

Durham E-Theses

Growth and degeneration of motor end-plates in mammalian skeletal muscle

Tuffery, A. R.

How to cite:

Tuffery, A. R. (1972) *Growth and degeneration of motor end-plates in mammalian skeletal muscle*, Durham theses, Durham University. Available at Durham E-Theses Online:
<http://etheses.dur.ac.uk/8689/>

Use policy

The full-text may be used and/or reproduced, and given to third parties in any format or medium, without prior permission or charge, for personal research or study, educational, or not-for-profit purposes provided that:

- a full bibliographic reference is made to the original source
- a [link](#) is made to the metadata record in Durham E-Theses
- the full-text is not changed in any way

The full-text must not be sold in any format or medium without the formal permission of the copyright holders.

Please consult the [full Durham E-Theses policy](#) for further details.

GROWTH AND DEGENERATION OF MOTOR END-PLATES IN

MAMMALIAN SKELETAL MUSCLE

A thesis presented in candidature for the degree of
Doctor of Philosophy

by

A. R. Tuffery, B.Sc. (Newcastle),
Department of Zoology, University of Durham

Durham, June 1972



ACKNOWLEDGMENTS

I am most grateful to Professor D. Barker for his stimulation, guidance and encouragement during this study. Muscles from ageing cats were obtained through the kind co-operation of Mr. Henderson and Mr. Turner, veterinary surgeons. Particular thanks are due to Mr. D. Hutchinson for his skilled photographic assistance; to Dr. A.H.M.F. Ragab for help with the preparation of material for electron microscopy; to Miss K. Flower and Miss S. Grocott for their help in the preparation and staining of paraffin sections; to Dr. J. Ollason for the use of original computer programmes; to the staff of the University of Durham Computer Unit for advice on computer programming and operation; to Professor W. Zeit of the Masquette School of Medicine, Milwaukee, for his generous gift of reprints of the work of E.J. Carey and his co-workers; to Mrs. R. Ashton for her patience and efficiency in the preparation of the typescript. The financial support of the Medical Research Council is gratefully acknowledged.

Finally, I would like to thank all the members of the Department of Zoology for contributing to a pleasant working atmosphere.

TABLE OF CONTENTS

	Page
Acknowledgements	(i)
Table of Contents	(ii)
Abstract	(vi)

INTRODUCTION

MATERIALS AND METHODS

1. Choice of species	4
2. Choice of muscles	5
3. Operative procedures	6
3.1 Tenotomy and exercise	7
3.2 Surgically-induced hypertrophy	8
4. Removal of muscles	8
5. Techniques for whole muscles	9
5.1 Modified de Castro silver impregnation	9
5.11 Procedure	10
5.12 Examination	11
5.13 Measurement	12
5.2 Combined cholinesterase and succinic dehydrogenase	13
5.3 Gold chloride	14
5.4 <u>In vivo</u> methylene blue	14
6. Techniques using sectioned material	15
6.1 Wax sections	15
6.2 Fresh-frozen sections	17
6.3 Histochemical staining methods	18
6.31 Succinic dehydrogenase (SDH)	18
6.32 Alkaline-stable actomyosin adenosine triphosphatase (ATPase)	18

	Page
6.33 Phosphorylase (P'ase)	19
6.4 Examination of histochemical preparations	20
6.5 Estimates of the number of muscle fibres	21
7. Electron microscopy	22
8. Photography	23
9. Statistical treatment	24

RESULTS

1. Terminology	26
1.1 The terminal innervation and the motor end-plate	26
1.2 Outgrowths of the terminal axon	26
1.3 End-plate types	28
1.4 Degeneration of motor end-plates	29
2. Morphology of motor end-plates of young adult cats ..	32
2.1 Peroneus digiti quinti	32
2.2 Soleus	36
2.3 Peroneus brevis	37
3. Measurements of motor end-plates and muscle fibres of young adult cats	40
3.1 Peroneus digiti quinti	41
3.11 Population values	41
3.12 End-plate types	42
3.2 Soleus	43
3.3 Peroneus brevis	44
4. Conclusions from the study of the terminal innervation of young adult cats	46
5. The terminal innervation of ageing cats	49
5.1 Morphology of end-plates of ageing cats	49
5.12 Ten year old peroneus digiti quinti	49

	Page
5.13 Soleus muscles of 6, 10 and 18 year old cats	52
5.2 Measurements of end-plates and muscle fibres of an ageing cat	54
5.21 Ten year old peroneus digiti quinti	54
5.22 Ten year old soleus	56
5.3 Numbers of muscle fibres	57
5.4 Conclusions	57
6. Effects of use and disuse in kittens	59
6.1 Tenotomy	59
6.2 Exercise	59
6.3 Conclusions	60
7. Surgically-induced hypertrophy	61
7.1 Morphological results	61
7.2 Measurements	62
7.3 Conclusions	66
8. Histochemical studies	67
8.1 Classification of muscle fibre types	68
8.2 Frequency of fibre types	71
8.3 Muscle fibre size and histochemical type	72
8.4 Combined cholinesterase and succinic dehydrogenase	73
8.41 Measurements	75
8.5 Conclusions	77

DISCUSSION

1. Validity of the observations on end-plate morphology	79
2. Earlier studies	82

	Page
2.1 Complex motor end-plates	82
2.2 Growth configurations	83
2.3 Degeneration	84
2.4 Conclusions	85
3. The nature of variations of end-plate morphology	86
3.1 The 'replacement' hypothesis	86
3.11 Rejuvenation	87
3.12 Substitution	88
3.13 Collateral sprouting	88
3.14 Conclusions	90
3.2 Muscle fibre types	91
3.3 The 'functional state' of the motor end-plate ..	93
4. Ageing	94
4.1 End-plate morphology	94
4.2 Muscle fibres	97
5. The elaboration hypothesis	100
5.1 A possible cause of elaboration	102
6. Concluding remarks	104
References	105

ABSTRACT

A detailed quantitative study of the morphological variations of extrafusal motor end-plates of normal cat hindlimb muscles as seen in teased silver impregnated preparations was undertaken.

The principal aim was to examine the hypothesis that end-plates undergo growth and degeneration in a process of cyclic degeneration and renewal ('replacement').

A new classification of the morphological complexity of end-plates was devised and the three muscles studied (peroneus brevis, peroneus digiti quinti and soleus) show characteristic variations in the proportions of complex endings, and in the size relationships of end-plates and muscle fibres. These variations are not related to differences in the proportions of muscle fibres of the three principal histochemical types.

The existence of growth and degeneration of end-plates was confirmed, but no new end-plates are formed. Hence the 'replacement' hypothesis is regarded as untenable. Instead, it is suggested that growth leads to the formation of end-plates of greater complexity ('elaboration'), and degeneration to the loss of muscle fibres commonly observed in ageing mammals. The examination of muscles from cats aged 6 - 18 years supports this concept because there is a striking increase in the proportions of complex end-plates and the number of muscle fibres is reduced.

By analogy with the formation of end-plates, it is suggested that 'elaboration' during ageing is a response to the increasing functional demands indicated by the increased

body weights and muscle fibre diameters. An attempt to test the effects of use and disuse in kittens was unsuccessful. However, surgically-induced hypertrophy of soleus in a young adult cat resulted in an increased proportion of larger, more complex end-plates with more numerous, longer axon terminals. This strongly suggests that 'elaboration' is indeed a response to functional demand.

The observations are discussed in relation to current views of the neuromuscular system.

INTRODUCTION

Since Doyere (1840) established the fact that motor nerves terminate on muscle fibres, the morphology of such neuromuscular junctions has been the subject of numerous studies and considerable variations according to species (Kuhne, 1887; Cole, 1955) and muscle (Cole, 1957) have been described. Mavrinskaya (1962) has summarized many of these comparative investigations and concludes that there is an evolutionary trend for motor nerve endings to become more compact and to involve greater specialization of the underlying part of the muscle fibre. The subject of this study is the motor end-plate. The term motor end-plate was coined by Krause (1863) to describe the compact type of neuromuscular junction in the retractor bulbi muscle of the cat, and is used throughout this account to refer to similar structures on the extrafusal muscle fibres of mammalian skeletal muscles. Such endings are all of the compact 'en plaque' form with a marked sole-plate or eminence of Doyere, in contrast to the more diffuse, varicose 'en grappe' endings with poorly-developed sole-plates found, for example, in the tonus bundle of the frog iliofibularis.

The principal aspect of the motor end-plate (or end-plate) studied is the form of the nervous elements, as distinct from the muscle component (or sub-neural apparatus). Also included is the appearance of the terminal nerve fibres from the point at which they leave the small intramuscular nerve trunks to their termination on the muscle fibres.



Variations in the form of motor end-plates in experimental and pathological conditions have been much investigated during the last three decades (e.g. Carey, 1941; Edds, 1950; Coers & Woolf, 1959), and diagnostic significance has been attributed to some of them (e.g. Allen, Johnson & Woolf, 1969). However, clinical studies have been handicapped by the difficulty of establishing the normal range of variation and of obtaining adequate numbers of end-plates for examination.

The development of the methods of investigation and the changes in the understanding of the motor end-plate from the 'classical' descriptive studies to the 'modern' functional or clinical studies have recently been fully reviewed by Zacks (1964). The modern view of the end-plate as a labile structure received dramatic confirmation from the observation that the end-plates of normal muscles of healthy young adult animals show evidence of growth and degeneration (Barker & Ip, 1965, 1966). These authors postulated that end-plates do not persist unchanged throughout the life of the animal, but degenerate and are replaced by new outgrowths from terminal axons. Barker & Ip were able to make their observations because they had developed a technique for demonstrating the terminal innervation with a clarity and completeness which had not been attained by earlier workers (Barker & Ip, 1963).

Thus, the increasing importance of end-plate morphology in clinical studies and the development of a greatly improved staining technique make a detailed quantitative examination of its variations in normal muscles both desirable

and possible. The present account is of such an investigation, the principal aim of which is to elucidate the nature of the 'replacement' of end-plates suggested by Barker & Ip, while gaining a more complete understanding of the normal range of variation in the form of motor end-plates.

MATERIALS AND METHODS

1. Choice of species

Since the object of this study was to investigate variations in the morphology of motor end-plates, animal muscles were used so that large numbers of end-plates could be obtained from a single muscle, thus obviating one of the chief difficulties of clinical studies. In order to isolate the variations due to growth and degeneration, it was necessary to eliminate the other possible sources of variation discussed above. Variations due to species differences were eliminated by restricting all the observations to muscles of the cat. This species had several other advantages for this study. Firstly, the principal observations of Barker & Ip (1965, 1966) on the growth and degeneration of end-plates were made on the cat. Secondly, the sequence of the morphological changes of end-plates after nerve section was established (Barker & Negus, unpublished; Barker, Stacey & Adal, 1970) and the preparations were available for examination. Moreover, a reliable technique for silver impregnation of nerve endings had been developed for cat muscles (Barker & Ip, 1963) and tedious modification of existing methods could be avoided. Since a great deal is already known about other aspects of the innervation and physiological properties of cat hindlimb muscles (e.g. Barker, 1962; Buller, 1965; Stacey, 1969; Barker et al., 1970), the results of the present study may contribute directly to this body of knowledge and thence to the understanding neuromuscular relationships as a whole.

Initially, all the animals selected for this study were healthy young adults, i.e. over 6 months old and weighing over 2.0kg. (cf. Nystrom, 1968c). Subsequently, it became necessary to examine the terminal innervation of much older animals, and cats aged 6, 10, 18 and 19 years were obtained. Lansing (1959) gives the normal life-span of the cat as 9-10 years, although individual animals have attained certainly 28 and possibly 33 years (Comfort, 1956). Both on this basis and their general appearance the 18 and 19 year old cats were considered to be senile. The ages of the principal animals used in this study are given in Table 1.

2. Choice of muscles

Only muscles of the lower part of the hindlimb were used, thereby minimizing differences in the distance from the spinal cord as a possible factor in variations in the terminal innervation. This was particularly important when using muscles from ageing cats, since it is suspected that the more distal muscles undergo changes earlier than the more proximal ones (Harriman, Taverner & Woolf, 1970).

The three peroneal muscles, which are flexors and extensors of the foot (Mivart, 1881; Barker et al., 1970), were selected as the principal muscles for study because of their accessibility and convenient small size for processing in a variety of ways. Of these three muscles the smallest, peroneus digiti quinti (PDQ) was examined most intensively.

Peroneus brevis (PB) and peroneus longus (PL) were examined in less detail in order to ensure that the observations on PDQ were generally valid for other fast muscles, and to determine whether relatively slight differences in contractile characteristics (as indicated by the histochemical studies of Barker et al., 1970) were reflected in the terminal innervation.

The soleus muscle, which has a much slower speed of contraction (Buller, 1965) and muscle fibres of a single histochemical type (Engel, Brooke & Nelson, 1965; Nystrom, 1968c), was also examined in detail. Thus it was hoped that the sources of variation of end-plate morphology would be minimized, while a sufficient diversity of muscles was examined to permit the evaluation of the results with respect to the function of the muscle fibres. The sources of the principal muscles used in the present study, together with their subsequent treatment, are summarized in Table 1.

3. Operative procedures

Because the principal object of the present investigation was to determine the extent of growth and degeneration of normal motor end-plates, very few operated muscles were used. Two series of experiments were carried out to test the effects of use and disuse on experimental muscles. All the operations were performed with full aseptic precautions under sodium pentobarbitone B.P. (40mg/kg i.p.) anaesthesia.

TABLE 1. Principal animals and muscles used

All the cats were 6 - 18 months old and weighed over 2kg ('young adults'), unless otherwise specified. The procedure to which each muscle was subjected is indicated (details in text).

Cat No.	Age	Muscles	Procedure
K1	10 weeks	PB, PDQ, PL, soleus	Holmes silver method
C230		PDQ	Silver impregnation
C251		PDQ	Nerve section and silver impregnation
C254		PB, PDQ (2), soleus	Silver impregnation
C268		PDQ	Electron microscopy
C293	6 years	soleus	Silver impregnation
C294	10 years	PDQ, soleus (2)	Silver impregnation
C295		PDQ	Combined cholinesterase and succinic dehydrogenase
C296	18 years	PDQ soleus	Paraffin sections Silver impregnation
C297	19 years	PDQ	Paraffin sections
C303		PB, PDQ, PL, soleus	Histochemistry (frozen sections)
C306		soleus	Hypertrophy and silver impregnation

SEP 1972
1

3.1 Tenotomy and exercise

The experimental animals were four kittens (litter-mates) aged 8 weeks, the age at which the end-plates were likely to have just reached the adult form (Nystrom, 1968b). The right Achilles tendon of one animal was sectioned and the tenotomy maintained for 10 days. This was the time taken for noticeable adhesions to form between the cut end of the tendon and the surrounding tissues and determined the duration of the experimental period. During this period a second animal was exercised daily on a motor-driven activity wheel. The intensity and duration of the exercise was adjusted daily so that it always appeared to be maximal. Care was taken to ensure that the animal was not deprived of food or milk during the exercise period.

The two remaining animals were used as controls, one at the beginning and one at the end of the experimental period. The body weights of these three animals were recorded daily. The weights of the gastrocnemius and soleus muscles were weighed immediately after excision from the animals. The muscles of all the animals were fixed in neutralized formalin for 10 days, embedded in paraffin wax, sectioned longitudinally and stained according to the Holmes silver method (infra, 6.1) to demonstrate the terminal innervation. Silver impregnations of the whole muscles were not attempted because preliminary trials had shown that kitten muscles did not stain satisfactorily with this technique.

3.2 Surgically-induced hypertrophy

A second attempt was made to determine the effects of increased use on the morphology of the motor end-plates. The tendon of the right soleus muscle of a young adult cat (C306) was sectioned, leaving that of the gastrocnemius intact. About 0.5cm of the soleus tendon was removed in order to discourage regeneration. In this way it was expected that the gastrocnemius would be subjected to greater loading due to the loss of function of its major synergist (cf. Rowe & Goldspink, 1968). The animal was examined every few days and when there was any sign of the formation of adhesions between the sectioned tendons and the surrounding tissues, the limb was flexed to break them down (Buller & Lewis, 1965). In this way the tenotomy was maintained for 84 days. The gastrocnemius and soleus muscles were excised and impregnated with silver according to the modified de Castro method (infra, 5.1).

4. Removal of muscles

All the muscles used were removed from the animals under standard conditions as far as possible, whatever the subsequent treatment. The animal was given a fatal intra-peritoneal dose of sodium pentobarbitone B.P. (approx. 60mg/kg) and the muscles excised between the onset of deep surgical anaesthesia and death. In the case of the 6, 18, and 19 year old animals the sodium pentobarbitone was administered by intracardiac injection and the muscles taken 1 - 24hr post mortem. In some instances the muscles were weighed immediately after removal from the animal.

The treatments to which the muscles were then subjected were of two basic types. Firstly, techniques using whole muscles, for the examination of their terminal innervation. Secondly, techniques using sections to study the histochemistry and morphology of the muscle fibres. In addition to these, one PDQ muscle was prepared for electron microscopy.

5. Techniques for whole muscles

Clearly, for the examination of such a diffuse entity as the terminal innervation, preparations of whole muscles are to be preferred to sections, since they will give a more complete picture and avoid errors due to reconstruction from serial sections.

5.1 Modified de Castro silver impregnation

The selection of the principal staining method to be used is critical in any histological study. In the present investigation it is of paramount importance since the manifestations of the growth of the terminal axon (Barker & Ip, 1965, 1966) consist of extremely fine non-myelinated outgrowths and could easily pass unobserved with a coarse staining method.

The modified de Castro method for the silver impregnation of terminal intramuscular nerve fibres and their endings was preferred to other techniques for whole muscles (vide infra 5.3 and 5.4) because of its greater reliability and clarity of impregnation of nerve fibres and their endings. This technique has the additional advantage that it enables the nodes of Ranvier to be distinguished (cf. Stacey, 1969),

permitting the exact determination of the point of origin of the outgrowths. There is also a useful amount of general staining of other structures such as capillaries and nuclei and in most cases the area of the sole-plate can be distinguished.

5.11 Procedure. The modifications of Barker et al. (1970) of the original method described by Barker & Ip (1963) were adopted. The suggestion of Ip (1967) that the fixative be changed daily was tried in some cases, but caused no appreciable difference in staining properties and was not generally used. All the muscles from a given animal were passed simultaneously through the same solutions. The volume of each solution was about 200ml for 20g muscle. All the solutions were freshly prepared immediately before use and the conditions standardized as far as possible. A brief description of the procedure follows.

The labelled muscles were placed in fixative (chloral hydrate, 1g; 95% alcohol, 45ml; distilled water, 50ml; conc. nitric acid, 1ml) for 6 days. A longitudinal incision was made in larger muscles such as soleus to facilitate the penetration of reagents. The muscles were washed for 24hr in running filtered tap water, and placed in ammoniacal alcohol (4 drops 0.880 ammonium hydroxide in 100ml 95% alcohol). After blotting, the tissue was incubated in 1.5% aqueous silver nitrate at 37°C in the dark for 5 days, and reduced in 2% hydroquinone in 25% formic acid. Finally, the muscles were thoroughly washed in distilled water and placed in glycerol for at least a week before teasing.

Slides of material treated in this way were prepared by separating a small piece of the muscle by blunt dissection and squashing under a slide in glycerol. This 'squash' preparation was examined with a Zeiss Stereomicroscope II using both incident and transmitted light and selected portions teased out with fine surgical needles, mounted in glycerol and the coverslip sealed with 'Glyceel' (George T. Gurr Ltd.) or, better, pitch.

5.12 Examination. All preparations were examined using a Zeiss GFL microscope with x12.5 eyepieces. The x10, x25 and x100 objectives were 'Planapo' quality and the x40 'Neofluor'. The range of magnifications was further increased by an accessory lens system ('Optovar').

Only well-stained sprays of end-plates were selected for detailed study, and all the end-plates in a selected spray were included in the sample, in order to minimize subjective bias. Each end-plate was examined at a magnification of at least x300 and the presence of signs of growth and degeneration noted. The Functional Terminal Innervation Ratio (F.T.I.R.) was determined for each sample of end-plates from a given muscle. In some muscles the number of axon terminals present in each end-plate was also recorded. Each sample of end-plates was examined several times during the course of the study, often at intervals of over a year. In this way it was ensured that all the criteria for selection were being maintained and that all the descriptive terms used (Results 1) were being applied in a consistent manner to all samples.

Because the location of each terminal spray (and often of individual end-plates) was known by reference to the microscope stage co-ordinates or an 'England Finder' (Graticules Ltd.), it was possible to compare the results of successive examinations in detail and to resolve any discrepancies that occurred.

5.13 Measurements. All measurements were made using a x40 objective and a Zeiss micrometer eyepiece (xl6), calibrated using a micrometer slide. No attempt was made to correct for the shrinkage which undoubtedly occurs in such preparations (Stacey, 1969; Crowe & Ragab, 1970). Since all measurements were made by the same observer on material prepared in the same way, any comparisons of measurements within the study are valid. Only those end-plates which lay 'en face' within the depth of focus, and which were on muscle fibres with distinct margins, were selected for measurement.

The end-plate diameter was the mean of two orthogonal measurements, one of which was in the long axis of the muscle fibre. The muscle fibre diameter was the mean of three to five measurements made close to the end-plate. In addition, to these 'primary' parameters, two derived values were used in each case. The first of these was the ratio of the two measurements of the end-plate, that made in the long axis of the muscle fibre being the numerator. This axial ratio was preferred to the ratio of the longer axis to the shorter (L1/L2 ratio of Woolf, 1970), because, besides giving an indication of the general shape of the ending, it is 'orientated', i.e., if an end-plate is elongated in the long axis of the muscle

fibre, the axial ratio will be greater than unity. However, if an end-plate of the same dimensions is elongated in the short axis of the muscle fibre, then the axial ratio will be less than unity. The L1/L2 ratios of end-plates of the same dimensions will be the same and convey no information about the direction of elongation. In practice there was little difference between these ratios because the end-plates were almost always elongated in the long axis of the muscle fibre. However, in pathological material this refinement might prove of value (e.g. Allen et al., 1969).

The second derived parameter was the percentage ratio of the end-plate and muscle fibre diameters, which may be used to compare the relationship of the two primary parameters from different muscles without reference to absolute values.

5.2 Combined cholinesterase and succinic dehydrogenase

In order to compare end-plate structure directly with the histochemical type of muscle fibre, squash preparations of muscles were double-stained for acetylcholinesterase (AChE) which delineates the sub-neural apparatus (SNA) of the end-plate, and succinic dehydrogenase (SDH), an oxidative mitochondrial enzyme. The method was that of Barker et al. (1970), based on the methods of Karnovsky & Roots (1964) for AChE, and Pearse (1961) for SDH. The only modification required was the reduction of the incubation time for AChE to 5min, optimal for extrafusal motor end-plates. This procedure clearly demonstrated

the sub-neural apparatuses of the end-plates and the three types of muscle fibre commonly observed (Stein & Padykula, 1962). A similar double-staining method has been described using frozen sections of mouse muscles (Ogata, 1965), but is unsuitable for the larger end-plates and muscle fibres of the cat. The present method obviates difficulties and errors due to sectioning.

The form and intensity of staining of the SNA was related to the intensity of the succinic dehydrogenase reaction of the muscle fibres. Only SNA seen 'en face' were measured, otherwise every SNA and muscle fibre encountered was measured until the required number had been reached. By this means any bias towards the selection of larger muscle fibres (Jcubert, 1956) was avoided.

5.3 Gold chloride

In order to check the validity of the modified de Castro silver impregnation method, some cat peroneal muscles were stained by the gold chloride method of Gairns (1930). The contrast of the end-plates and muscle fibres was poor and the axon terminals lacked the delicacy seen in silver impregnated material so that fine axonic outgrowths could be seen only with difficulty. Some endings with enlarged, extremely coarse axon terminals resembling those of degenerating end-plates were observed. The method was regarded as unsuitable for general use.

5.3 In vivo methylene blue

Methylene blue has been widely used for staining

motor end-plates, although it is only suitable for very small pieces of tissue. Accordingly, the hindlimbs of anaesthetized rats and kittens were perfused with a solution of 0.5% methylene blue in a modified Krebs' solution at pH 5.6 (Crowe & Ragab, 1970; Ragab, 1970). In both species it was found that only the smallest muscles of the foot were adequately stained. The intensity of staining was very variable, but in the most well-stained areas some axonic outgrowths could be seen. The nodes of Ranvier were seldom identifiable and the points of termination of the nerve endings could not be determined with certainty because of the lack of background staining. Some end-plates with swollen axon terminals indicative of degeneration (Woolf, 1966) were observed. Like the gold chloride method it was regarded as unsuitable for general use.

6. Techniques using sectioned material

As stated above, teased preparations were preferred for the study of the terminal innervation, sections being used solely for the examination of the histological and histochemical properties of the muscle fibres.

6.1 Wax sections

Muscles embedded in paraffin wax were used when large amounts of material were required for examination in serial section. Peroneal, gastrocnemius and soleus muscles of kittens, 18 and 19 year old cats, were prepared in this way. The muscles

were removed from the anaesthetized animal as described above (Section 3) and fixed in Susa's fixative for 3hr. Dehydration was accomplished using cellosolve (2-ethoxyethanol) in the following way :-

- (a) iodized 95% cellosolve 3hr, replacing the solution every 30min, with agitation;
- (b) absolute cellosolve, 1hr with three changes, with agitation.

The muscles were cleared in toluene for 20min and embedded in plasticized paraffin wax (Paramat, George T. Gurr Ltd.).

Both longitudinal and transverse sections were cut, 10 μ m thick of the muscles of the senile cats, and stained with either haemotoxylin and eosin (H & E) or Weigert's haemotoxylin and Curtis' Ponceau S substitute for van Gieson's stain (H & VG; Humason, 1962). These sections were examined for atrophic fibres and other signs of abnormality such as centrally placed nuclei.

The muscles from kittens were sectioned first transversely to determine the muscle fibre diameter. The blocks were then re-orientated for longitudinal sectioning, the section thickness being set at approximately the fibre diameter in order to obtain as many end-plates seen 'en face' as possible (Nystrom, 1968a). These sections were stained by the Holmes silver method followed by gold toning, to demonstrate the terminal innervation (Carelton & Drury, 1957). Some of the slides were coated with celloidin to prevent detachment of the sections during processing. Muscle fibre diameters were measured in transverse sections stained with either H & E or H & VG. Care was taken to examine and measure

only intact end-plates, and the number of axon terminals present and the form of the ending (see Results 1.3) were noted.

6.2 Fresh-frozen sections

Fresh-frozen sections were used when small amounts of tissue were being processed and for the demonstration of enzyme activities of muscle fibres.

After excision, muscles were cut into suitable pieces and frozen by immersion for at least 1min in a slurry of liquid nitrogen and iso-pentane at approximately -160°C (Maxwell, Ward & Nairn, 1966). The muscles were frozen directly on to metal chucks using 5% gum tragacanth (Engel & Cunningham, 1963), or, more often on to pieces of stiff card, and later attached to the chucks using gum tragacanth and CO_2 gas. If not immediately required for sectioning the muscles were stored in sealed containers at -30°C .

Before sectioning, the muscles were placed in the cryostat (Slee Ltd.) to equilibrate at -20°C . Serial $10\mu\text{m}$ transverse sections were cut from the thickest part of the muscle and the exact orientation checked using sections stained with H & E or H & VG. If necessary the tissue block was re-orientated before further sections were cut.

Sections were picked up in pairs on clean microscope slides and allowed to thaw at room temperature ($22-26^{\circ}\text{C}$). In this way, successive pairs of sections could be processed for each of the histochemical methods and one for the histological stain.

6.3 Histochemical staining methods

Fresh-frozen sections were incubated to demonstrate the activities of succinic dehydrogenase, alkaline-stable actomyosin adenosine triphosphatase and phosphorylase, so that the histochemical profiles of the fibres could be determined. Sections from the three peroneal muscles and soleus of a young adult cat (C303) were passed simultaneously through the same solutions in each staining method, in order to reduce any variations in treatment. The details of the histochemical techniques are briefly described in the following sections.

6.31 Succinic dehydrogenase (SDH). Nitro blue tetrazolium was used as a hydrogen ion acceptor according to the method of Nachlas, Tsou, de Souza, Cheng & Seligman (1957) as modified by Pearse (1961). Incubation was carried out at 37°C and pH 7.6. The optimum incubation time was found to be 25min. The incubation medium was freshly prepared from stock solutions on the day of staining.

The sites of activity of SDH were defined by purple diformazan granules scattered in the sarcoplasm of the muscle fibres. Succinic dehydrogenase is a mitochondrial enzyme and Ragab (1970) has pointed out the similarity of the distribution of diformazan granules and mitochondria in tortoise muscles.

6.32 Alkaline-stable actinomyosin adenosine triphosphatase (ATPase). The ATPase activity of the muscle fibres was demonstrated by the method of Guth &

Samaha (1970). The alkaline pre-incubation solution was adjusted to the empirically determined optimum of pH 9.5. The incubation time was 45min at room temperature. All solutions were freshly made up from the stock solutions immediately before use.

Muscle fibres of low ATPase activity were colourless or occasionally 'smoky' in appearance. As the activity increased a more intense brown colour developed. Blood vessels and connective tissue also showed a positive reaction. Guth & Yellin (1971) have demonstrated that after fixation and alkaline pre-incubation, the ATPase activity is localized in the myofibrils.

6.33 Phosphorylase (P'ase). The method of Eranko & Palkama (1961) was used with the sole modification that the slides were mounted in D.P.X. and not iodine-glycerol. This modification was adopted because it was found in preliminary experiments that fading of the preparations was negligible when they were stored in darkness at 5°C. The resulting preparations also gave better contrast between different intensities of staining when photographed. The optimum incubation time was 20min.

A trial series of slides was incubated at various times with and without the substrate, glucose-1-phosphate, to determine the sequence and nature of the colour intensities produced by the reaction. The 'negative' reaction produced in the absence of substrate was characterized by a golden-yellow colour of the muscle fibres. Fibres of intermediate and high activity stained blue-black and brown respectively.

When sections of soleus were processed in the presence of the other highly active muscles, it was observed that the muscle fibres had a light blue 'wash' effect. It was assumed that this false positive result was produced by the diffusion of glucose from the active sections, and when sections of soleus were processed alone in fresh solutions, they showed the golden-yellow 'negative' reaction. A similar process may explain the occasional 'smoky' appearance of some fibres in PB and PL.

The activity of P'ase is much more widely distributed throughout the muscle as a whole than SDH or ATPase and consequently enables specific groups of muscle fibres to be readily identified.

6.4 Examination of histochemical preparations

Following the observations of earlier workers (e.g. Nystrom, 1968c; Edgerton & Simpson, 1969), it was decided to base the classification of the histochemical types of muscle fibres on the activity of all three enzymes, and not on any single enzyme. Accordingly, sections stained for the activity of each enzyme were set up side by side on three microscopes and each muscle fibre in a selected fascicle identified on each preparation and its enzyme profile recorded. At the same time the size was noted on a three-point semi-quantitative scale. This process was repeated until the required number of fibres had been typed. The precise criteria used for determining the activity of each enzyme are summarized in Table 9. The criteria for fibre typing are discussed elsewhere (Results 8.1).

In order to determine more exactly whether muscle fibre diameter was related to histochemical type, two orthogonal diameters were measured at a final magnification of x640 using a micrometer eyepiece. The longest axis of the muscle fibre was always measured. This method was preferred to the more exact procedures described by Edstrom & Torlegard (1969) because of its ease of execution (cf. Adams, Coers & Walton, 1968). Preparations stained for ATPase were preferred for measurements because the individual fibres were well defined. Each fibre was classified as before by simultaneous examination of SDH and P'ase preparations.

6.5 Estimates of the number of muscle fibres

Estimates were made of the number of muscle fibres in sections of one PDQ muscle of cats aged 1, 18 and 19 years. In each case a photographic montage of a complete transverse section through the widest part of the muscle was prepared and small groups of muscle fibres marked off on it. Each of the groups was identified on the section and the number of extrafusal fibres present recorded on the montage. In this way it was possible to ensure that all the fibres present in the section were counted and that none were counted more than once. No attempt was made to test the accuracy of the counting technique by performing replicates, since insufficient material was available to determine other than gross variations. The muscle fibres of PDQ are inserted in a pennate fashion so that it is probable that not all of them are present in any one transverse section. However, this is unlikely to be a major source of variation between counts in different muscles.

7. Electron microscopy

The terminal innervation is not amenable to study with the electron microscope, because the relatively low occurrence of growth and degeneration in particular make it highly improbable that such configurations will be identified in thin sections. Moreover, it is unlikely that the different types of end-plate (Results, 1.3) will be distinguishable at the ultrastructural level. However, the PDQ muscle of one young adult cat (C298) was prepared for electron microscopy using 3% glutaraldehyde in 0.2M cacodylate as a fixative (2hr) with 1hr osmium post fixation and Epon embedding. Thick (0.5 - 1 μ m) transverse sections were stained with toluidine blue in 1% borax and examined with the light microscope. When end-plates were identified (Plate XVb) the block was trimmed and thin (50 - 60 μ m) sections cut at 2 - 3 μ m intervals. The sections were stained with lead citrate and uranyl acetate and examined and photographed with an AEI EM 801 electron microscope.

In this way, 25 end-plates were examined at two to five levels. In every case all the axon terminals had the normal appearance described by Adal & Barker (1967) in the cat and by other workers in the rat (e.g. Padykula & Gauthier, 1970) and no sign of growth or degeneration was found (Plate XVa, c). Since the ultrastructure of the motor end-plate does not form a major part of this study, these findings will not be discussed further.

8. Photography

All preparations were photographed using the Zeiss Ultraphot II microscope with the same types of eyepieces and objectives as used for the original examination. Ilford FP4 film was used with a general purpose developer. All photographs were produced to a standard enlargement. The final magnification of the prints was determined by making exposures of a micrometer slide at each of the magnifications used and processing them in the usual way. Filters were used to improve the contrast of the final prints whenever possible. No further attempts were made to standardize the photographic procedures used for the histochemical preparations, since all comparisons of enzyme activity were made on the original preparations and not on photographs. All preparations were selected for photography on the basis of their clarity. In teased preparations, end-plates often extended beyond the plane of focus of a single photograph. In such cases several exposures were made at different levels of focus and a montage prepared. If any doubts arose concerning the completeness of the montages, the original preparation was re-examined. This technique is now so commonly used that it has not been thought necessary to distinguish montages from single exposures in the legends to the individual figures presented.

Where the endings were not suitable for photography but were considered to be especially important, camera lucida drawings were made. A few endings were traced from photographs

in order to improve their clarity in presentation. In all these cases the original preparation was carefully checked to ensure the maximum degree of accuracy.

9. Statistical treatment

The statistical analysis of the measurements of end-plate and muscle fibre diameters and the parameters derived from them (above, Section 4.13) was made using the facilities of the Northumbrian Universities Multiple Access Computer (NUMAC). All the programmes used were tested for accuracy using specially prepared sets of data.

The correlation coefficient (r) and the regression lines were calculated by the method of least squares (Moroney, 1956), for all the possible combinations of the four parameters in each set of data. The level of statistical significance of the correlation coefficient was determined from statistical tables (Fisher & Yates, 1957). Significant differences between mean values were determined by the Student's test.

It was necessary to determine whether the distributions of the end-plate and muscle fibre diameters corresponded to the normal curve, because it has been shown that they can be markedly altered in various experimental and pathological conditions (Allen et al., 1969; Goldspink, 1964; Rowe & Goldspink, 1968). Further, tests of the normality of the distribution of muscle fibre diameters might be expected to indicate whether diameter could be used as a criteria of muscle fibre type.

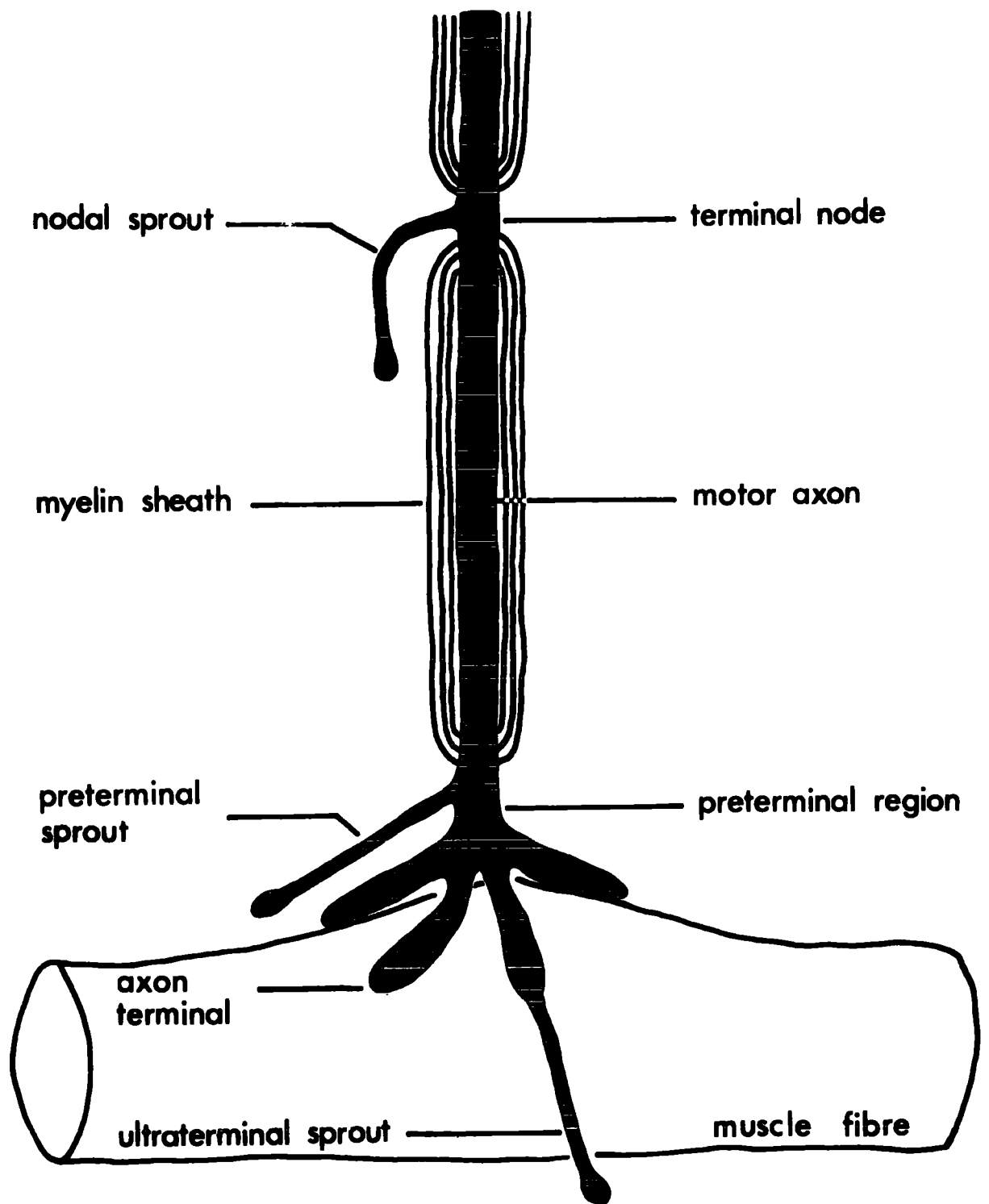
The method of Harding (1949) and Cassie (1954) using the cumulative percentage distribution plotted on arithmetic probability paper proved both tedious and unreliable, depending in critical cases on subjective assessment. Reske-Nielson, Coers & Harmsen (1970) have used the calculation of g_1 and g_2 (Snedecor, 1962) to test populations of end-plate and muscle fibre diameters for skew (assymetrical distribution) and kurtosis ('an excess or deficit of items concentrated near the centre of the range'), respectively, and this method was adopted.

The parameters g_1 and g_2 were calculated using a modified version of the FORTRAN programme given by Sokal & Rohlf, 1969). The level of statistical significance of g_1 and g_2 was determined by a t test (Snedecor, 1962) using an original PL/1 programme. This method of testing the extent of the deviation from the normal distribution has the advantage that it uses ungrouped data, and does not rely on subjective assessment. Besides indicating that a distribution is not normal, it identifies the nature of the deviation as being due to skew or kurtosis or both.

FIGURE 1. Diagram to illustrate the terms used to describe the morphology of the terminal axon and the motor end-plate

The motor axon passes towards the muscle fibre and loses its myelin sheath, forming a short preterminal region. The axon terminates on a slight swelling of the muscle fibre (the Doyere's eminence) and there sub-divides to form the axon terminals.

Non-myelinated outgrowths (sprouts) may arise from the various regions of the terminal axon. Thus, a nodal sprout typically originates from the terminal node, whereas preterminal sprouts and ultraterminal sprouts arise from the preterminal region and the axon terminals respectively. The part of the muscle fibre immediately underlying the axon terminals is termed the sole-plate.



RESULTS

1. Terminology

Any morphological study, however well illustrated, must rely heavily upon verbal description, and clearly the value of such a description is dependent upon the precision of the terms employed. Since end-plates were first recognized, the nomenclature applied to the terminal innervation has proliferated. Many of the terms have been poorly defined, not defined at all, or used in different ways. Therefore, before describing the results of the present study, the terms used will be defined. In general, the usage of Barker & Ip (1966) has been adopted (see Fig. 1).

1.1 The terminal innervation and the motor end-plate

Typically, the terminal axons leave the intramuscular nerve trunks in small groups. Such a group of terminal axons and their motor end-plates is referred to as a terminal spray (e.g. Plate Ia). Just before reaching the muscle fibre, the myelin sheath investing each axon ends, leaving a short, naked preterminal region, which finally subdivides forming the fine axon terminals of the ending (Fig. 1). The area of muscle fibre underlying the end-plate is modified by the accumulation of cell organelles to form a sole-plate or eminence of Doyere.

1.2 Outgrowths of the terminal axon

The terminal axon and the end-plate may give rise

to non-myelinated outgrowths, which, following other workers (e.g. Coers & Woolf, 1959; Barker & Ip, 1966), are considered to be evidence of growth. Non-myelinated outgrowths terminating in a simple taper or, more frequently, in a small swelling or 'growth cone' are described as sprouts. These are referred to as nodal, preterminal, or ultraterminal, according to whether they take origin from a node, the preterminal region or from the axon terminals. In the material used in the present study it was not possible reliably to distinguish a preterminal sprout from a slightly elongated axon terminal ending in a small bulb (see Plate Id). Ultraterminal sprouts were only rarely encountered and hence the term 'sprout' refers to a nodal sprout unless specified otherwise. Frequently, a non-myelinated outgrowth from a node ends in a group of axon terminals associated with an end-plate. Such an outgrowth is termed a contribution (Fig. 2b). Sprouts and contributions are collectively referred to as growth configurations, and the end-plate formed by the terminal axon from which they arise is called the parent ending. Examples of growth configurations are illustrated in Plates VI - VII.

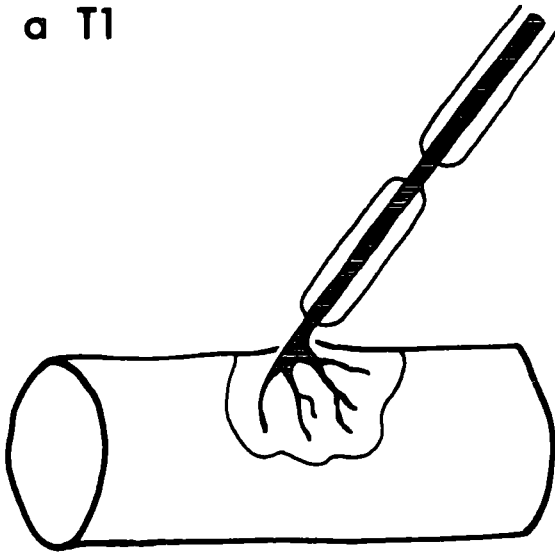
The adjective collateral will be used to describe an outgrowth from a terminal axon that ends on a muscle fibre other than the one bearing the parent ending. Thus, Fig. 2e illustrates a bifurcating terminal axon forming two collateral end-plates on separate muscle fibres. Two end-plates derived from the same terminal axon are said to be a collateral pair of end-plates. Collateral end-plates are illustrated in

FIGURE 2. Diagram to illustrate the terms used to describe morphological features of motor end-plates

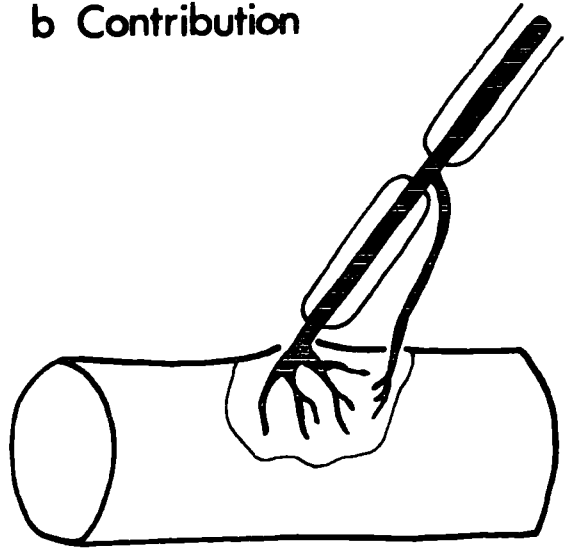
The extent of the sole-plate of each ending is indicated by the continuous line.

- a) Simple T1 end-plate formed by an unbranched myelinated terminal axon.
- b) T1 end-plate receiving a contribution, i.e. a non-myelinated outgrowth from a node which forms axon terminals on the sole-plate of the parent ending.
- c) T2 end-plate formed by two myelinated branches of the terminal axon; both end on the same sole-plate.
- d) A terminal axon divides and the axon terminals of the two branches lie on separate sole-plates, forming a duplex ending.
- e) Collateral branching. A terminal axon divides, giving two collateral end-plates on separate muscle fibres.

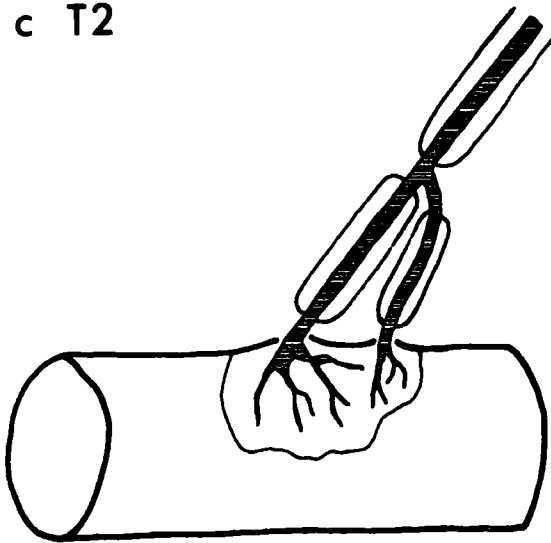
a T1



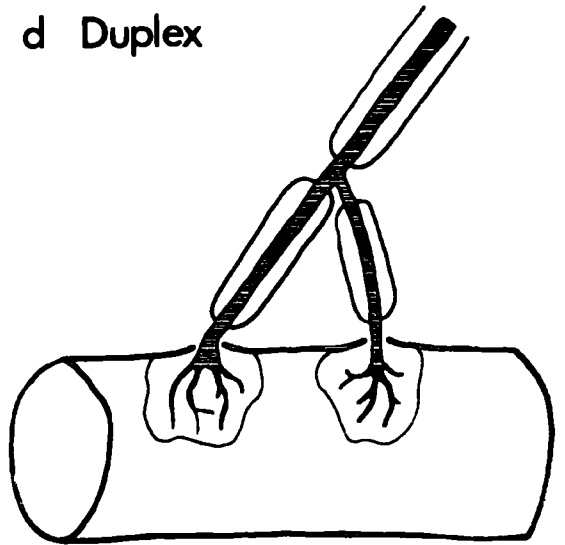
b Contribution



c T2



d Duplex



e Collateral

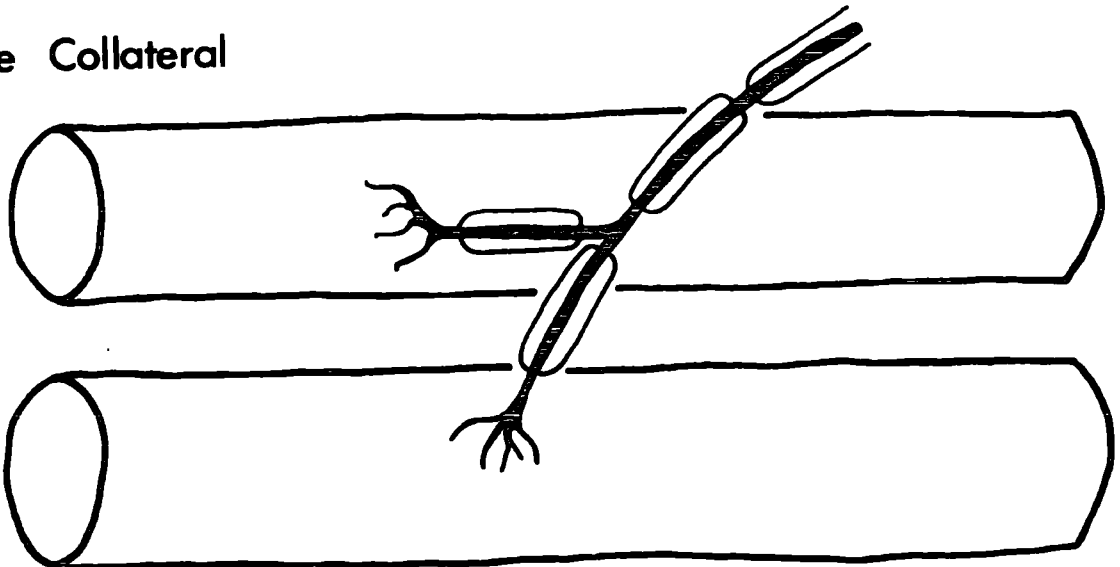


Plate III. The incidence of such forms is expressed by the ratio of the number of muscle fibres to the number of terminal axons supplying them. This is known as the Functional Terminal Innervation Ratio (Edds, 1950) and, if each terminal axon innervated only one muscle fibre, it would be unity. In experimental and pathological conditions this ratio is greatly increased. Thus, in partially denervated muscles, the surviving terminal axons re-innervate the denervated muscle fibres by forming collateral outgrowths ('collateral regeneration', Edds, 1950; see Fig. 18).

1.3 End-plate types

End-plates vary in their mode of formation from the terminal axon. The simplest is formed by the unbranched terminal axon and is described as a T1 end-plate (Fig. 2a). End-plates formed by two or three myelinated branches of the terminal axon are called T2 (Fig. 2c) and T3 endings, respectively. More complex endings involving more than three myelinated branches were rarely encountered in muscles from young adult animals. 'More complex' in the context of this study means that an end-plate is formed by a greater number of myelinated branches of the terminal axon or that it bears a growth configuration. Thus a T2 ending and a T1 ending receiving a contribution are both 'more complex' than a simple T1 ending. It should also be noted that the use of the terms 'form' or 'type' of end-plate are based solely on morphological considerations and no functional significance is implied.

Each complex end-plate (T2 - T5 forms) is considered to be a single entity and not several separate endings on the same muscle fibre because of the proximity of the axon terminals derived from each of the branches of the terminal axon. In those cases where the sole-plate nuclei are stained, it can clearly be seen that there is but a single sole-plate (e.g. Plates IVh, IXh). On very rare occasions a terminal axon branches to form two groups of axon terminals that are so widely separated that they can not be considered to lie on the same sole-plate. Such an ending is described as duplex (Fig. 2d). However, only four convincing examples of duplex endings were encountered in the course of the present study. One of these is illustrated in Fig. 8d. The distinction between T2 and duplex endings is important in a consideration of the role of the growth configurations and will be discussed further (Discussion 3.12). Some workers have regarded all end-plates formed by one terminal axon and lying on the same muscle fibre as separate functional entities (e.g. Harriman *et al.*, 1970). Many others have not distinguished between 'double end-plates' (corresponding in most cases to the T2 ending, e.g. Cole, 1955, 1957; Barker & Ip, 1966) and duplex endings, even when they have used the terms (e.g. Carey, 1941, p.401, Figs. 25 - 31).

1.4 Degeneration of motor end-plates

In the course of this study end-plates having a configuration resembling those seen after nerve section were observed in unoperated muscles. In accord with the practice of Barker & Ip (1966) and various clinical workers (see Coers

& Woolf, 1959) these end-plates were considered to be undergoing degeneration. A brief account of the changes in the morphology of end-plates after nerve section has been given by Barker et al. (1970), but because these changes are of such importance to this study, a fuller account, based upon material prepared by Barker & Negus (unpublished), will be presented (Fig. 3).

The normal end-plates of peroneal muscles have distinct, fine axon terminals, typically ending in fine tapers. After section of the common peroneal nerve at the point of its division into the deep and superficial branches, the axon terminals become less delicate. Thus, 24hr after nerve section the axon terminals are typically swollen or varicose, and slightly retracted, sometimes terminating in rings or knobs. After 48hr the majority of end-plates are further retracted, often leaving only a single bulbous terminal swelling. At 60 - 72hr post-operatively almost all the endings are granular and also show centripetal degeneration of the terminal axon. Examples of end-plates at various times after nerve section are illustrated in Plate IVc - e and similar configurations from normal muscles in Plate IVa - b, f - h, and Plate V. These changes are not simultaneous in all endings; for example, the end-plate shown in Plate VIIc is normal in appearance 24hr after nerve section.

For convenience, end-plates with varicose, slightly retracted axon terminals are described as being in the early phase of degeneration and those with marked retraction as in the middle phase of degeneration. End-plates with complete granulation of the axon terminals and replacement of the nerve

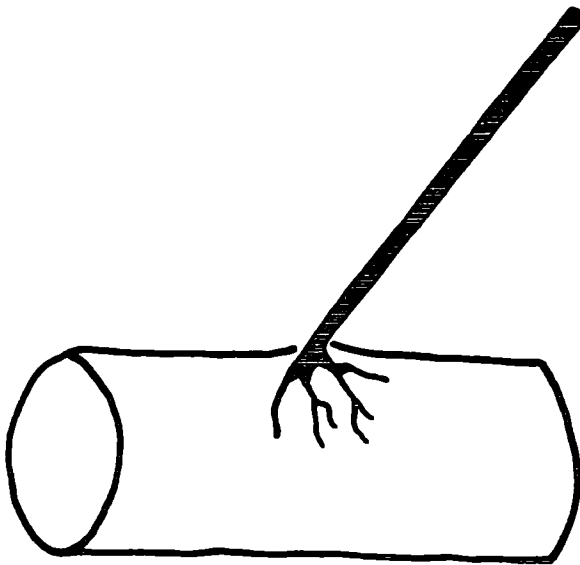
by axonal debris were never seen in normal muscles. However, occasionally end-plates with retracted, somewhat granular axon terminals were observed, and these are described as in the late phase of degeneration.

The results of an examination of the morphology of end-plates of a PDQ muscle of a young adult cat (C251) 24hr after nerve section are summarized in Table 2. A comparison of these results with those of normal PDQ muscles (Table 4) shows that they are similar in all respects, except for the greatly increased proportion of end-plates in the early phase of degeneration.

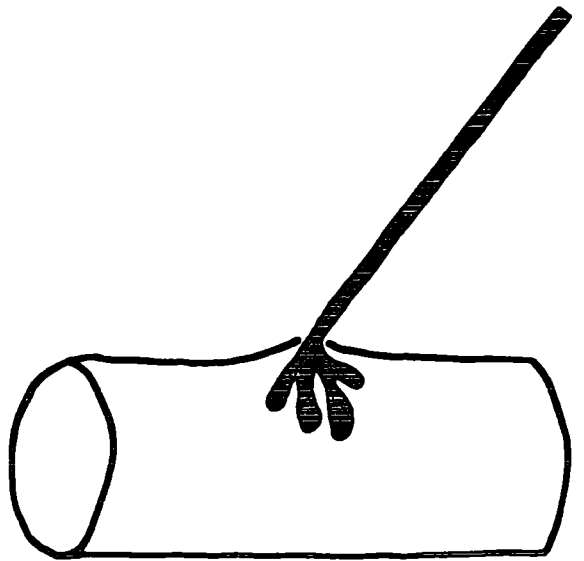
FIGURE 3. Diagrams of the typical changes in end-plate morphology after nerve section (based on teased silver preparations)

- a) The normal motor end-plate has delicate axon terminals, typically ending in fine tapers.
- b) At about 24hr after nerve section the axon terminals are slightly retracted and swollen.
- c) After 48hr the axon terminals are further retracted and swollen, often forming only a single knob.
- d) The final stage in the disappearance of the end-plate is reached about 60hr after nerve section. The axon terminals and part of the terminal axon are replaced by axonal debris with a granular appearance.

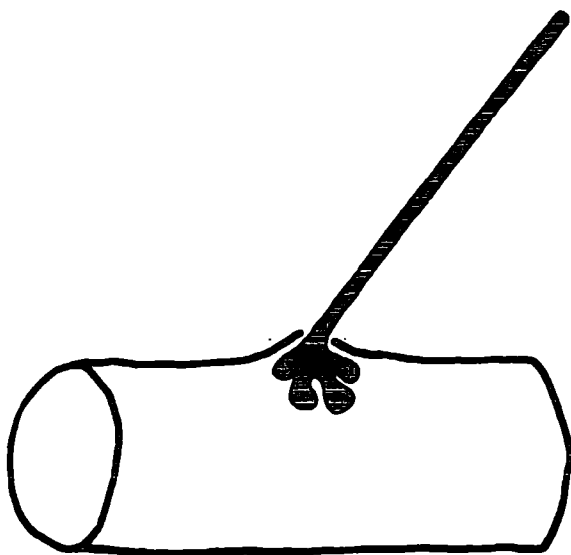
a Normal



b 24 hr



c 48 hr



d 60 hr

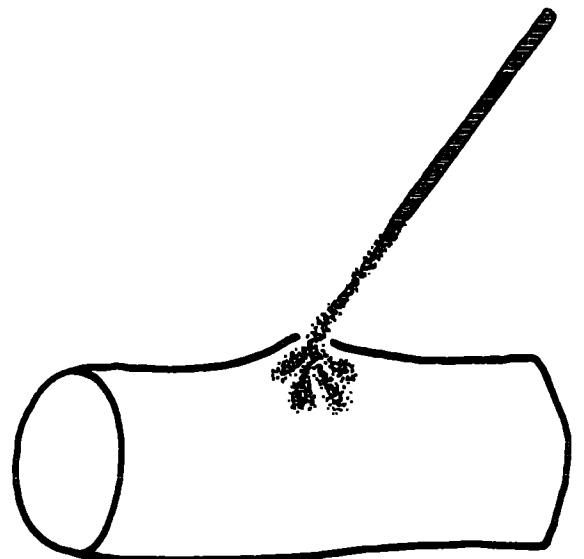


TABLE 2. Morphology of motor end-plates in the PDQ muscle of a young adult

cat (C25A), 24hr after nerve section

The common peroneal nerve was sectioned 1cm above the level of entry into the muscle 24hr prior to fixation. The total number of end-plates examined was 1,304.

The results for each principal type of end-plate (T1, T2 and T3) are shown separately, as well as those of the whole sample. The 'total' values for each type represent the total number of endings of that type (with or without evidence of growth or degeneration) as a percentage of the total number of endings examined. The remaining values in each column are the percentage of each type modified as indicated.

(Note : 'Late' degeneration should read 'Total' degeneration).

	T ₁	T ₂	T ₃	Total
Total	67.2	31.2	1.6	100.0
Nodal sprouts	4.8	3.0	4.8	4.2
Contributions	10.7	3.8	-	8.4
Total growth	15.5	6.8	4.8	12.6
Early degener- ation	62.0	57.2	100.0	44.6
Middle degener- ation	3.5	3.1	-	3.4
Late degener- ation	65.5	60.3	100.0	63.9

2. Morphology of motor end-plates of young adult cats

The main object of this investigation was to examine in greater detail and to quantify the observation of Barker & Ip (1965, 1966) that motor end-plates show growth and degeneration in muscles of normal young adult cats. The principal muscles selected for study are PDQ and soleus, but other muscles were also examined in less detail. The morphology of the end-plates of PDQ will be described fully, but in order to reduce repetition only the chief differences will be described for other muscles. The results of the morphological examination of end-plates are summarized in Table 4.

2.1 Peroneus digiti quinti

In the course of this study, no muscle fibre receiving more than one end-plate derived from different terminal axons was observed. Over 2,000 motor end-plates were examined from three PDQ muscles of two normal young adult cats, and, since the end-plates and muscle fibres of different muscles were similar in respect of all criteria studied, the results were pooled and treated as a single entity.

The end-plates of PDQ show a diversity of form and have well developed, fine axon terminals, usually terminating in tapers, although knobs and rings also occur. There is a diversity of form of ending (Plates I - II), the most complex being of the T4 type (Fig. 8b). No duplex endings were found in the three muscles included in the sample, but a single example was present in another PDQ muscle (Fig. 8d).

The frequencies of end-plate types, growth and degeneration in PDQ are summarized in Table 4. The proportion of T1 end-plates was about four times as high as that of the more complex forms. Only 1.5% of all end-plates were of the T3 type. The more complex T2 and T3 types of end-plate were usually formed by branching at the terminal node (Plate IIb, e), but sometimes the terminal axon branched at a more proximal node (Plate IIa, d, f). The proportion of the number of axon terminals derived from each of the myelinated branches of the terminal axon was very variable. In some cases the branches formed approximately equal numbers of axon terminals, in others one branch provided nearly all the terminals.

Growth configurations most commonly arose from the terminal node. Contributions could form more or less axon terminals than the parent ending. The range of variation in origin and termination of sprouts and contributions is illustrated in Plates VI - VII. Growth configurations were associated with 15.6% of terminal axons (Table 4). In every case the growth configuration passed to the sole-plate of the parent end-plate and generally ended close to its axon terminals. Occasionally, however, the axon terminals of the contribution lay among those of the parent end-plate (Plates VIc, VIId). That growth configurations do indeed end on the same sole-plate as the parent ending was most evident when the nuclei of the sole-plate were visible (e.g. Plate VIc - d).

Contributions occurred with twice the frequency of sprouts and were absent from T3 end-plates. The latter finding

may be attributed to the small size of the sample of T3 end-plates. Occasionally a contribution with a more or less localized thickening of its axon was encountered. Such configurations were interpreted as indicating that myelination was taking place (Plate VI f). End-plates of the T1 form received proportionately more growth configurations than T2 endings. This difference was largely due to the relatively high proportion of T1 end-plates receiving contributions (11.4% compared with 5.6% of T2 end-plates), since the proportion of sprouts associated with these two principal types of end-plate were approximately equal. Less than 1% of end-plates received more than one growth configuration and in such cases there were two sprouts or two contributions.

The ratio of the number of muscle fibres receiving end-plates to the number of terminal axons supplying them (F.T.I.R.) was 1.02 (Table 4). This indicates that the incidence of collateral branching is extremely low compared with values obtained in various muscles of rat and man (Edds, 1950; Coers, 1955; Coers & Woolf, 1959). In each case of collateral branching the terminal axon divided to form end-plates on two separate muscle fibres (i.e. no case of a terminal axon innervating more than two muscle fibres was seen). All the collateral end-plates were well-formed with myelinated axons and could not be considered as 'young end-plates' (Barker & Ip, 1966). Nor were any cases of the formation of a second end-plate on a muscle fibre by collateral branching observed. Such cases of 'hyperneurotization' have been reported in collateral regeneration (Hoffman, 1951, 1953).

The proportions of T1 and T2 collateral end-plates and the incidence of growth configurations were not markedly different from those of the sample as a whole. Although no T3 collateral end-plates were found in any of the three muscles in the sample, a single instance of terminal axon branching to form two T3 end-plates was found in a PDQ muscle of another young adult cat.

There was no apparent relationship between the form of the members of a pair of collateral end-plates. Thus, in only one instance were both members of a pair of the T2 form. Nor was there any relationship between the presence of a growth configuration on members of a collateral pair. No degenerating collateral end-plates were observed.

In all, 14.6% of the end-plates in PDQ muscles of normal young adult cats were considered to be undergoing degeneration. Of these, approximately 70% were in the early phase (Table 4). Approximately equal proportions of T1 and T2 end-plates were affected (15.4% and 17.8% respectively. All the 35 T3 end-plates in the sample appeared completely normal.

Some 30% of degenerating end-plates received growth configurations. In every case where the growth configuration was a contribution its axon terminals had the same retracted or swollen appearance as those of the degenerating parent end-plate. In other words, where a contribution occurred on a degenerating end-plate, it too appeared to be affected by the degeneration process (Plates Vd, g, IXd).

TABLE 3. Morphology of motor end-plates in the PB muscle of a young adult cat (C254)

(For description, see legend to Table 2).

	T ₁	T ₂	T ₃	Total
Total	90.0	9.7	0.3	100.0
Nodal sprouts	2.5	0.9	-	2.4
Contributions	6.0	1.7	-	5.6
Total growth	8.5	2.6	-	7.9
Early degeneration	0.3	-	-	0.3
Middle degeneration	4.3	-	-	3.9
Late degeneration	0.1	-	-	0.1
Total degeneration	4.7	-	-	4.2

2.2 Soleus

In terms of their general appearance the end-plates of soleus are less delicate than those of PDQ. The axon terminals are fewer, shorter and coarser than in PDQ and commonly end in knobs rather than in the fine tapers or rings typical of the latter muscle. As noted by Nystrom (1968b), the most distal portion of the terminal axon is frequently curled round on itself so that the axon terminals lie to one side of it. Examples of typical soleus end-plates are shown in Plate VIIIa - g and the results of the morphological examination are summarized in Table 4.

There were far fewer complex endings than in PDQ, T2 end-plates constituting only 1% of the sample (21.5% in PDQ) and T3 endings were completely absent. The incidence of growth configurations was also much lower than in PDQ (4.1% and 15.6%, respectively. Again, no sprouts passing to muscle fibres other than the one bearing the parent ending were observed. Only one end-plate received more than one growth configuration.

The F.T.I.R. was 1.02, the same as in PDQ. All the collateral end-plates were of the T1 form, as might be expected from the predominance of these endings in the sample as a whole. One collateral end-plate showed evidence of growth. In this muscle two degenerating collateral end-plates were observed. They were derived from the same terminal axon and both were in the middle phase of degeneration.

The assessment of degeneration in soleus end-plates is more difficult than in the peroneal muscles because of their coarser appearance, but generally the swollen, retracted axon terminals, characteristic of middle degeneration, are unmistakable on careful scrutiny (cf. Plates VIIIa - g and IXe).

The incidence of degenerating end-plates was 12.2%, a little less than in PDQ; however, unlike PDQ, the majority were in the middle phase of degeneration. Growth configurations were associated with 10.3% of all degenerating end-plates.

2.3 Peroneus brevis

This muscle was included in the study because it resembles PDQ in form and function more closely than soleus does. Consequently, an examination of its terminal innervation may be expected to give a measure of the more subtle variations in the morphology of motor end-plates with respect to muscle function. In order to simplify the presentation of the results and to facilitate comparisons between the two principal muscles studied, the results of the morphological examination of PB are tabulated separately (Table 3).

In addition to the morphological study of the terminal innervation whole fascicles of muscle fibres were teased and examined throughout their length to determine whether any of the muscle fibres received more than one end-plate. It was not possible to determine precisely the number of fibres examined, but it was estimated that the sample size was at least 400. In no case did a fibre receive more than one end-plate.

This finding confirms the observations made on the end-plate region of other muscle fibres.

In terms of their general form the end-plates of PB are simpler than those of PDQ, having fewer, more widely separated axon terminals. The muscle appears to contain more connective tissue and to have a higher degree of vascularization than PDQ. In terms of the proportions of complex end-plates, PB is intermediate between PDQ and soleus, T2 and T3 endings together constituting 10% of the sample (PDQ, 23%; soleus, 1%). The incidence of growth configurations is 8% (Table 3), the same as in soleus. However, PB resemble PDQ in that sprouts occur with twice the frequency of contributions.

All the growth configurations ended on the sole-plate of the parent ending as they did in soleus and PDQ. End-plates of the T1 form received proportionately more growth configurations than the other forms. Three end-plates received more than one growth configuration. One of these received a sprout and a contribution; the others each received two contributions.

Cases of collateral branching were more frequent than in PDQ and soleus as shown by the F.T.I.R. of 1.03. However, Coers (1955) has pointed out that the muscle-to-muscle variation in the F.T.I.R. is such that an increase of this magnitude is not likely to be significant. It was noticeable that a much greater proportion of the collateral branching of the terminal axons occurred in the small intramuscular nerve trunks, rather than more distally in the terminal sprays as in PDQ and soleus. In a single case a terminal axon formed three end-plates, in the remainder

only two end-plates were formed by the bifurcated terminal axon. The proportion of T2 collateral end-plates was considerably higher than in the sample as a whole (25% and 9.7%, respectively). In only one case were both members of a collateral pair of the T2 form. No T3 collateral end-plates were encountered. Growth configurations were associated with only three collateral end-plates but never with both members of a collateral pair.

The total amount of degeneration in PB was 4.2% (Table 3), only a third of that in PDQ and soleus. All the degenerating end-plates were of the T1 form and as in soleus the majority had the swollen, retracted appearance characteristic of the middle phase of degeneration. Only four (8%) degenerating end-plates received a growth configuration.

FIGURE 4. Graph of 172 end-plate and muscle fibre diameters from teased silver preparations of PDQ muscles of a normal young adult cat (C254). Each form of the end-plate is denoted by a separate symbol:-

- Simple T_1 end-plate
- ▽ T_1 end-plate receiving a nodal sprout
- T_1 end-plate receiving a contribution
- ▼ T_1 end-plate receiving a myelinating contribution
- T_2 end-plate without evidence of growth
- T_2 end-plate receiving a sprout or contribution
- ▲ T_3 end-plate
- △ Other more complex end-plates

Overall, the end-plate and muscle fibre diameters are significantly correlated ($r = 0.37$; $P < 0.001$; $y = 0.55x + 38.1$), and the regression line is shown by the solid line. The correlation for T_1 end-plates receiving contributions is shown as a dotted line ($n = 28$; $r = 0.50$; $p < 0.01$; $y = 0.54x + 28.4$). There is considerable dispersion of the points and the ranges of values for each individual end-plate type overlap to a great extent.

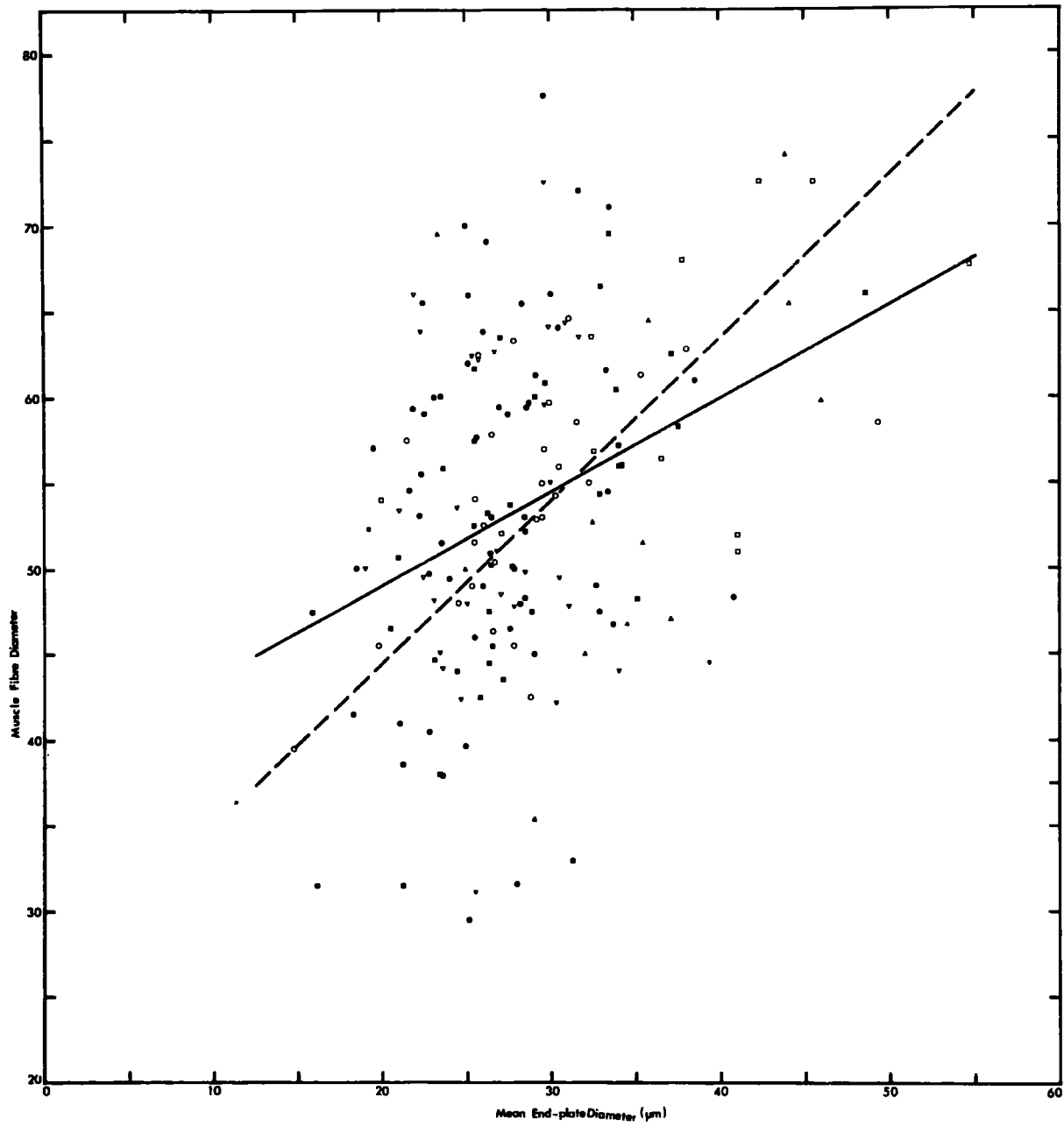
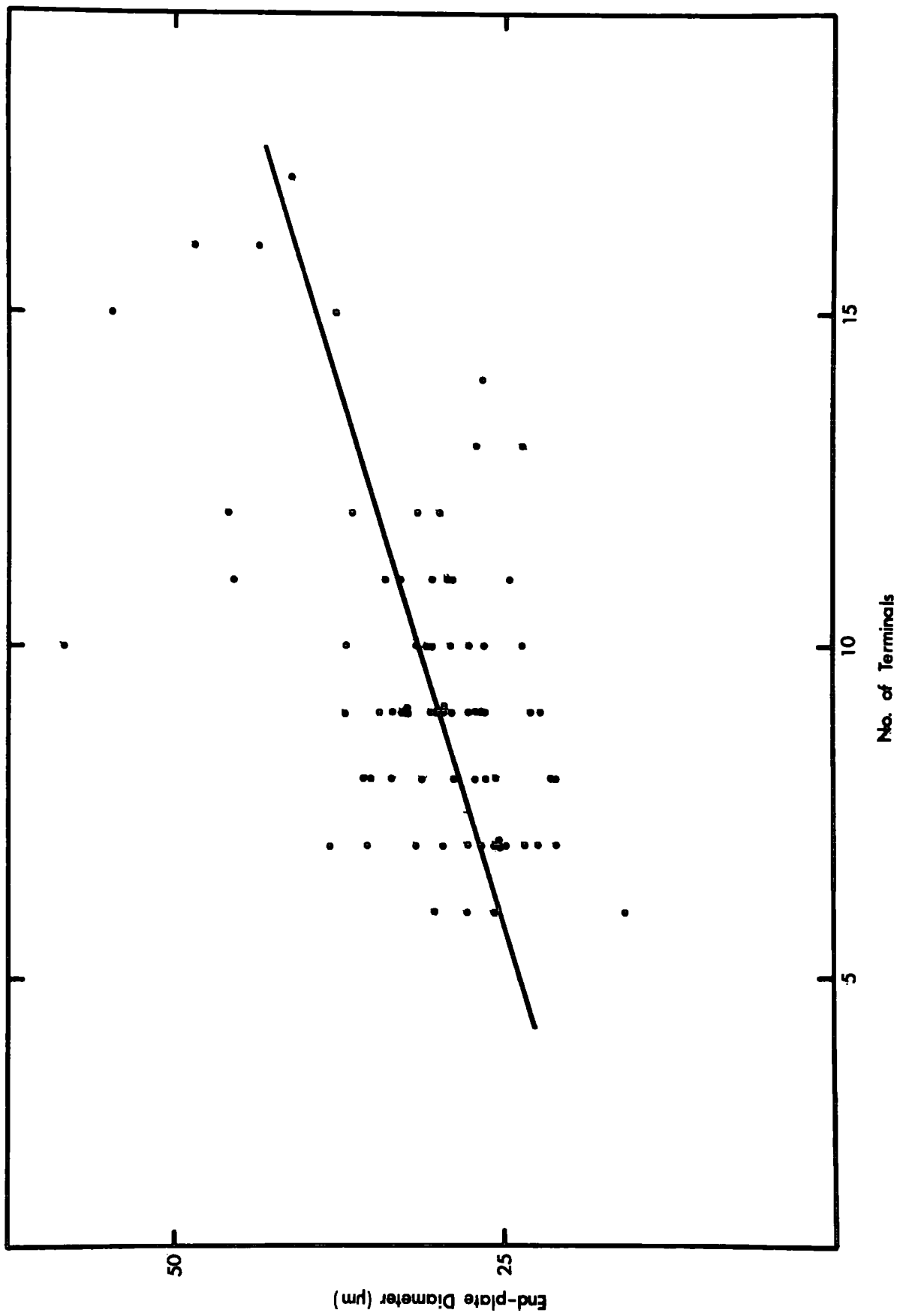


FIGURE 5. Graph of the number of axon terminals and end-plate diameters
of the PDQ muscle of a normal young adult cat (C254)

A total of 72 end-plates were measured in teased silver preparations. The correlation is highly significant, although the dispersion is great ($r = 0.28$, $P < 0.001$; $y = 1.56x + 16.0$).



3. Measurements of motor end-plates and muscle fibres of young adult cats

A study of the measurements of end-plates and their muscle fibres can be expected to shed light upon their relationships. The results of these measurements and of the numbers of axon terminals per end-plate are summarized in Tables 5 - 6.

Table 5 shows the data from the PDQ muscles of both the young adult and the 10 year old cats and Table 6 the values for the soleus muscles of young adult and ageing cats. This arrangement has been adopted to demonstrate as clearly as possible the changes occurring with ageing (Results, 5.2).

In each case the data are grouped according to the end-plate types, arranged in increasing order of complexity (i.e. simple T1 end-plates first, then T1 end-plates receiving nodal sprouts, and so on up to T3 endings). Even where the sample sizes are too small to be adequate for statistical analysis, the results are shown for comparison. The mean values for each muscle are also included but must be treated with some caution because the samples were not taken entirely at random; the rarer complex end-plates were sometimes specifically sought in order to increase sample sizes. Statistically significant variations from the normal distribution are indicated.

It should be noted that the end-plate and muscle fibre diameters consist of paired data but that the number

of axon terminals was estimated in end-plates other than those measured and not in every case where an end-plate was measured. Consequently the sample sizes available for assessing the degree of correlation between this last parameter and the others are somewhat lower than might be expected and are given where relevant.

3.1 Peroneus digiti quinti

In view of the diversity of morphological types of end-plate in this muscle (Table 4), it is of particular interest to determine the nature of the variations between them. Therefore, the results will be presented firstly as a whole and secondly with regard to the end-plate types.

3.11 Population values. The mean values with their standard errors are given in Table 5. The end-plate and muscle fibre diameters were positively correlated to a significant extent ($r = 0.37$, $P < 0.001$), however there is considerable dispersion of their values about the calculated regression lines (Fig. 4). The distribution of the muscle fibre diameters is given as a histogram in Fig. 10. The end-plate diameter is also positively correlated with the number of axon terminals (Fig. 5), although the degree of significance is lower ($n = 72$, $r = 0.28$, $P < 0.02$), presumably due to the smaller sample size. Thus, it may be said that larger muscle fibres tend to have larger end-plates with greater numbers of axon terminals.

The mean value for the percentage ratio of end-plate and muscle fibre diameters is 54.4 (S.E. 0.97). The mean

ratio of the two measured orthogonal axes of the end-plates (the axial ratio) is 1.36 (S.E. 0.065), indicating that the end-plates were consistently somewhat elongated in the long axis of the muscle fibre. For this reason the axial ratio was not significantly different from the L1/L2 ratio (Methods, 5.13).

3.12 End-plate types. The muscle fibre diameter percentage ratio and the axial ratio did not vary significantly between end-plate types. A few of the values for the number of axon terminals and end-plate diameter were significantly different from those of other forms of end-plate. These two parameters appear to form a graded series showing a clear tendency to increase with increasing morphological complexity of the end-plate (Table 5). Thus, although the distribution of the whole population of end-plate diameters shows both skew and kurtosis ($g_1 = 1.05$, $P < 0.001$; $g_2 = 1.93$, $P < 0.001$) this could not be attributed to the presence of specific sub-populations of different forms of end-plate. The range of the diameters of each form of end-plate overlapped that of the adjacent forms in the series. For example the range for simple T1 end-plates is (16.3 - 40.7 μ m), virtually the same as that of the population as a whole, viz. 14.8 - 49.3 μ m (see also Fig. 4).

When the data are considered according to end-plate type, the correlation between the number of axon terminals and end-plate diameter is not significant in any of the sub-groups. Similarly, the correlation between end-plate and muscle fibre diameter remains statistically significant in only two sub-

groups; T1 end-plates receiving contributions ($r = 0.50$, $P < 0.01$) and T2 end-plates ($r = 0.61$, $P < 0.001$). This loss of correlation in the remaining sub-groups must be attributed to the small sample sizes.

3.2 Soleus

The vast majority of end-plates are of the simple T1 form and the results will therefore be treated only as a whole. All three parameters shown in Table 6 are significantly different ($P < 0.001$) from the corresponding values in PDQ.

The finding that the end-plates of soleus are smaller than those of the 'fast' peroneal muscles confirms the work of Gerebtzoff, Philippot & Dallemagne (1954) and disagrees with the observations of Nystrom (1968b) who found that the end-plates of soleus are larger than those of gastrocnemius.

The increase in the muscle fibre diameter is the most striking feature and is to be expected in a postural muscle which is used much more than the 'phasic' peroneal muscles (Vrbova, 1962). A consequence of the increased muscle fibre diameter with a reduced end-plate diameter is the fact that the percentage ratio of 32.1 (S.E. 1.26) is also significantly lower ($P < 0.001$) than in PDQ. This contrasts with the finding of Nystrom (1968b) who found that the percentage ratio in both soleus and gastrocnemius muscles of the cat was about 50.

The mean axial ratio of 1.41 (S.E. 0.106) is not significantly different from the values in PDQ. This contrasts with Nystrom's (1968b) finding that the end-plates of soleus are more elongated than those of gastrocnemius. The distributions

of the numbers of axon terminals and the end-plate diameters both show skew and kurtosis ($g_1 = 1.29$, $P < 0.001$, $g_2 = 3.19$, $P < 0.001$; $g_1 = 0.97$, $P < 0.01$, $g_2 = 1.58$, $P < 0.05$, respectively). Clearly, since the end-plates in this sample are virtually all of the same morphological type, the deviations from normality cannot be accounted for by any consistent variations in the characteristics of any one type. This observation confirms the findings in PDQ. The distribution of the muscle fibre diameters is normal and is shown as a histogram in Fig. 10.

Unlike the situation in PDQ, the end-plate and muscle fibre diameters are not correlated. Because the estimates of the numbers of axon terminals per end-plate were not made at the same time as the measurements were carried out, it was not possible to determine whether there was any correlation between this parameter and the others.

3.3 Peroneus brevis

As before, the results are not tabulated with those of PDQ and soleus. Because of the paucity of complex end-plates (Table 3) it was not possible to obtain sufficient numbers to warrant treating the different end-plate types separately and the data are therefore treated only as a whole.

The mean values for the number of axon terminals, end-plate diameter and muscle fibre diameter were 5.6 (S.E. 0.25), 23.1 μ m (S.E. 0.61), and 53.1 μ m (S.E. 1.35), respectively. The number of end-plates in the sample was 73 in the case of the axon terminals and 100 each for the diameter measurements. All three parameters were distributed normally.

The mean muscle fibre diameter of PB is not significantly different from that of PDQ and, like the latter, it is significantly smaller than in soleus ($P < 0.001$). The mean end-plate diameter is the same as in soleus and significantly lower than in PDQ ($P < 0.001$). The mean number of axon terminals of PB end-plates is also intermediate between the values for soleus and PDQ, but the differences are not statistically significant. The end-plates of PB are more rounded than in either PDQ or soleus as shown by the mean axial ratio of 1.15 (S.E. 0.046), significantly lower ($P < 0.001$) than PDQ and soleus values. These relationships are reflected in the percentage ratio of end-plate and muscle fibre diameter (44.5, S.E. 0.97) which is intermediate between those of PDQ (54.4, S.E. 0.97) and soleus (32.1, S.E. 1.26) and significantly different from both ($P < 0.001$). Thus, the observation that the end-plates of PB are somewhat simpler in form than those of PDQ, but not as simple as those of soleus, receives quantitative confirmation from these data.

The end-plate and muscle fibre diameters are significantly correlated ($r = 0.67$, $P < 0.001$; Fig. 6). Similarly, the number of axon terminals is correlated with the end-plate diameter ($r = 0.71$, $P < 0.001$; Fig. 7). Clearly, the degree of correlation is much greater than in PDQ. This is reflected by the fact that the number of axon terminals is also correlated with the muscle fibre diameter in a statistically highly significant manner, although the correlation coefficient is reduced ($r = 0.53$, $P < 0.001$), relative to that for the correlation between the number of axon terminals and the end-plate diameter.

FIGURE 6. Graph of end-plate and muscle fibre diameters
of the PB muscle of a normal young adult cat
(C254)

The sample size is 100. The correlation
is highly significant ($r = 0.67$, $P < 0.001$;
 $y = 1.39x - 20.8$).

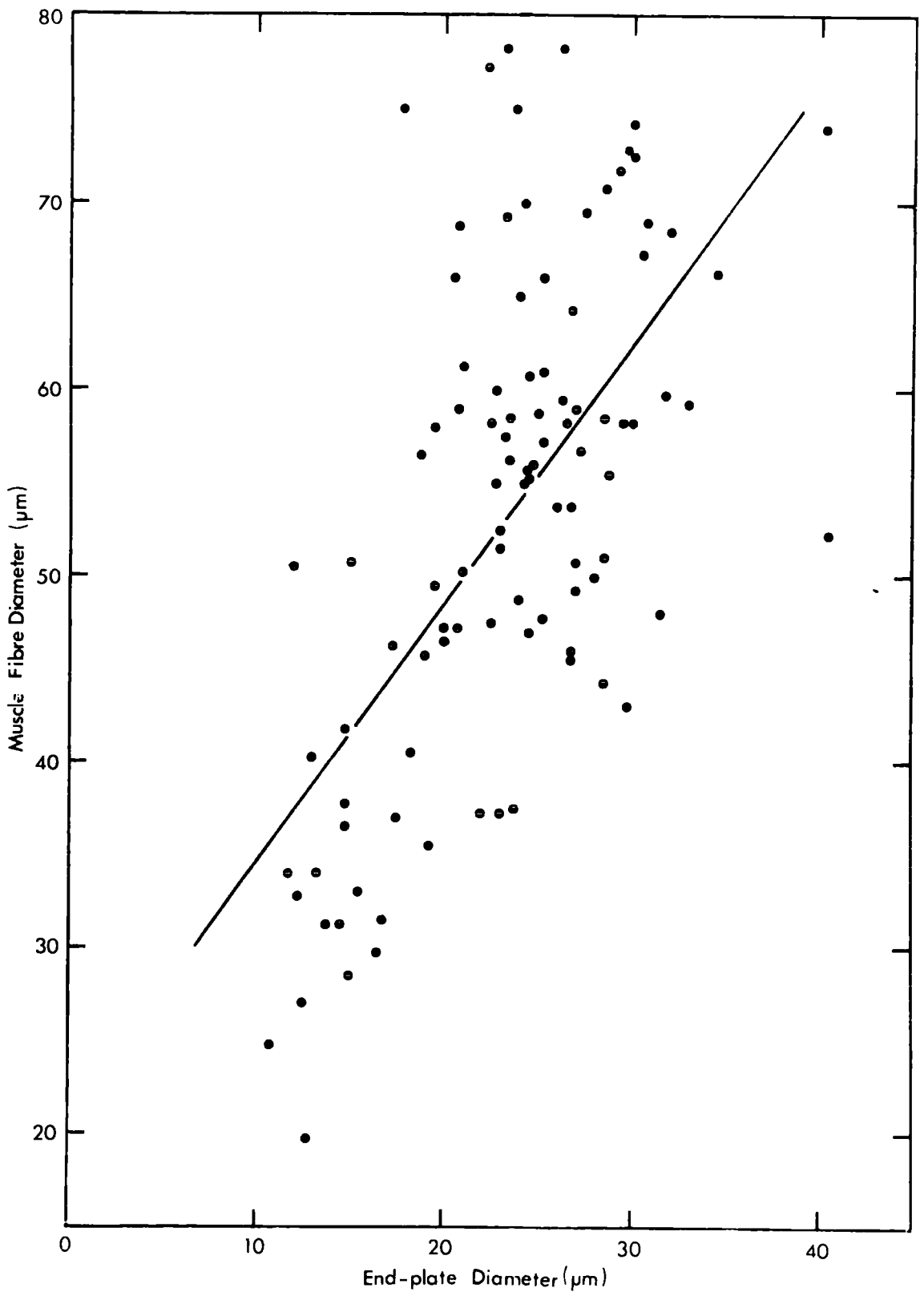


FIGURE 7. Graph of the number of axon terminals and end-plate diameters of the PB muscle of a normal young adult cat (C254)

The number of end-plates in the sample is 73. The correlation is highly significant ($r = 0.71$, $P < 0.001$; $y = 0.27x - 0.05$). Some points have been slightly displaced along the ordinate to improve clarity.

4. Conclusions from the study of the terminal innervation of young adult cats

The results demonstrate that PDQ, PB and soleus muscles have characteristically different frequencies of end-plate types, PDQ having the highest incidence of the more complex forms and soleus the lowest. There are also variations in the incidence of growth and degeneration. The end-plates of PB resemble those of soleus in size and are intermediate between PDQ and soleus in respect of frequency of complex forms and the number of axon terminals. The mean muscle fibre diameter, however, is the same as that in PDQ and much lower than in soleus. These variations may be seen as a reflection of the different functions of the muscles. Thus, the peroneal muscles are used relatively seldom, while soleus is subject to almost constant excitation (Vrbova, 1962), which might explain the increased muscle fibre diameter in soleus. The difference between PDQ and PB may be attributable to more subtle variations in usage. For example, PB probably has a slower contraction speed than PDQ (see Table 10 and Barker et al., 1970), and this may explain the lower incidence of complex endings in PB.

The results of the measurements of end-plates and muscle fibres and the estimates of the number of axon terminals show that there is a tendency for more complex end-plates to be larger and to have more axon terminals. However, these parameters appear to bear no relationship to the muscle fibre diameter.

The results of the morphological study of the terminal innervation confirm Barker & Ip's (1966) finding that the end-plates of normal muscles of young adult mammals undergo growth and degeneration. However, they do not support their hypothesis that the two processes are causally related in a cyclic process of growth and decay ('replacement', see Fig. 17) for two reasons.

Firstly, all the growth configurations were in contact with the sole-plate of the parent ending, and there was no evidence of the formation of new end-plates by substitution (Fig. 17d - f) or collateral sprouting. Secondly, if 'replacement' were taking place it would be expected that most, if not all, degenerating end-plates would receive a growth configuration. In fact only 30% of all degenerating end-plates in PDQ do so, and the proportions in soleus and PB are even lower (10.3% and 8%, respectively).

These points will be discussed more fully elsewhere. For the present it is sufficient to say that the hypothesis of end-plate 'replacement' must be regarded as untenable, and that the explanation for the variations of end-plate morphology must be sought elsewhere. It appears that growth and degeneration are unrelated, and it is suggested that growth might be involved in the formation of the more complex forms of the end-plate from simpler forms. According to this hypothesis of end-plate elaboration, sprouts and contributions are seen as successive stages in the formation of more complex end-plates (Fig. 19). If growth and degeneration are not related, then it seems probable that degenerating end-plates

are lost and that there will be a concomitant reduction in the number of muscle fibres.

In order to test this hypothesis of end-plate elaboration the terminal innervation of cats aged 6 - 18 years was examined in the same way as in the young adult animals. If the hypothesis is correct it would be expected that the proportion of the more complex end-plates would be greater in the muscles of these older animals, and that the number of muscle fibres would be lower in the muscles of the older cats.

TABLE 4. Morphology of motor end-plates of PDQ and soleus muscle
of cats of various ages

The individual animals are identified and their ages and body weights given. The values for the frequencies of the principal types of end-plate and of growth and degeneration are percentages of the total number of end-plates examined in each case.

	Young adult PDQ (C254, C230). 2.80kg.	10 year old PDQ (C294). 4.40kg.	Young adult soleus (C254). 2.80kg.	6 year old soleus 5.53kg.	10 year old soleus (C294). 4.40kg.	18 year old soleus (C296). 2.25kg.
	(\bar{n} = 2339)	(\bar{n} = 757)	(\bar{n} = 614)	(\bar{n} = 119)	(\bar{n} = 500)	(\bar{n} = 500)
T_1	77.0	45.1	99.0	59.7	87.6	73.8
T_2	21.5	47.4	1.0	36.1	12.0	24.4
T_3	1.5	7.0	absent	4.2	0.2	1.4
Nodal sprouts	5.6	24.8	2.0	9.2	7.4	12.8
Contributions	10.0	16.7	2.1	7.6	12.0	19.8
Total growth	15.6	41.5	4.1	16.8	19.4	32.6
Early degeneration	10.3	absent	4.2	--	1.0	--
Middle degeneration	4.4	1.6	7.3	--	2.4	--
Late degeneration	0.1	absent	0.5	--	1.4	--
Total degeneration	14.8	1.6	12.2	--	4.8	--
F.T.I.R.	1.02	1.03	1.02	1.02	1.01	1.01

5. The terminal innervation of ageing cats

The terminal innervation of ageing individuals may be expected to show signs of all the processes of growth and degeneration that have occurred. Accordingly, muscles from cats aged 6, 10 and 18 years old were examined in the same way as muscles from young adult animals. In the following sections, the results of these examinations are presented and compared with those from young adults.

5.1 Morphology of motor end-plates of ageing cats

Only PDQ and soleus muscles were examined, and the number of muscles available was limited by the difficulty of obtaining old animals. Several muscles were excluded because of post-mortem autolysis of the terminal axons and end-plates. These changes were due to unavoidable delays in fixing the muscles prior to silver impregnation. The terminal innervation of soleus appeared to be more resistant to these changes, and consequently more were studied. As before, the results for PDQ and soleus will be presented separately.

5.12 Ten year old peroneus digiti quinti. In order to facilitate comparisons the results of the morphological examination are summarized alongside those of the young adult muscle (Table 4). Examples of end-plates from this muscle are shown in Plate IX.

The most striking feature of the terminal innervation of this muscle was the marked increase in the proportion of the more complex end-plates; T2 end-plates constituted 47.4% of

all endings compared with 21.5% in the young adult PDQ muscles. There was also an increase in the proportion of T3 and T4 end-plates (e.g. Fig. 8b). A few examples of even more complex (T5) end-plates which were not encountered in the young adult muscle were also present.

The incidence of growth configurations was also greatly increased, 41.5% of all endings receiving one or more, compared with 15.6% in the young adult. In contrast to the latter, however, contributions were less frequent than sprouts. Ultra-terminal sprouts were occasionally observed (Plate IXj). The incidence of end-plates receiving two growth configurations was 3.6%, a marked increase over the young adult muscles. The proportions of T1 and T2 end-plates receiving growth configurations were in the ratio of 2 : 1, and the ratio of sprouts to contributions was the same for each type. As in the young adult, end-plates of the T3 form showed less evidence of growth than the two commoner types and configurations interpreted as myelinating contributions were observed (Plate IXb - c).

The F.T.I.R. was 1.03, slightly higher than in the young adult, indicating an increased incidence of collateral branching. However, an increase of this magnitude is unlikely to be significant. One terminal axon branched to form three end-plates on separate muscle fibres. All other cases of collateral branching resulted in the innervation of two muscle fibres by a single terminal axon. In two of these instances collateral plates were formed by several short non-myelinated outgrowths from a node as in Fig. 8a. There were 18 collateral T2 end-plates (37% of all collateral end-plates), fewer than

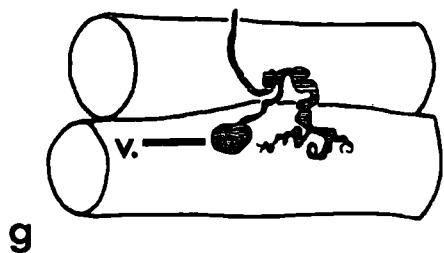
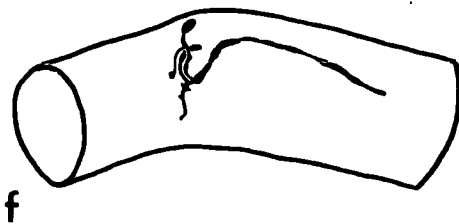
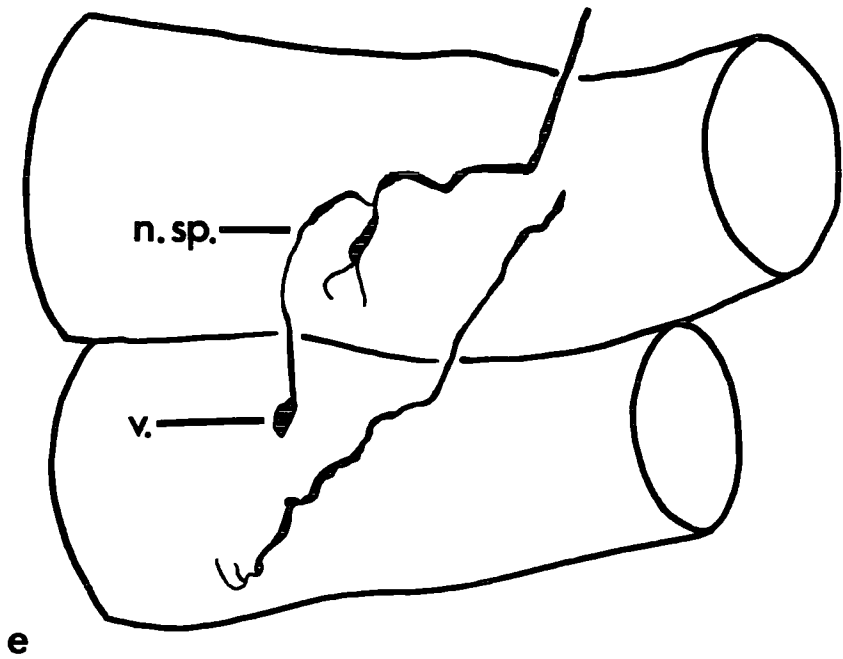
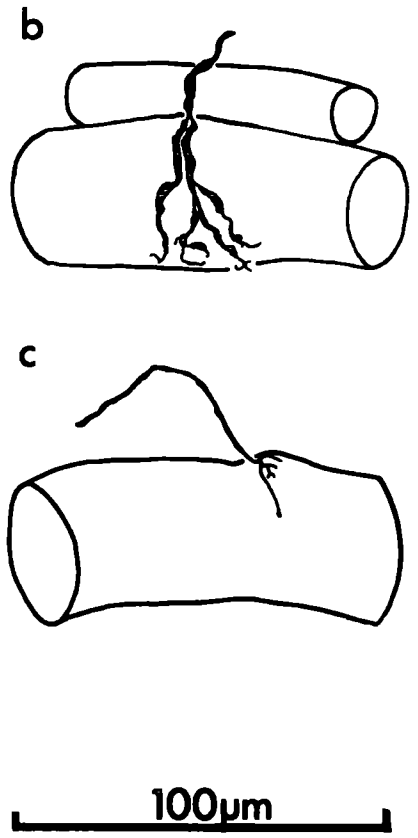
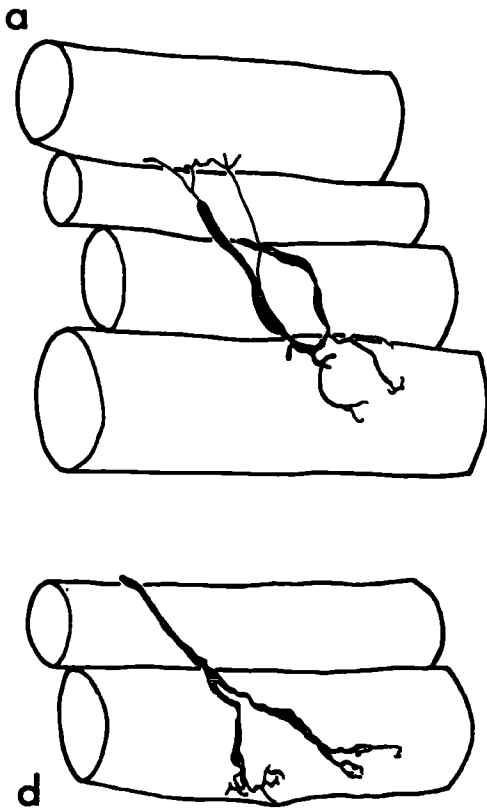
FIGURE 8.

Drawings of motor end-plates

The end-plates were drawn at various magnifications from teased silver preparations but are reproduced to the same scale. The endings in a, c, e and f are camera lucida drawings; those in b, d and g are tracings from photographs.

- a) The lower of this pair of collateral end-plates is formed by non-myelinated outgrowths from a node. The upper end-plate receives a small contribution. Young adult PDQ (C230).
- b) T4 end-plate. Three of the myelinated branches of the terminal axon arise from the terminal node; the fourth arises from a more proximal node. Ten year old PDQ (C294).
- c) A short ultraterminal sprout arises from the axon terminal of an end-plate. It terminates in a growth cone on the same muscle fibre as the parent ending. Ten year old soleus (C294).
- d) Duplex end-plate. The axon terminals from the two myelinated branches of the terminal axon are widely separated. Young adult PDQ (C251).
- e) A nodal sprout (n.sp.) passes towards an end-plate other than the parent ending. It does not make a synaptic contact but ends in a vesicular swelling (v.). Ten year old soleus (C294).

Ccntd.



f) Vesicular axonic swelling on an axon terminal.

Ten year old soleus (C294).

g) Vesicular axonic swelling (v.) on a nodal sprout.

Ten year old PDQ (C294).

expected from the overall proportion of T2 endings in the whole sample (47.4%). Similarly there were proportionately fewer growth configurations (20% compared with 41.5% in the sample). No relationship was apparent between the members of a collateral pair of end-plates, in respect of form, or presence of growth configurations. Thus, in only two cases did a terminal axon form a pair of T2 end-plates, and in only one case did both members show evidence of growth. No degenerating collateral end-plates were observed. Only eight degenerating end-plates were present in the sample, one of these (12.5%) received a growth configuration. All were in the middle phase of degeneration.

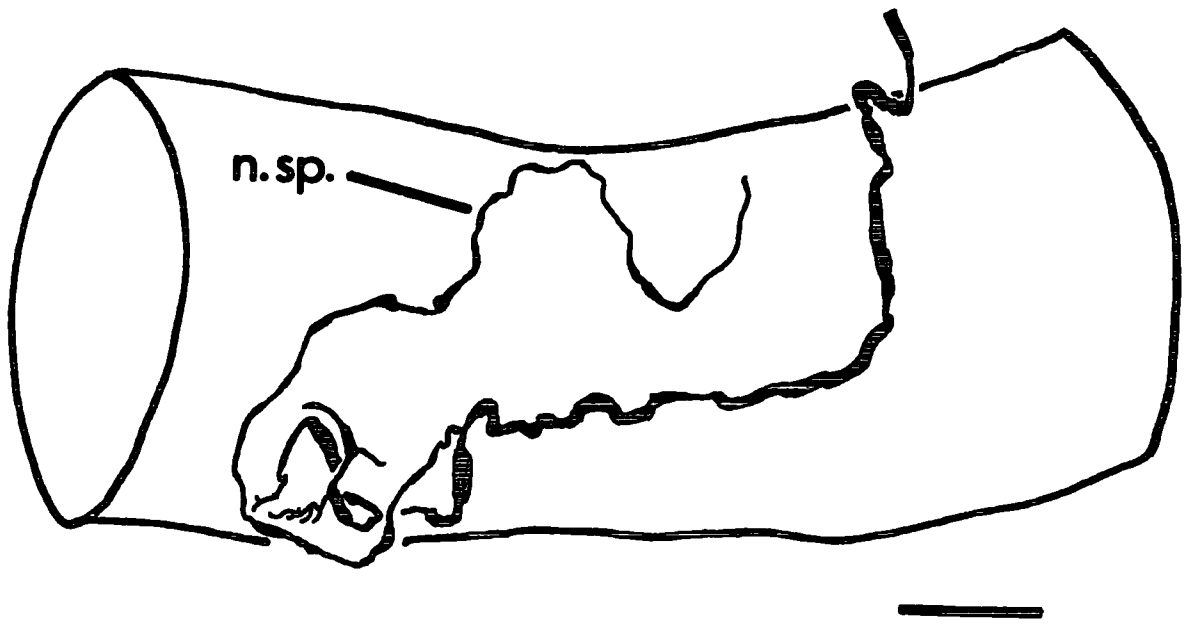
As well as the increased proportions of the more complex end-plates and growth configurations, the end-plates of this muscle appeared to have shorter and fewer axon terminals than those of the young adult PDQ muscles. The sole-plate nuclei were generally well-stained and prominent and appeared to be more numerous than in the young adult (cf. Plate VIc - d, and Plate IXa - c). Such an apparent increase in the number of sole-plate nuclei has been noted by Gutmann & Hanzlikova (1965) in senile rats.

A feature of the terminal innervation of this muscle was the bizarre appearance of many end-plates. Axon terminals were occasionally elongate and even coiled and the terminal axons were often folded up on themselves (Plate IXi) and, in some instances, even appeared to overlie the axon terminals. Vesicular swellings were occasionally found on axon terminals, nodal sprouts or on nerve fibres in the intramuscular nerve trunks (Plate IXg - j, Fig. 8g).

FIGURE 9. Camera lucida drawing of a motor end-plate

This end-plate is illustrated in Plate XIc and is from a teased silver preparation of the soleus muscle of an 18 year old cat (C296). The scale represents 25 μ m.

The nodal sprout passes beyond the end-plate and meanders over the surface of the muscle fibre.



5.13 Soleus muscles of 6, 10 and 18 year old cats. The nature of the changes in the morphology of the end-plates from the soleus muscles of ageing cats was similar to those described in PDQ. Thus the end-plates were often of bizarre form with relatively few axon terminals, and vesicular swellings were occasionally present (e.g. Fig. 8f).

The results of the morphological examination of the terminal innervation of these muscles is summarized in Table 4. The increase in the proportions of the more complex end-plates and growth configurations is even more striking than in PDQ, because of the paucity of these configurations in the young adult muscle. The proportions of T2 and T3 end-plates do not appear to be related solely to the age of the animal, but are greatest in the muscles from the 6 year old cat. However, in all three muscles the increase is unequivocal when compared to the young adult muscle. Selected end-plates from these muscles are illustrated in Plates IX - XI. Two duplex endings were present in each of the muscles from the two oldest animals.

The muscles of all three ageing cats had a much higher proportion of end-plates receiving growth configurations than in the young adult. End-plates of the T2 form received proportionately fewer growth configurations than expected, about 90% of all growth configurations being associated with T1 end-plates. Only the end-plates of the 10 year old cat showed a preponderance of nodal sprouts over contributions. In these muscles too, the only example of a nodal sprout passing to muscle fibre other than the one bearing the parent ending was seen. However,

it did not appear to make synaptic contact with the muscle fibre, which was itself supplied with a separate end-plate. Instead, the sprout ended in a vesicular swelling (Fig. 8e). Other examples of long, wandering nodal sprouts were occasionally encountered, but they never passed to another muscle fibre (e.g. Fig. 9). A few end-plates formed ultraterminal sprouts from their axon terminals, but these were always quite short and never passed far from the parent ending (Fig. 8c). The incidence of end-plates receiving more than one growth configuration was 0.2% in the 10 year old muscle, the same as in the young adult. The incidence in the muscles of the 6 and 18 year old animals was much greater (2.5 and 2.2%, respectively), resembling the situation in a 10 year old PDQ. Some contributions were apparently undergoing myelination in the manner observed in PDQ (Plate Xg).

The F.T.I.R. values of the soleus muscles of the older animals were the same as, or slightly lower than, in the young adult (Table 4). Only one collateral end-plate was of the T2 form; all the others were T1 end-plates. A single case in which a terminal axon branched to supply end-plates to three muscle fibres occurred. One of the collateral end-plates in the 10 year old was a duplex ending and another was formed by short non-myelinated outgrowths from a node. Two unrelated collateral end-plates from the soleus of the 18 year old cat showed evidence of growth (cf. Plate IXh).

It was possible to assess the proportion of degeneration only in the muscles of the 10 year old cat, because the end-plates of the others had undergone some slight

post-mortem changes, rendering it difficult to see the fine detail of the axon terminals. The incidence of degenerating end-plates in this muscle was very low relative to that of the young adult soleus, as was the case in PDQ. As in the young adult, there was a preponderance of endings in the middle phase of degeneration. Growth configurations were associated with only two (8.3%) of the 24 degenerating end-plates in the sample. Both were nodal sprouts and the end-plates were in the final phase of degeneration.

5.2 Measurements of end-plates and muscle fibres of an ageing cat

Measurements were taken only in the 10 year old animal to represent the changes occurring with ageing. The results for PDQ and soleus muscles are tabulated separately (Tables 5 and 6, respectively), alongside the corresponding results for the young adult muscles. The end-plates of the muscles of older cats show the same tendency to increase in size and number of axon terminals with increasing complexity, as in the young adult muscles. However, the end-plates are the same size as in the young adult muscles and have fewer axon terminals. These findings support the morphological observations. The diameter of the muscle fibres is greatly increased relative to those of the young adult muscles.

5.21 Ten year old peroneus digiti quinti. The end-plate and muscle fibre diameters show a statistically significant degree of correlation ($r = 0.35$, $P < 0.02$) as they did in the young adult. The lower level of significance in the older animal may be attributed to the smaller size of sample.

It was not possible to do a direct test of the degree of correlation between the number of axon terminals and the other parameters because it was not estimated at the same time as the measurements were taken. However, it is clear from Table 5 that all three parameters show the same tendency to increase with the increasing complexity of the form of the end-plate. As in the young adult, the distribution of the end-plate diameters shows both skew and kurtosis to a significant extent ($g_1 = 1.16$, $P < 0.05$; $g_2 = 2.40$, $P < 0.001$). There is no significant difference between the end-plate diameters of the young and old animals. The mean number of axon terminals is significantly lower than in the young adult muscles, and shows the same deviation from the normal distribution ($g_2 = 0.52$, $P < 0.001$).

The mean muscle fibre diameter is significantly ($P < 0.05$) greater in the 10 year old animal for each form of the end-plate, except where the sample size is very small (Table 5). This increase in the muscle fibre diameters of the older animal is reflected in their distribution, which is shifted to the right relative to that of the young adult muscles (Fig. 10). There is a second smaller peak at the upper end of the range, which confers a moderate amount of skew to the population ($g_1 = 0.77$, $P < 0.05$).

The increased muscle fibre diameter combined with an unchanged end-plate diameter means that the percentage ratio of 42.3 (S.E. 1.29) is significantly lower ($P < 0.001$) than in the young adult. The mean axial ratio in this muscle is 1.15, lower than in the young adult ($P < 0.05$), indicating that the end-plates become more rounded with ageing.

TABLE 5. Results of measurements of end-plates and muscle fibres of PDQ muscles

The data are shown for each form of the end-plate, arranged in order of increasing complexity. The sample means are the values for the largest possible samples and not necessarily derived only from the data shown. In each group a represents the mean number of axon terminals per end-plate, b the mean end-plate diameter (μm), and c the mean muscle fibre diameter (μm). The number of end-plates in each group (n) and the standard error of the mean (S.E.) are given. The probability (P) of significant differences between corresponding values of muscles of different ages is given; non-significant differences are indicated by NS. Significant deviations from the normal distribution are indicated by superscripts (see text).

End-plate type	Young adult PDQ				P	10 year old PDQ			
	n	mean	(S.E.)	n		mean	(S.E.)		
T ₁	a	129	5.6	(0.16) [‡]	< 0.001	46	4.5	(0.22)	
	b	65	26.6	(0.61)		< 0.05	7	23.9	(1.16) [‡]
	c	65	53.0	(1.29)		< 0.05	7	59.0	(2.20)
T ₁ + sprout	a	24	7.6	(0.38)	< 0.001	22	5.2	(0.42) [†]	
	b	18	26.3	(0.93)		NS	8	25.9	(1.77)
	c	18	53.1	(1.68)		< 0.02	8	65.7	(4.86)
T ₁ + contri- bution	a	40	8.2	(0.30)	< 0.001	22	6.0	(0.39)	
	b	28	28.6	(1.15) [‡]		NS	7	26.6	(1.01)
	c	28	53.9	(1.21)		< 0.01	7	67.5	(4.06)
T ₂	a	51	7.9	(0.36)	< 0.001	85	4.9	(0.15)*	
	b	28	29.4	(1.14)		NS	17	29.3	(1.54)
	c	28	53.5	(1.72)		< 0.001	17	67.3	(3.08)
T ₂ + sprout	a	4	10.3	(0.75)	< 0.001	17	6.0	(0.47)	
	b	5	37.9	(2.62)		< 0.05	4	29.1	(2.95)
	c	5	64.3	(3.56)		NS	4	64.1	(9.05)
T ₂ + contri- bution	a	5	12.6	(1.90)	< 0.001	2	8.5	(0.50)	
	b	6	37.2	(4.81)		--	--	--	--
	c	6	57.4	(3.32)		--	--	--	--
T ₃	a	6	8.2	(0.40)	NS	7	6.6	(0.69)	
	b	7	30.1	(2.16)		NS	4	31.0	(3.84)
	c	7	53.9	(4.89)		NS	4	69.5	(8.06)
Sample Mean	a	197	6.3	(0.14)*	< 0.001	229	5.3	(0.12)*	
	b	171	28.7	(0.49) [†]		NS	50	27.4	(0.78) [†]
	c	171	53.7	(0.72)		< 0.001	50	65.5	(1.70)*

*g₁ statistically significant

†g₂ statistically significant

‡g₁ and g₂ statistically significant

5.22 Ten year old soleus. Despite the increased incidence of complex endings in this muscle, relative to the young adult, it was still not possible to obtain adequate numbers for statistical analysis. However, although the sample sizes for the more complex forms are still small, it can be seen that the number of axon terminals and the muscle fibre diameters tend to increase with increasing complexity of the end-plate as in the 10 year old PDQ muscles (Table 6). These two parameters were significantly correlated ($r = 0.41$, $P < 0.01$), but, as in the young adult soleus, the end-plate and muscle fibre diameters were not.

In general, the changes occurring with age were the same as in PDQ. Thus there is a significant reduction in the mean number of axon terminals ($P < 0.01$) while the mean end-plate diameter is unchanged. The mean muscle fibre diameter is significantly greater ($P < 0.001$) in the 10 year old soleus, and the distribution shows the same shift to the right seen in PDQ. However, the range is also increased and the population follows the normal distribution (Fig. 10). The concomitant of this increased muscle fibre diameter with an unchanged end-plate diameter is, as in PDQ, a significant ($P < 0.001$) reduction in the percentage ratio of these parameters to 30.4 (S.E. 5.28). Unlike PDQ, the axial ratio is not significantly different from that of the young adult, indicating that the general shape of the end-plates is unchanged.

TABLE 6. Results of measurements of end-plates and
muscle fibres of soleus muscles

(For description see legend to Table 5)

End-plate type		Young adult soleus <u>n</u>	mean	soleus (S.E.)	<u>p</u>	10 year old soleus <u>n</u>	mean	soleus (S.E.)
T ₁	<u>a</u>	129	4.3	(0.12)	< 0.01	82	3.7	(0.16)*
	<u>b</u>	41	22.7	(0.82)‡	NS	33	25.3	(1.08)
	<u>c</u>	41	71.4	(1.25)	< 0.001	33	82.5	(2.40)
T ₁ + sprout	<u>a</u>	5	5.8	(1.46)	NS	7	3.6	(0.30)
	<u>b</u>	-----	-----	-----	-----	3	15.7	(2.75)
	<u>c</u>	-----	-----	-----	-----	3	81.9	(5.90)
T ₁ + contri- bution	<u>a</u>	4	4.5	(0.50)	NS	10	4.4	(0.22)
	<u>b</u>	-----	-----	-----	-----	10	26.3	(1.72)
	<u>c</u>	-----	-----	-----	-----	10	76.5	(3.07)
T ₂	<u>a</u>	-----	-----	-----	-----	9	5.0	(0.41)
	<u>b</u>	-----	-----	-----	-----	3	26.5	(3.56)
	<u>c</u>	-----	-----	-----	-----	3	88.4	(3.19)
Sample Mean	<u>a</u>	139	4.4	(0.13)	< 0.01	108	3.9	(0.14)*
	<u>b</u>	41	22.7	(0.82)	NS	50	24.8	(0.90)
	<u>c</u>	41	71.4	(1.25)	< 0.001	50	81.4	(1.78)

*g₁ statistically significant

‡ g₁ and g₂ statistically significant

FIGURE 10. Histograms of muscle fibre diameters of PDQ and soleus muscles of young adult and 10 year old cats

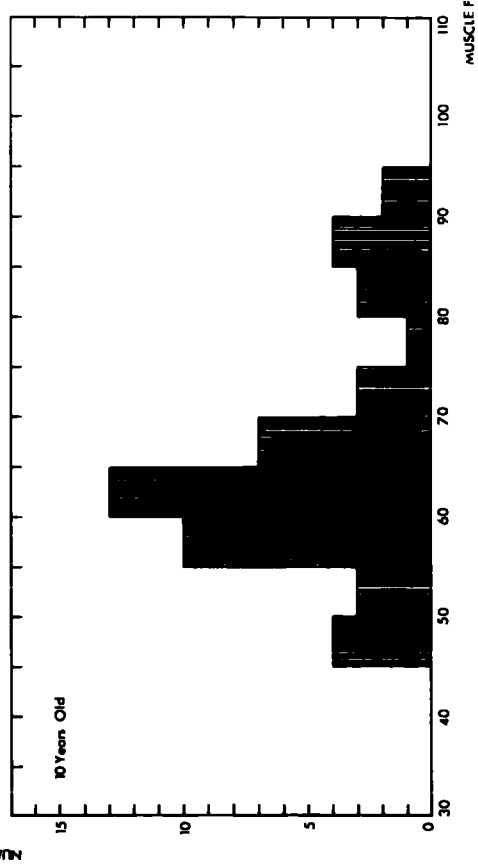
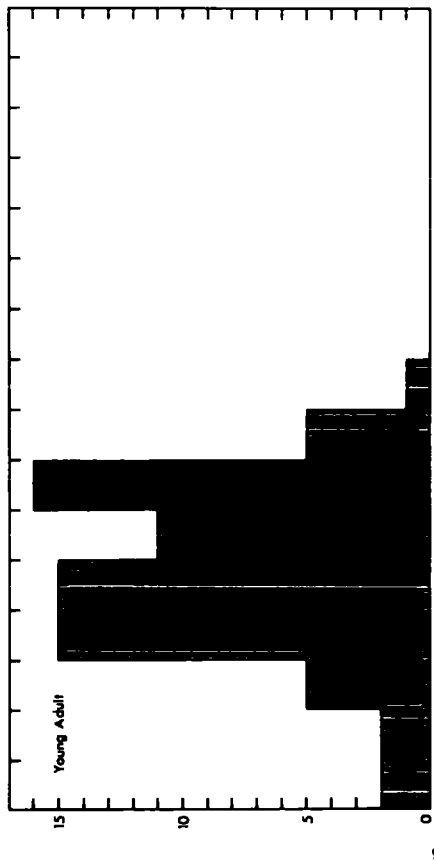
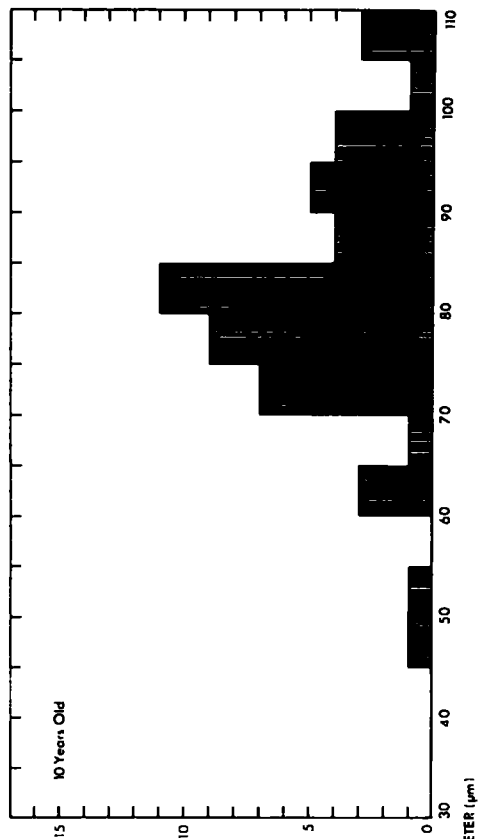
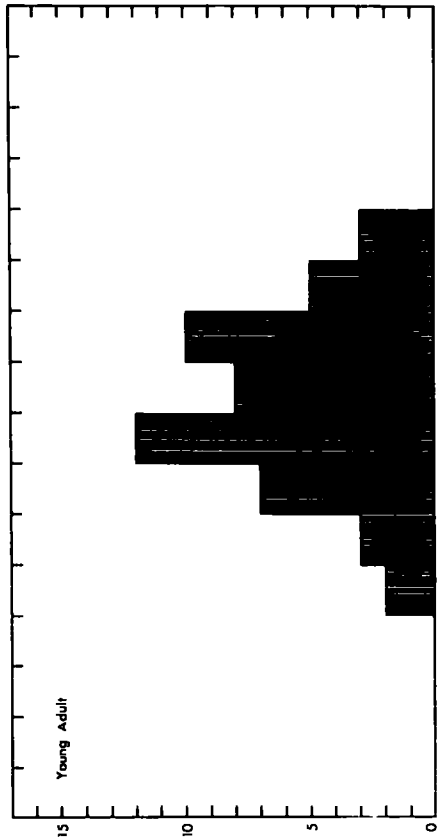
All measurements were made on teased silver preparations. The number of fibres measured was 72 in the young adult PDQ, and 50 in each of the other muscles. The mean values are :-

young adult PDQ, 56.7 μ m (S.E. 1.40);
young adult soleus, 70.9 μ m (S.E. 1.21);
10 year old PDQ, 65.6 μ m (S.E. 1.70);
10 year old soleus, 81.4 μ m (S.E. 1.78)

The distribution in the PDQ of the 10 year old cat (lower left) shows a slight positive skew ($g_1 = 0.77$, $P < 0.05$). The other distributions show no statistically significant deviation from the normal.

SOLEUS

PDQ



NUMBER OF MUSCLE FIBERS

MUSCLE FIBRE DIAMETER (µm)

5.3 Numbers of muscle fibres

The cat is unsuited to quantitative studies of ageing phenomena because of the difficulties of obtaining sufficient numbers of older individuals to ensure adequate statistical samples. However, counts of the numbers of muscle fibres present in transverse sections through the belly of PDQ muscles of ageing cats did indicate that muscle fibres are lost with increasing age. Thus, the number of muscle fibres in PDQ muscles of cats aged 1, 18 and 19 years were 4,794, 2,409 and 1,852 respectively. This finding confirms observations made on various muscles of the rat, both during the present study and by other workers (Andrews, Shock, Barrows & Yiengst, 1959; Gutmann & Hanzlikova, 1966; Rowe, 1969).

However, although representative sections of all muscles sectioned in the course of this study were carefully examined, no evidence of abnormalities suggestive of denervation atrophy was found. All the muscle fibres had a rounded appearance in cross-section and none had the central nuclei or irregular profile commonly associated with atrophy (Greenfield, Shy, Alvord & Berg, 1957; Bethlem, 1970). It may be that the rate of loss of muscle fibres, particularly in the young adult, is so low that no atrophic fibres were present in the sections examined.

5.4 Conclusions

It is clear from the morphological observations that there is a marked increase in the frequency of the more

complex forms of motor end-plates. As might be expected, these more complex forms tend to be larger and to have more axon terminals. There is also a considerable increase in the incidence of growth configurations. These findings lend support to the hypothesis that the evidence of growth seen in the terminal innervation of normal muscles of young adult animals is associated with the formation of complex end-plates. The loss of muscle fibres with ageing also strengthens the idea that the growth and degeneration of motor end-plates are unrelated.

However, this study produced some further observations that require explanation. Firstly, the increase in the proportion of more complex end-plates is not precisely related to the age of the animal. In fact, it can be seen from Table 6 that in soleus, it is more closely related to the body weight. Secondly, the muscle fibres are greatly enlarged in the muscles of older animals. These two observations suggest that a major factor in the elaboration of motor end-plates might be the amount of work the neuromuscular system is required to do. This problem has been investigated and the results will be presented in the ensuing sections.

6. Effects of use and disuse in kittens

In order to determine the effects of activity upon the morphology of the motor end-plates a series of experiments were performed, involving the tenotomy and exercise of kittens at a stage when it was expected that their end-plates were attaining the adult form.

The results showed a wide variation in respect of all the parameters measured (muscle weights, end-plate and muscle fibre diameter, axial ratio, number of axon terminals and end-plate morphology). Consequently, only a brief summary of the findings will be presented.

6.1 Tenotomy

As judged by the criterion of muscle weight, tenotomy was successful in producing a relative atrophy of both gastrocnemius and soleus. However, the muscle fibre diameters did not support this. The end-plates of the tenotomised muscles showed the highest incidence of T2 end-plates and the incidence of growth configurations was higher than in all muscles except those of the exercised animal.

6.2 Exercise

On the criteria of muscle weight and muscle fibre diameter the exercise could not be said to have produced any significant effect. However, there was a greater incidence of growth configurations than in the other muscles.

6.3 Conclusions

From the above resume of the results of the experiment it cannot be said that any consistent effects were produced by the experimental treatments. This may be attributable to the short experimental period. Perhaps a longer period is required for the neuromuscular system to react to the stresses imposed upon it. Certainly, longer periods have been used to demonstrate the effects of tenotomy upon the contractile characteristics of muscles (Salmons & Vrbova, 1969; Buller & Lewis, 1965) and Gordon (1967) in a review of the effects of exercise has stated that it is the duration of exercise rather than its intensity that produces the observed results. Other observations on the effects of tenotomy indicate that it does not affect all muscle fibres equally, producing atrophy in some and hypertrophy in others (Engel et al., 1965). Studies of the effects of tenotomy on motor end-plates indicate that some are enlarged while others are reduced in size (Falin, 1935; Gladden, 1971). Thus, it would appear that in such studies tenotomy is not a suitable model for disuse atrophy.

TABLE 7. Morphology of motor end-plates of a soleus
muscle after surgically-induced
hypertrophy

(For description see legend to Table 2)

	T ₁	T ₂	T ₃	Total
Total	68.9	28.3	2.6	100.0
Nodal sprouts	2.8	3.7	-	2.9
Contributions	14.8	8.1	6.7	12.7
Total growth	17.6	11.8	6.7	15.6
Early degener- ation	3.6	1.2	-	2.8
Middle degener- ation	1.8	0.6	-	1.4
Total degener- ation	5.4	1.9	-	4.2

F.T.I.R. 1.02

7. Surgically-induced hypertrophy

In the following sections the results of the study of the end-plates in a soleus muscle of a young adult cat 84 days after tenotomy of the synergist gastrocnemius are presented and compared with those from the normal soleus muscle of a young adult animal (Results, 2.2, and 3.2). Since it appears that the variations between individual animals are small (Results, 2.1), it was preferred to use the latter muscle as a control rather than the contralateral muscle of the operated animal because the effects of unilateral operation on the unoperated side of the animal are unknown. Thus, the weight of the unoperated soleus muscle was 2.97g, slightly greater than might be expected from the body weight of 3.01kg (cf. Fig.20), which might mean that some hypertrophy had occurred in this muscle too. The weight of the soleus muscle of the operated limb was 3.61g, 24.6% greater than that of the contralateral muscle and hence the attempt to induce hypertrophy was judged to have been successful. Examples of end-plates from the hypertrophied soleus muscle are shown in Plate XII.

7.1 Morphological results

In terms of their general appearance, the end-plates of the hypertrophied soleus muscle were larger, with more numerous, longer and finer axon terminals than those normally seen in soleus (cf. Plates VII and XII). Complex endings, which are normally virtually absent from the normal soleus (Table 4), constituted approximately 30% of the sample (Table 7). A single end-plate of the T4 form was encountered (Plate XIIh).

The incidence of growth configurations was 15.6%, a threefold increase compared to the normal muscle. Over 80% of all growth configurations were contributions and proportionately more passed to T1 endings. Four T1 end-plates (less than 1% of the sample) received more than one growth configuration, compared with one in the normal muscle.

The F.T.I.R. was 1.02, indicating that there was no increase in the incidence of collateral branching. No terminal axon formed end-plates on more than two muscle fibres, and no degenerating collateral or T3 end-plates were observed. End-plates of the T2 form constituted 58.3% of all collateral endings, twice the proportion in the sample as a whole. As in the other muscles described above, no correlation was apparent between the members of collateral pairs in respect of their form or the presence of growth configurations.

Degenerating end-plates were less common than in the normal muscle and the majority were in the earliest phase of degeneration.

7.2 Measurements

The results of the estimations of the number of axon terminals per end-plate and the measurements of end-plates and muscle fibres are given in Table 8. Selection for measurement was solely on the basis of clarity and the sample may therefore be considered random.

Considering firstly the values for the population as a whole, it is apparent that the mean muscle fibre diameter is unchanged relative to that of the normal young adult muscle (Table 6). This finding is at variance with the large increase

in muscle weight and no satisfactory explanation is available. However, the distribution of the muscle fibre diameters is very different from that of the young adult (cf. Figs. 10 and 11), having a greater range and showing a statistically significant degree of flattening ($g^2 = - 0.48$, $P < 0.05$).

The mean number of axon terminals per end-plate and the mean end-plate diameter are both significantly greater than the corresponding values of the normal muscle ($P < 0.001$ in each case). This confirms and quantifies the morphological observations reported above. The distribution of the end-plate diameters is shifted to the right, relative to that of the normal soleus muscle, and shows both skew and kurtosis to a statistically significant degree, whereas that of the normal soleus muscle has a normal distribution. These changes are consistent with the formation of larger end-plates as a result of hypertrophy. The enlarged end-plate diameter reflects not only the fact that there are more axon terminals, but also that they are longer. The increased mean end-plate diameter with an unchanged mean muscle fibre diameter results in a percentage ratio of 38.3 (S.E. 0.83), significantly greater than that of the normal muscle ($P < 0.001$).

The axial ratio is 1.13 (S.E. 0.055), lower than that of the normal soleus ($P < 0.05$), indicating that the end-plates of the hypertrophied muscle are more rounded. Since the end-plates of the normal soleus are elongated in the long axis of the muscle fibres (axial ratio 1.41), any growth that has occurred must have been principally in the short axis of the muscle fibres. This again supports the elongation of axon terminals because the terminal axon is usually orientated so that it meets the muscle fibre approximately at a right angle.

The diameters of the end-plates and muscle fibres showed a statistically significant degree of correlation ($r = 0.53$, $P < 0.001$; Fig.13), unlike the normal young adult muscle (Results, 3.1). The number of axon terminals was also positively correlated with the end-plate diameter ($n = 89$, $P < 0.001$; Fig.12), so that, as in the other muscles where it was possible to relate these parameters, larger end-plates tend to have a greater number of axon terminals and to lie on larger muscle fibres.

On considering the values for the separate forms of the end-plate (Table 8), a comparison with the normal muscle is only possible for simple T1 end-plates, because of the scarcity of more complex forms (Table 4). The slight increase in the mean end-plate diameter of simple T1 end-plates in the hypertrophied muscle is not statistically significant, showing that the greater mean end-plate diameter of the whole population is due to the increased proportion of larger, more complex end-plates, i.e. to the process of end-plate elaboration.

That the more complex endings are indeed larger is shown by the fact that the simple T1 end-plates are significantly smaller than those receiving growth configurations and T2 end-plates ($P < 0.001$ in each case). The difference between simple T1 endings and T2 endings receiving growth configurations is not statistically significant, presumably due to the greater variation in the latter (Table 8). Similarly, the more complex endings have significantly more axon terminals and tend to lie on larger muscle fibres.

TABLE 8. Measurement of end-plates and muscle fibres
of a hypertrophied soleus muscle

The results are shown separately for several forms of the end-plate. The values for some types have not been shown separately because of small sample sizes, but they are included in the total values. The number of measurements (n) is shown for each mean, together with the standard error of the mean (S.E.). Statistically significant deviations from the normal distribution are indicated by superscripts.

	Number of Axon Terminals		End-plate Diameter (μm)		Muscle Fibre Diameter (μm)	
	n	mean (s.e.)	n	mean (s.e.)	n	mean (s.e.)
T ₁	112	5.5*	46	24.1 0.70	46	67.5 2.37
T ₁ + growth	25	6.6 0.37	15	28.1 0.75	15	74.7 3.67
T ₂	48	6.2 0.24	25	28.4 0.99	25	76.6 3.38
T ₂ + growth	9	8.3 0.44	10	28.3 1.66	10	73.7 4.95
Sample Mean	206	6.0*	100	26.6****	100	71.5***

* g₁ statistically significant;

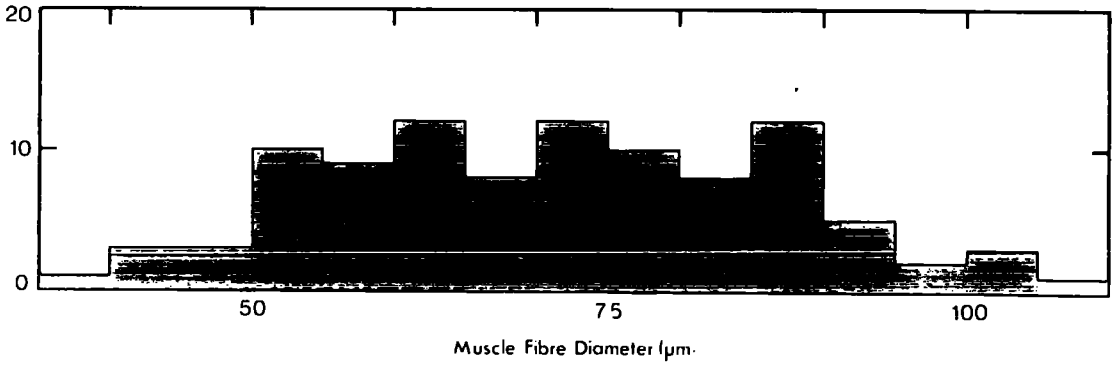
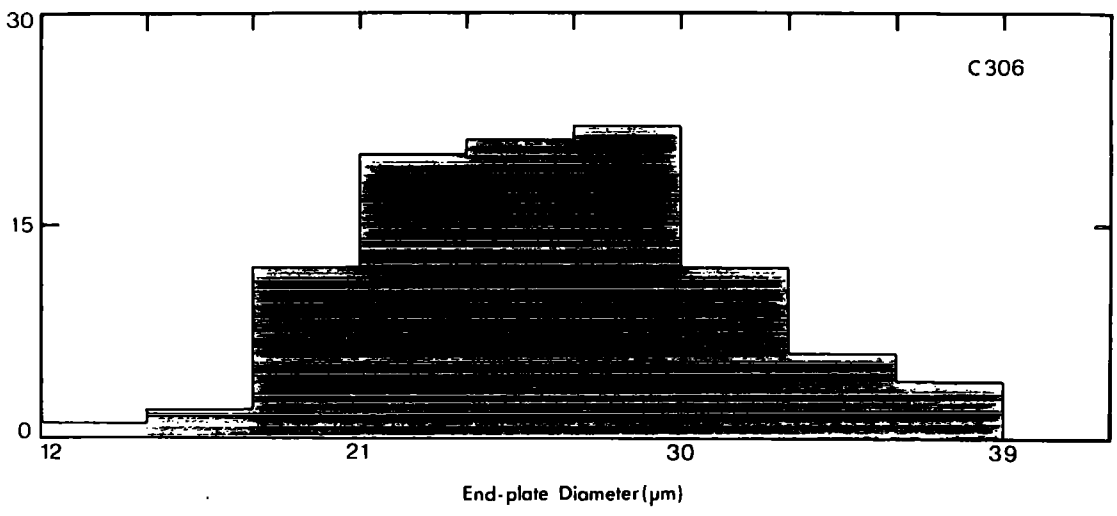
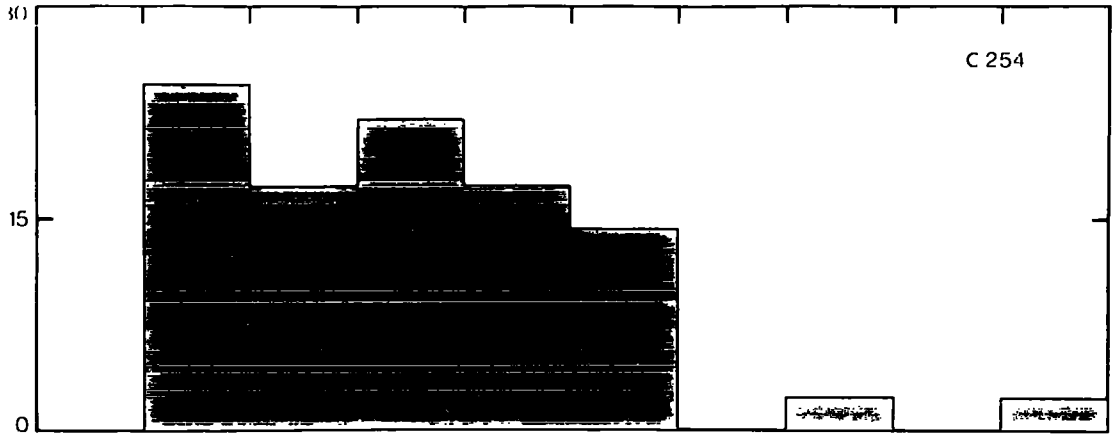
** g₂ statistically significant;

*** g₁ and g₂ statistically significant

FIGURE 11. Distribution of end-plate and muscle fibre diameters after surgically-induced hypertrophy

The upper two histograms show the percentage distributions of end-plate diameters in soleus muscles from a normal young adult cat (C254, $n = 41$) and after surgically-induced hypertrophy (C306, $n = 100$). Both are to the same scale. The end-plate diameters of the normal muscle have a normal distribution, but in the hypertrophied muscle the distribution shows both skew and kurtosis to a moderate degree, and is shifted to the right.

The lowest histogram shows the percentage distribution of the muscle fibre diameters after hypertrophy ($n = 100$). The distribution is flattened ($g_2 = -0.48$, $P < 0.05$), resulting in a greater range than in the normal muscle, although the mean is unchanged (cf. Fig. 10, upper right).



As in the other muscles examined, fewer of the correlations between parameters are statistically significant than in the population as a whole because of the reduced sample sizes. Thus, the correlation between the end-plate and muscle fibre diameters is significant only in the cases of simple T1 endings ($r = 0.59$, $P < 0.001$) and simple T2 endings ($r = 0.48$, $P < 0.02$). The correlation between the number of axon terminals and the end-plate diameter is significant only in the case of simple T1 endings ($n = 43$, $r = 0.45$, $P < 0.01$).

The only other study of the effects of hypertrophy upon the form of motor end-plates appears to be that of Granbacher (1971), who used a cholinesterase technique on rat soleus muscles 14 days after surgically-induced hypertrophy. The cholinesterase method gives no information about the mode of formation of the end-plates, but Granbacher found a slight increase in the mean number of sub-elements in each end-plate and more pronounced increases in the total end-plate area and the mean synaptic area. In this respect, the observations agree with those of the present study. However, Granbacher also noted that the end-plate and muscle fibre diameters were no longer correlated in the hypertrophied muscles as they were in unoperated muscles. This is the converse of the situation in cat soleus muscles, where the end-plate and muscle fibre diameters are not normally correlated, but become so after hypertrophy.

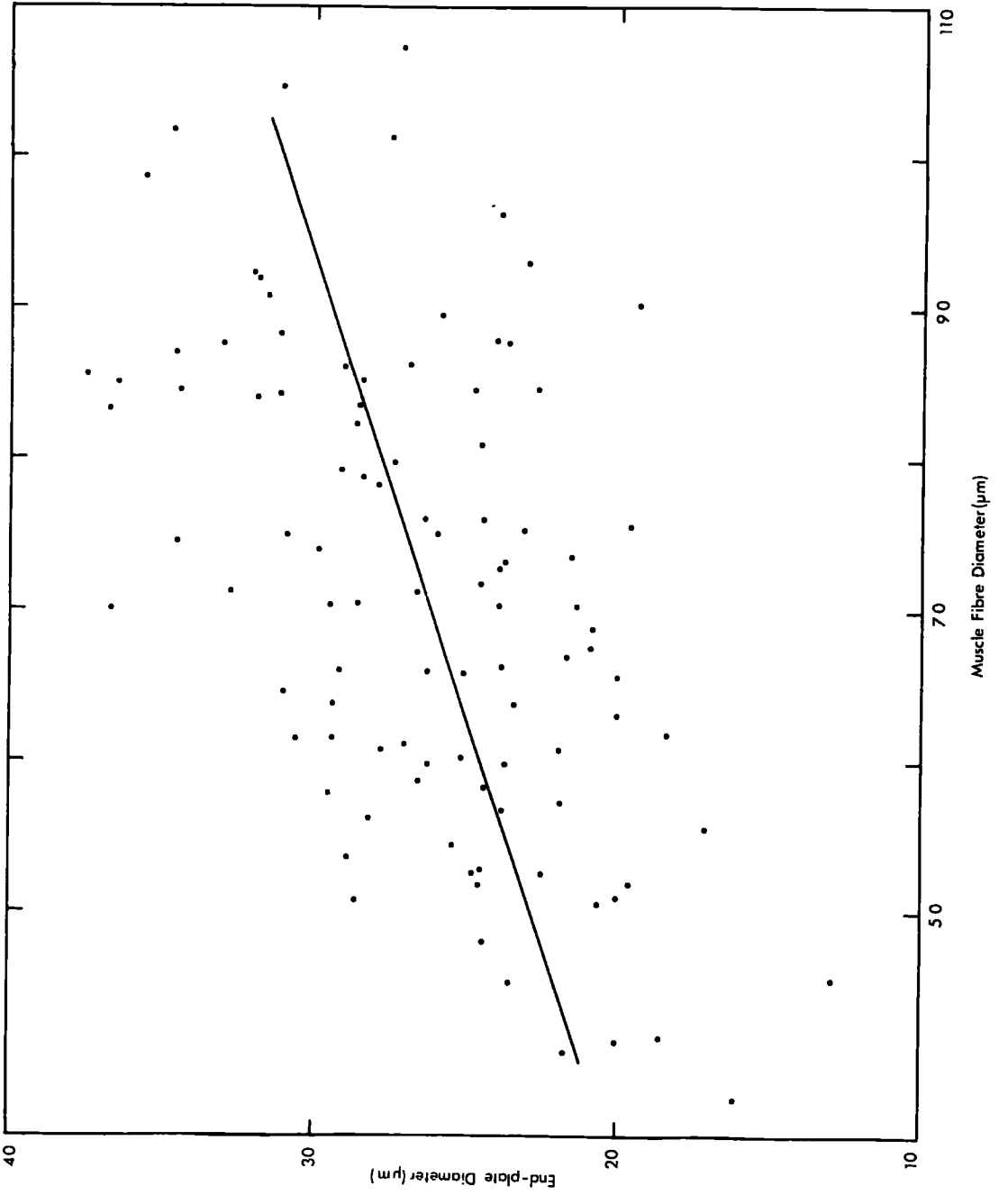
FIGURE 12. Graph of the number of axon terminals and end-plate diameters of a soleus muscle after surgically-induced hypertrophy

The sample size is 89. The correlation is highly significant ($r = 0.37$, $P < 0.001$; $y = 0.16x + 2.50$).

Some points have been slightly displaced along the ordinate to improve clarity.

FIGURE 13. Graph of end-plate and muscle fibre diameters of a soleus muscle
after surgically-induced hypertrophy

The sample size is 100 (one point has been omitted; muscle fibre diameter, $112.7\mu\text{m}$; end-plate diameter $33.9\mu\text{m}$). The correlation is highly significant ($r = 0.53$, $P < 0.001$; $y = 0.16x + 14.63$), unlike that of the normal soleus.



7.3 Conclusions

The concept of end-plate elaboration as a response to increasing functional demands upon the muscle is supported by two principal findings. First, after hypertrophy, complex endings that are normally absent from soleus form a large proportion of all end-plates. Second, the mean end-plate diameter is significantly increased due to the presence of larger, more complex end-plates. In addition, the number of axon terminals is also significantly greater than in the normal soleus muscles of young adult cats. In all these respects, the changes in the morphology of motor end-plates that take place after surgically-induced hypertrophy resemble those occurring during ageing (except for the absence of bizarre forms which may be ascribed to the decline in the regulative properties of ageing neurones).

Although the analysis of the changes in the morphology of motor end-plates during hypertrophy is based upon a single experimental animal and further replicates are obviously desirable, it is an important confirmation of the existence of end-plate elaboration.

In the final section of the Results, consideration is given to the possibility that some or all of the variations in the morphology of motor end-plates in normal muscles of young adult cats are related to variations in the histochemical properties of muscle fibres.

8. Histochemical studies

Several workers have attempted to correlate the morphological characteristics of motor end-plates with the functional types of the muscle fibre. The results of these attempts vary from general statements relating the size of end-plates with the speed of contraction of the muscle as a whole, to more precise evaluations of variations in morphology or ultrastructure. Thus, Gerebtzoff et al. (1954) considered that in the cat the end-plates of the slow soleus were smaller than those of the faster muscles, such as tibialis anterior and diaphragm. However, Nystrom (1968b) was unable to confirm this finding and reported fairly marked differences in the structure of end-plates in fast and slow muscles of the cat. The end-plates of gastrocnemius had a 'fairly wide spreading of the end ramifications' which were 'rather long and smooth'. In soleus, however, the axon terminals were 'more tightly packed, and they were wrinkled and fluted in outline, as well as being shorter than those of gastrocnemius'. In addition, the axon terminals often lay to one side of the terminal axon (Nystrom, 1968b, p.367). Nystrom also observed that the end-plate and muscle fibre diameters were positively correlated in both muscles (Nystrom, 1968b) but that the muscle fibre diameter was not a reliable criterion of the muscle fibre type (Nystrom, 1968c). Some of these observations have been discussed above (Results, 3.3). Studies of rat muscles have indicated that there is a relationship between the morphology of the end-plates and the types of muscle fibre (Ogata, 1965; Padykula & Gauthier, 1970; Duchen, 1971).

In view of these observations it seemed appropriate to investigate the nature of the histochemical types of muscle fibres and their frequencies in the muscles studied, and to attempt to correlate the results with the frequencies of end-plate types and of growth and degeneration. The relationship of fibre type and size was also assessed, both quantitatively and qualitatively. A further study was undertaken to determine the relationship between the size and structure of the end-plate after staining for cholinesterase activity, and of the muscle fibre, as shown by its SDH activity. As a result of these investigations it might be possible to determine whether any of the observed morphological variations were attributable to muscle fibre type, rather than to elaboration.

8.1 Classification of muscle fibre types

Several types of muscle fibre have been recognized on the basis of the activity of various enzymes although the number of types recognized in a given species has varied with both the species and the type of enzyme activity examined. There is also some disagreement between different workers.

In man there are normally only two types (Engel, 1965; Morris & Woolf, 1970), in the rat up to eight types have been differentiated (Romanul, 1964) although only three are commonly recognized (e.g. Stein & Padykula, 1962; Guth & Samaha, 1969). In the cat, Engel et al. (1965) differentiated only two types on the basis of myofibrillar ATPase activity, whereas Henneman & Olson (1965) recognized three

types on the basis of the activity of mitochondrial ATPase. Nystrom (1968c) using a combination of methods for oxidative and phosphorylytic activities described three types in fast muscles with a fourth type peculiar to slow muscles such as soleus. The activity of each of the three enzymes studied (SDH, ATPase and P'ase) was classified as high, intermediate or low, according to the criteria shown in Table 9). Since it has generally been observed that the activities of ATPase and P'ase are generally the same in each muscle fibre, they may be classed together as phosphorylytic enzymes. For the purposes of typing, intermediate activities are classed as highly active.

The nomenclature of fibre types has been fully discussed by Edgerton & Simpson (1969) and Guth & Samaha, 1969. Since the histochemistry of muscle fibres forms a relatively minor part of this study, only sufficient detail to permit a clear understanding of the results will be presented. It was decided to designate fibres with both high oxidative and high phosphorylytic activity as 'C' fibres. Those with high oxidative and low phosphorylytic activity are described as 'B' fibres, and those with low oxidative and high phosphorylytic activity as 'A' fibres. This A, B, C system of nomenclature is based upon the activities of both oxidative and phosphorylytic enzymes and corresponds to that used by other workers (Nystrom, 1968c; Edgerton & Simpson, 1969; Guth & Samaha, 1969).

Guth & Yellin (1971) have pointed out that the classification of muscle fibre types in this way is an oversimplification of the true variation of their histochemical

activities. Indeed, when the activity of each enzyme was assessed on a three-point scale, 20 of the 27 theoretically possible fibre types were encountered in the three peroneal muscles. However, because the A, B, C system of classification has been used elsewhere and no satisfactory alternative has yet been proposed, it has been adopted in the present account.

The three fibre types of the fast peroneal muscles are illustrated in Plates XIII- XIV. These corresponded with those described by Henneman & Olson (1965) and Nystrom (1968c). Only six of the 300 peroneal muscle fibres examined did not fall into one of these three categories. Of these, five showed a positive reaction for P'ase and a negative one for ATPase, while the other fibre had the reciprocal reaction. These fibres were classified according to whether the reaction with SDH was high (C fibre) or low (A fibre). All the fibres of soleus were of the same type, which did not occur in the peroneal muscles (Plate XIII), having low activity with ATPase and P'ase and high activity with SDH. In this they resembled the B fibres of the peroneal muscles. However, the diformazan granules were very fine, extremely numerous, and evenly distributed, unlike those of the B fibres which were coarse and aggregated at the periphery of the fibre. The soleus fibres correspond to the 'S' fibres of Nystrom (1968c). The 'aberrant fibres' with high ATPase activity described in soleus muscles by Nystrom (1968c, p.415) were not observed. That the peculiar staining properties of soleus muscle fibres were not due to any deficiencies in technique is demonstrated by the presence of intrafusal fibres, connective tissue and capillaries giving positive reactions with ATPase and P'ase.

TABLE 9. Assessment of enzyme activities of muscle
 fibres

The criteria are shown for assessing the degree of activity in muscle fibres stained for the activity of succinic dehydrogenase (SDH), phosphorylase (P'ase) or alkaline-stable actomyosin triphosphatase (ATPase).

TABLE 10. Frequencies of muscle fibre types

The percentages of fibres of each of the three histochemical types in the three peroneal muscles of a young adult cat (C303). The total number of fibres typed was 100 in each case.

Activity	High	Intermediate	Low
SDH	Many coarse granules, with peripheral aggregation.	Fewer, fine, evenly distributed granules.	Very few fine scattered granules.
Pase	Blue or blue-black.	Brown.	Yellow.
ATPase	Dark brown.	Very pale brown.	Colourless.

Fibre Type	A	B	C
PDQ	52	4	44
PB	38	24	38
PL	41	14	45

8.2 Frequency of fibre types

In all three peroneal muscles, the fibre types were scattered throughout the muscle in an apparently random fashion. The results of typing 100 muscle fibres in representative fascicles of all three peroneal muscles are summarized in Table 10. In each case the proportions of A and C fibres are similar. Thus, the characteristic variation between different muscles is in the proportion of B fibres (see also Guth & Samaha, 1969). The proportions of the different fibre types are in good agreement with the only published data on these muscles (Barker et al., 1970). However, it is not possible to correlate the fibre types directly since Barker et al. based their classification on P'ase activity alone and only distinguished two types of muscle fibre.

On comparing the frequencies of muscle fibre types with the frequencies of the morphological types of end-plate in soleus, PDQ (Table 4) and PB (Table 3), no obvious correlation can be seen. From the soleus data alone it might be expected that T1 end-plates are typical of B fibres. This is clearly not the case because in both PDQ and PB the proportion of T1 end-plates is far greater than that of the B fibres.

Of the 100 muscle fibres examined in PDQ, one had low P'ase activity but had high ATPase and SDH activities. Engel et al. (1965) have shown that there is a decline in the activity of P'ase in denervated muscle fibres. It is therefore possible that this fibre was denervated. According to the morphological observations, 1% of all end-plates in this muscle are in the late phase of degeneration (Table 4), so there appears

FIGURE 14. Histogram of the diameters of muscle fibres of different histochemical types

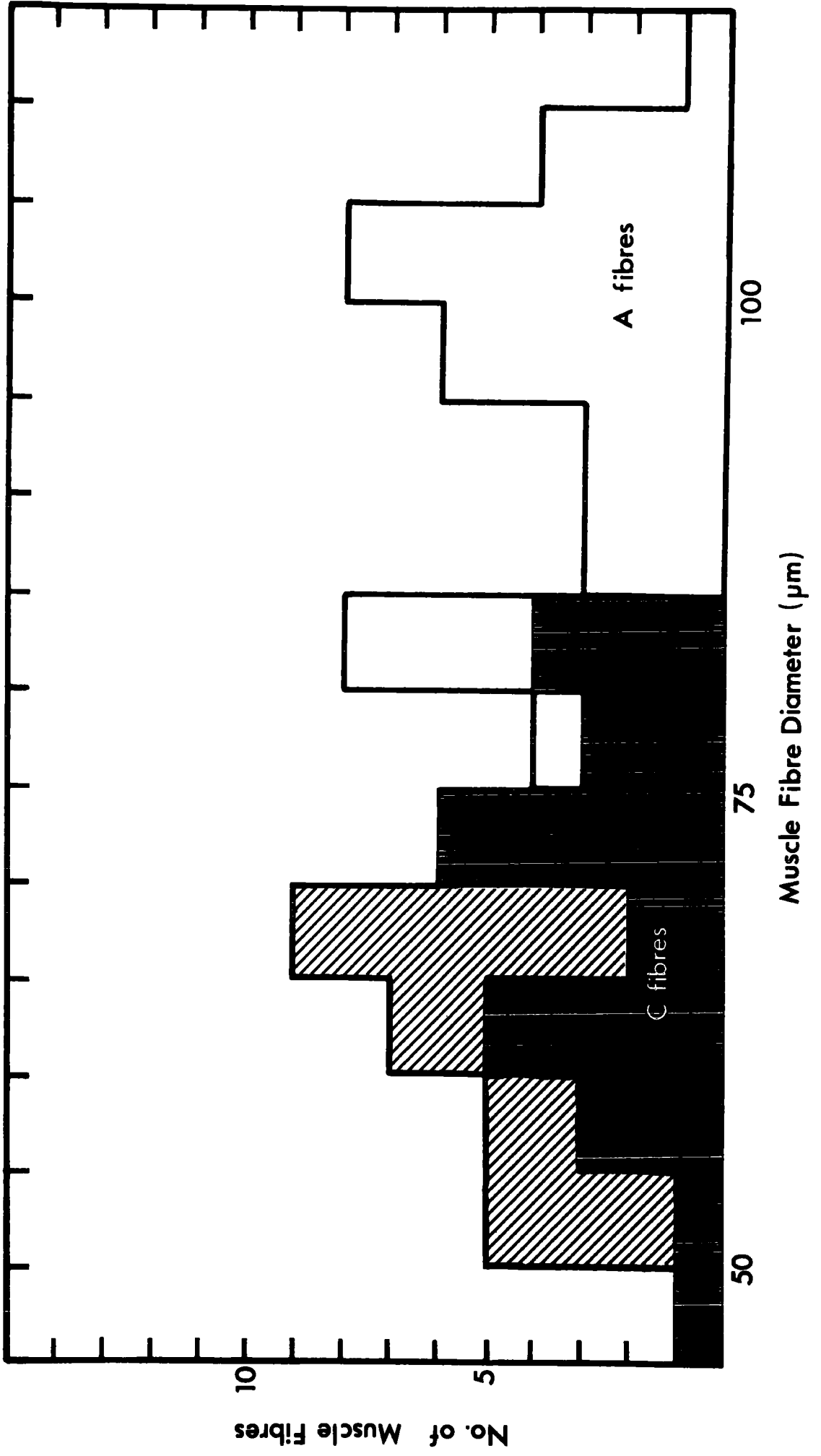
The muscle fibre diameters were measured in sections of a PDQ muscle of a young adult cat, after staining for ATPase. The number of A (unshaded columns), B (shaded columns) and C (solid columns) fibres measured were 30, 15 and 25, respectively. The mean diameters were :-

A fibres, $96.8\mu\text{m}$ (S.E. 1.59);

B fibres, $61.3\mu\text{m}$ (S.E. 1.59);

C fibres, $71.5\mu\text{m}$ (S.E. 2.60).

The mean diameter of 51 fibres measured at random was $84.5\mu\text{m}$ (S.E. 2.30). All four populations were normally distributed and there is a considerable degree of overlap between the three fibre types.



to be a good correlation. However, this finding must be treated with caution because of the low incidence of such fibres.

8.3 Muscle fibre size and histochemical type

When the muscle fibre size was assessed on a three point semi-quantitative scale for each type of muscle fibre in the peroneal muscles, 88% of the large diameter fibres were type A, and the remainder were type C. The medium diameter fibres were almost evenly divided between type A and type C. About 50% of the small fibres were type C, 40% type B (95% of type B fibres were of small diameter) and the remaining 10% were type A. Thus, it is apparent that on this semi-quantitative basis size is at best only a crude guide to fibre type, since only the large fibres can be assigned to a type group with a reasonable degree of certainty.

The mean diameter measured in ATPase preparations for A, B, and C fibres were $96.8\mu\text{m}$ (S.E. 1.59, $n = 30$), $61.3\mu\text{m}$ (S.E. 1.59, $n = 15$) and $69.1\mu\text{m}$ (S.E. 2.04, $n = 25$), respectively. Each of these values was significantly different from the others. However, when the muscle fibre diameters are plotted as a histogram (Fig.14), it can be seen that there is a considerable overlap between the diameter ranges of B and C fibres and that only fibres greater than $85\mu\text{m}$ can be reliably classified as A fibres. The distribution of the muscle fibre diameters of each type was normal. When 51 of these fibres selected for measurement without regard to their histochemical type were considered, the distribution of the muscle fibre diameters of this 'random' population was also normal (mean $84.5\mu\text{m}$, S.E. 2.3).

A comparison of the mean muscle fibre diameters from silver impregnated and frozen sectioned muscles (Figs. 10 and 14, respectively) reveals that silver impregnation causes a shrinkage of about 30%. Therefore the diameter alone cannot be used as a valid comparison between these muscles. However, from the data on histochemical types and muscle fibre diameter it may be said that the top 20% of muscle fibres by diameter can be classified as type A, with reasonable certainty. When the 35 end-plates of this group of muscle fibres in young adult PDQ muscles are examined, every morphological type is represented. Consequently, end-plate type is not related to the histochemical type of the muscle fibre.

8.4 Combined cholinesterase and succinic dehydrogenase staining

Several of the earlier studies relating variations in end-plate size and morphology to muscle function made use of staining techniques for cholinesterase activity (e.g. Gerebtzoff et al., 1954; Coers, 1955; Nystrom, 1968a). Ogata (1965) stained frozen sections of mouse muscles for both cholinesterase (ChE) and succinic dehydrogenase activity and found that the subneural apparatuses (SNA) of pale-staining muscle fibres were large with a 'complicated interlacing structure' (p.150). The SNA of the darkest fibres were small, simple and compact, while those of the intermediate fibres had a size and structure intermediate between these two extremes.

It has been demonstrated that the AChE of motor end-plates is localized in the primary and secondary synaptic clefts (Teravainen, 1967). Thus, it is possible to relate

observations made using light microscopy and ChE staining to ultrastructural studies such as those of Padykula & Gauthier (1970) who demonstrated differences in the elaboration of the synaptic clefts of end-plates on the three structural types of muscle fibre in rat diaphragm.

The results of the preceding sections concerned with the histochemistry of muscle fibres showed that in the cat PDQ the intensity of SDH activity alone was only a rough indication of muscle fibre type. Thus, all A fibres had low SDH activity, approximately 75% of B fibres had a high SDH activity, and 64% of C fibres were of intermediate activity while the remaining 36% were of high activity. With this proviso in mind, a study of the size and structure of SNA of the end-plates of whole muscle fibres stained for SDH activity according to the method of Barker et al. (1970) was undertaken. Examples of muscle fibres and SNA prepared in this way are illustrated in Plate VIIIi - 1.

Three types of muscle fibre of high, intermediate and low SDH activity were discernible (Plate VIIIi) and in general the findings of Ogata (1965) described above were confirmed. The SNA of the low activity (A) fibres were the most complex, having a network of gutters (Plate VIIIj - 1). The SNA of the high activity (B) fibres were simpler in structure, having a compact appearance with a much more even distribution of the reaction product and lacking the open network type of configuration (Plate VIII 1). The muscle fibres of intermediate SDH activity (C fibres) bore SNA with a less compact structure than those of the B fibres, but they were clearly less

divided than those of the A fibres (Plate VIIIk). No SNA of a lobed form which could be related to T2 or T3 end-plates were encountered. A particular effort was made to find configurations of SNA which might indicate growth, such as smaller patches of AChE activity close to the parent ending (cf. Kupfer, 1960), but no such configurations were found.

These observations can be related to the arrangement of the synaptic clefts of the end-plates of different fibre types (Padykula & Gauthier, 1970). Thus, the 'white fibres' (A fibres of this study) have long, branching, closely spaced, secondary synaptic clefts, while those of 'red' B fibres have the least area of contact with 'relatively shallow sparse' secondary clefts. The end-plates of 'intermediate' (C) fibres have the 'most widely spaced and deepest' secondary clefts. Some of these observations have been quantified by Duchon (1971a).

The ultrastructure of end-plates was not examined in detail in the present study, but the observations did show that the secondary synaptic clefts varied as described by Padykula & Gauthier (1970) and Duchon (1971a). Electron micrographs of motor end-plates are illustrated in Plate XV.

8.41 Measurements. The mean end-plate diameters (μm) for muscle fibres of high, intermediate and low SDH activity were : 29.5 (S.E. 0.62), 25.2 (S.E. 0.84) and 20.9 (S.E. 0.66), respectively. The number of end-plates measured was 50 in each case. Each of these mean diameters was significantly different from the others ($P < 0.001$), but there is a large amount of overlap in the distributions (Fig.14). Only in the case of the low activity fibres was the correlation between the end-

plate and muscle fibre diameters not statistically significant. Taken as a whole, the correlation between these two parameters was highly significant ($P < 0.001$) and both were normally distributed (Fig. 15).

It is of interest to compare these results with those obtained in silver-impregnated muscles (Table 4). It may be assumed that any shrinkage effects which occur during fixation are confined to the muscle fibres and do not greatly affect the end-plates.

The mean diameter of the 150 SNA measured in the AChE stained PDQ was $25.2\mu\text{m}$ (S.E. 0.50), significantly lower than the corresponding value of $28.7\mu\text{m}$ (S.E. 0.49) in silver preparations ($P < 0.01$). The mean axial ratio of 1.00 (S.E. 0.032) of the SNA was significantly reduced ($P < 0.001$) compared to the value of 1.36 (S.E. 0.065) in silver preparations. Both these reductions may be interpreted as reflecting the greater precision with which the junctional area is defined by the SNA, as opposed to the extent of the axon terminals. That they are not merely due to individual variation or to different degrees of shrinkage is indicated by the fact that in the AChE-stained muscle the mean muscle fibre diameter is significantly greater ($P < 0.001$) than in the silver-impregnated material.

The mean diameters (μm) of muscle fibres of high, intermediate and low activity were : 56.1 (S.E. 1.53), 66.2 (S.E. 2.15) and 62.6 (S.E. 1.28), respectively. The values for each of the three fibre types were normally distributed, as were the values for the population as a whole. Although each of the values is significantly different from the others, there is a considerable degree of overlap in the ranges

so that no single type can be separated on the basis of diameter (Fig.16). A comparison of these values with those previously given (Results 8.3) for A, B and C fibres shows a good correspondence between those of B and C fibres with those of high and intermediate activity, respectively. However, the mean diameter of low activity fibres is much lower than that of the A fibres measured in frozen sections ($96.8\mu\text{m}$). Further, the mean diameter of the low activity fibres is less than that of the intermediate fibres in contradistinction to the ranking of A and C fibres. These discrepancies must be attributed in part at least to the unreliability of typing muscle fibres on the basis of a single enzyme reaction. Thus, as demonstrated by the results of the more detailed study of the histochemistry of muscle fibres, there will inevitably be some overlap between B and C fibres when the classification is based solely on SDH activity.

8.5 Conclusions

The frequencies of the three histochemical types of muscle fibre present in peroneal muscles cannot be related to the frequency of any morphological type of motor end-plate, or to growth. It is possible that the few muscle fibres with a low P'ase activity and a high ATPase activity may be a concomitant of degeneration. The size and more particularly the structure of the SNA is related to the intensity of SDH activity of muscle fibres. The measurements of muscle fibres of known histochemical type demonstrate that the muscle fibre diameter is not a reliable criterion of histochemical type.

Thus, the variations in the morphology of the motor end-plates seen in teased, silver preparations cannot be ascribed to variations in the nature of the muscle fibres.

FIGURE 15. Histograms of the diameters of SNA of a PDQ muscle of a young adult cat (C295)

The SNA were measured in a muscle stained for the activities of acetylcholinesterase and succinic dehydrogenase. The populations for each type of muscle fibre (light, intermediate and dark) are shown separately. The number of SNA measured (n), the mean and the standard error of the mean are shown in each case.

The distribution of the SNA of the darkly-staining fibres shows a slight degree of kurtosis ($g_1 = 1.32, P < 0.05$). The other three distributions are normal. There is a considerable overlap of the sub-populations.

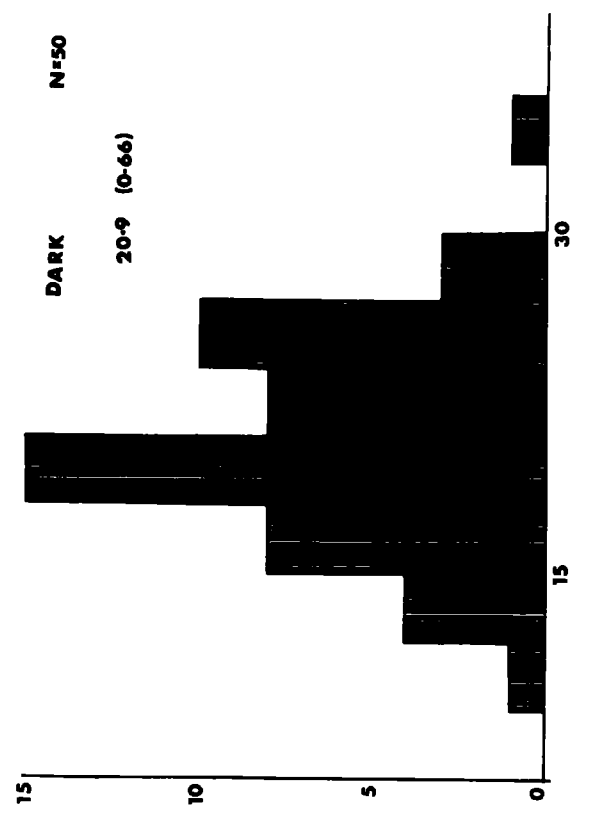



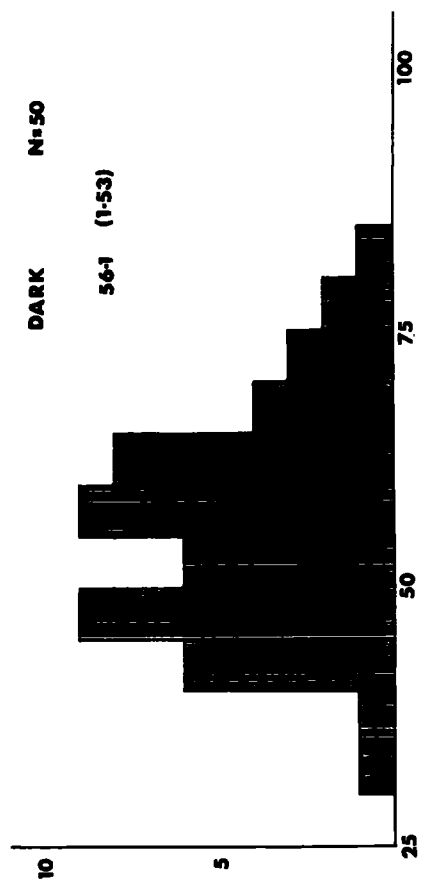
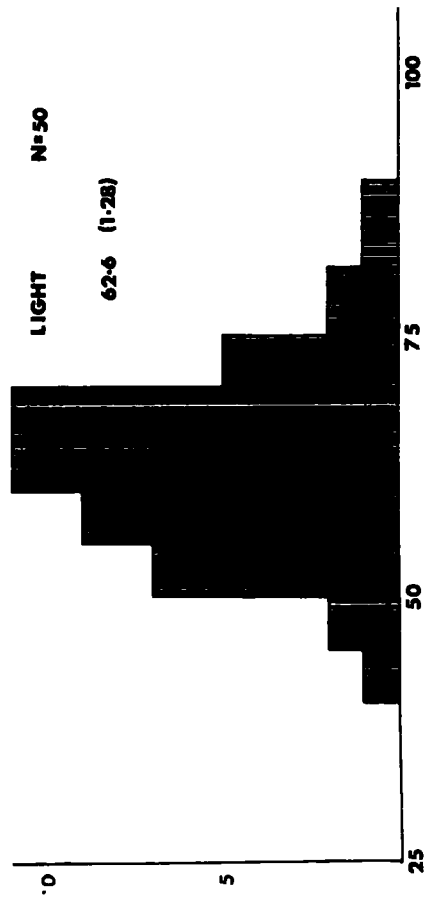




FIGURE 16. Histograms of the muscle fibre diameters of the PDQ muscle
of a young adult cat (C295)

The muscle fibres measured correspond to the SNA of Fig.15. The populations are shown separately, and the number of fibres measured (n), the mean and the standard error of the mean are shown in each case.

All four distributions are normal. There is considerable overlap between each of the sub-populations, so that the muscle fibre diameter is not clearly related to enzyme activity.



DISCUSSION

The discussion of the observations presented above is divided into five main categories. Firstly, consideration will be given to the possibility of artefacts distorting the observations. Secondly, the morphological results will be compared with those of other relevant studies. Then the relationship of the present observations to the principal views of the nature of the variations in the form of motor end-plates will be examined. The changes found in ageing will be the subject of a separate section, preceding an analysis of the hypothesis of end-plate elaboration, outlined above (Fig. 19). Whenever possible, the morphological data of the present study will be integrated with those of physiological investigations.

1. Validity of the observations on end-plate morphology

In a morphological study based almost exclusively upon a single staining method, it is important to consider what proportion of the observations might be due solely to distortion of the tissue during preparation. In the present case, only the more subtle and delicate configurations, such as non-myelinated outgrowths of the terminal axon, axonic swellings and the swelling and retraction of the axon terminals, are likely to be considered as artefacts.

The attempt to minimize errors due to any deficiencies of impregnation by rigorous selection of well-stained areas and the replication of examinations has been described in the Methods.

However, other factors combine to demonstrate the validity of the observations. Thus, end-plates showing growth or degeneration are scattered throughout the muscle and occur in terminal sprays containing normal, simple end-plates (Plates IVg - h, VI f). This militates against the possibility that these configurations could be due to some peculiarity of the staining technique, such as differential rates of penetration of reagents during processing.

Further, the variations between animals and muscles are consistent, so that the end-plates of PDQ muscles of different young adult cats are similar in all respects and, conversely, the end-plates of a soleus muscle differ markedly from those of PDQ of the same limb. The changes occurring with ageing show the same kind of consistency, and many of them have been observed by other workers using both silver and methylene blue techniques on rat and human muscles (Gutmann & Hanzlikova, 1965; Harriman et al., 1970). Moreover, the methylene blue and gold chloride techniques show the same types of configuration as those seen in silver-impregnated muscles, albeit with less clarity and precision.

Finally, the fact that the study of denervated muscles revealed many end-plates of a normal form as well as the increasing proportion of degenerating endings (Table 2), also tends to demonstrate that such forms are not due to some failing of the staining technique.

For these reasons, it must be assumed that the observed configurations are not artefacts, but represent

structures which are present in life. The fact that growth and degeneration could not be identified in the electron microscope study may have been due to sampling difficulties.

The possibility of distortion due to confusions in terminology is inherent in any description and, in order to minimize this, the terms used were carefully defined and frequent checks were made to ensure consistency in their use. The segregation of end-plates into 'types' is a 'natural' classification in that it is a reflection of the observed forms, i.e. it was conceived as a result of observation and not a priori.

Attempts were also made to eliminate errors due to unconscious selection on the part of the observer by using clarity as the primary criterion for the inclusion of a configuration in a given sample of observations. These attempts have been described in detail for each particular set of observations at the appropriate places in the Methods.

2. Earlier studies

The present study has amply confirmed Barker & Ip's (1965, 1966) finding that motor end-plates undergo both growth and degeneration in normal mammalian muscles. In the following sections, the results of a survey of many earlier investigations of the morphology of normal mammalian motor end-plates will be presented, with the aim of establishing the generality of the results reported above. Only end-plates from the limb muscles of mature mammals were included in the survey, although many endings resembling complex endings and growth configurations occur in other mammalian muscles (e.g. Krause, 1863; Kuhne, 1887; Boeke, 1911). The classification of end-plates is based upon the authors' photographs and drawings, rather than on their descriptions, because of the imprecise way in which descriptive terms have been used.

2.1 Complex motor end-plates

End-plates of the T2 form have been found in almost every mammalian muscle examined. Thus, Cole (1955) illustrates such forms in gold-impregnated preparations of muscles of the rat, rabbit, rhesus monkey, kangaroo rat (Dipodomys) and the cat. Other workers have also published photographs of T2 endings in various muscles of the rat (e.g. Carey, Downer, Toomey & Haushalter, 1946; Edds, 1950), man (Coers & Woolf, 1959, Fig. 30; Reske-Nielsen, Harmsen & Hojgaard, 1969, Fig. 9A - B), rabbit (Kuhne, 1887, Fig. 235) and the cat (Kuhne, 1887, Fig. 319; Wilkinson, 1929, Fig. 39; Nystrom, 1968b, Figs. 2, 3, 9, 12).

Examples of the more complex types of end-plate are rare, as might be expected if their low frequency, reported above (Tables 3 and 4), is general in mammalian muscles. However, there are a few references to 'multiple' forms and some clear illustrations of T3 endings (Cole, 1955, Fig. 66 - rabbit; Carey et al., 1946, Fig. 1 - rat; Reske-Nielsen et al., 1970, Fig. 8A - man). There are no unequivocal illustrations of such endings in cat muscles, but some published figures closely resemble them (Cole, 1955, Fig. 77).

None of the workers cited above seems to have attached any significance to complex end-plates and, indeed, only Wilkinson (1929) appears to have clearly recognized them as a distinct form of the ending. Nystrom (1967b) does not remark on them at all, while Carey et al. (1946), Cole (1955) and Edds (1950) do not distinguish between collateral branching, branching of the terminal axon or bifurcation of the preterminal region.

2.2 Growth configurations

Wilkinson (1929) appears to have been the only worker to recognize growth configurations as discrete structural entities, and he clearly distinguishes between ultraterminal and nodal outgrowths, and between myelinated and non-myelinated processes (loc. cit., p. 775). He apparently observed nodal outgrowths in muscles from various mammals including the cat (loc. cit., Fig. 39). Kuhne (1997) also shows a clear example of a T2 ending receiving a contribution in a cat muscle (loc. cit., Fig. 319). Nystrom (1968b) does not seem to have recognized any growth configurations in his examination of cat muscles.

However, the soleus end-plate shown in his Fig. 8 apparently receives a contribution, and Kruger (1960), using silver-impregnated sections, clearly distinguished growth configurations in muscles of the cat (loc. cit., Fig. 10) and other mammals.

2.3 Degeneration

The discrimination of degenerating forms of the motor end-plate in the photographs and drawings of other workers is difficult and uncertain, particularly when the staining technique and the species used are not familiar. Moreover, it is highly probable that degenerating end-plates will not be selected for illustration precisely because of their 'abnormal' appearance. However, that said, there are a few examples of retracted and swollen end-plates, resembling those seen after nerve section.

Thus, Cole (1957), in a study of 24,500 endings from gold-impregnated muscles of the rat, shows 'an unusual type of motor ending' which has the retracted appearance typical of the early phase of degeneration (loc. cit., Fig. 19). In the photographs of Carey and his associates there are more examples of such forms, possibly because they were concerned to show that there are 'retracted' and 'expanded' forms of the motor end-plate (e.g. Carey, 1941, Figs. 7 - 10). End-plates seen in methylene blue preparations of human muscles occasionally have swollen terminal expansions and such endings bear quite a close resemblance to degenerating endings (Reske-Nielsen et al., 1970, Fig. 4).

2.4 Conclusions

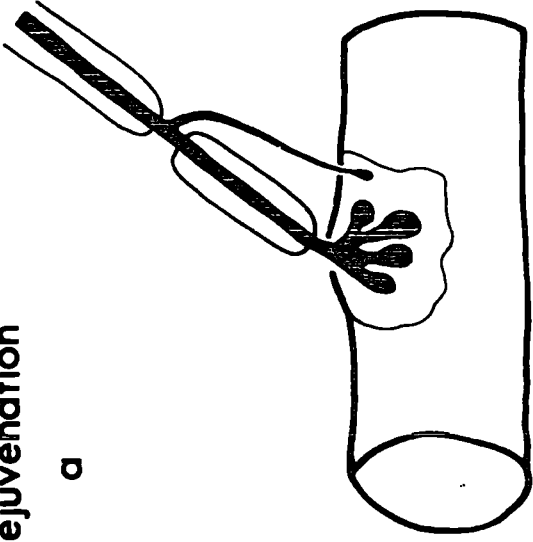
It is clear that complex end-plates have been repeatedly observed in a large number of mammalian species. The fact that examples of growth configurations are much rarer may be explained by the predeliction of the earlier workers for the less precise gold chloride staining techniques. Certainly, later workers using the much-improved methylene blue methods and impregnation with silver appear to find growth configuration much more readily. In spite of the probable selection against degenerating forms of the motor end-plate, it is possible to find examples resembling those seen in normal and denervated muscles of the cat.

In short, the observations of Barker & Ip (1965, 1966) and the present study on the nature of the morphological variations of end-plates are supported by those of other workers using different staining techniques on a variety of mammalian limb muscles.

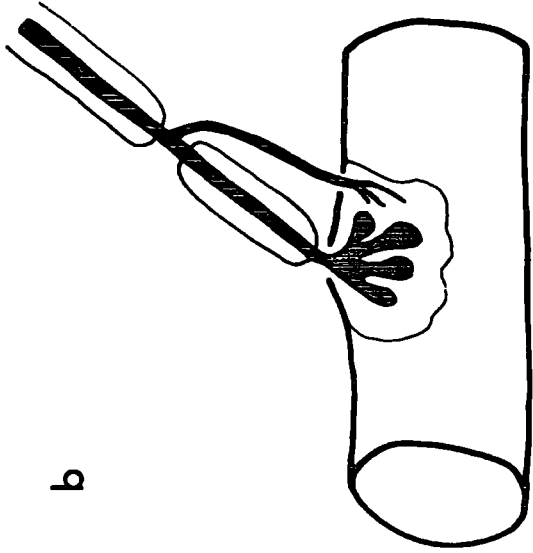
FIGURE 17. Two possible modes of end-plate replacement
(Barker & Ip, 1965, 1966)

- a - c) Rejuvenation. In Fig. a a nodal sprout grows towards the sole-plate of the parent ending and (Fig. b) forms axon terminals. Finally (Fig. c) the parent ending degenerates.
- d - f) Substitution. A new end-plate is substituted for the original one by a similar process, except that it results in the formation of a new sole-plate alongside the old one.

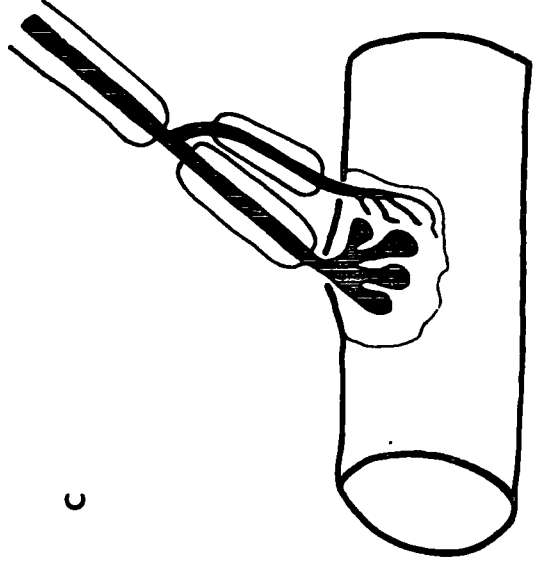
Rejuvenation



a

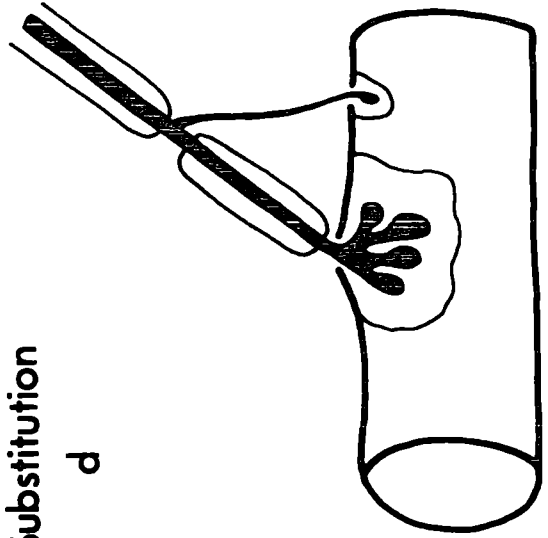


b

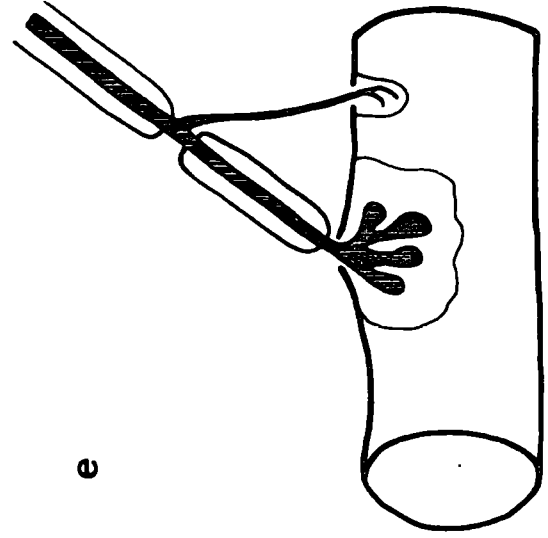


c

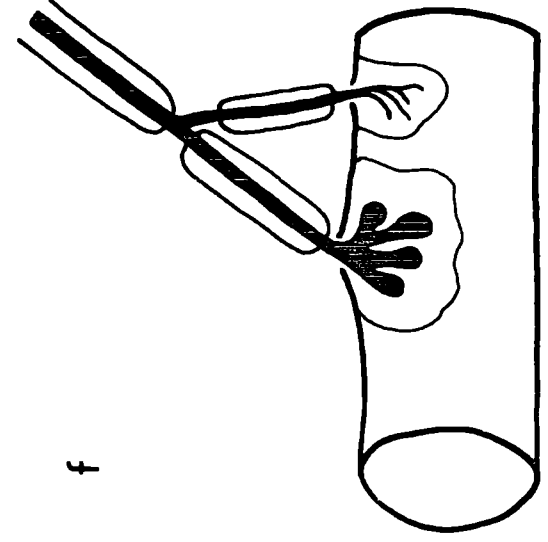
Substitution



d



e



f

3. The nature of variations of end-plate morphology

Three general types of hypothesis have been propounded to account for the observed variability in the form of motor end-plates. The 'replacement' hypothesis of Barker & Ip (1965, 1966) views their growth and degeneration as part of a normal cyclic process of degeneration and renewal. Other workers have suggested that the morphology of end-plates is related to the histochemical type of the muscle fibre (Ogata, 1965; Padykula & Gauthier, 1970) or to the contraction characteristics of the muscle as a whole (e.g. Gerebtzoff et al., 1954 ; Nystrom, 1968a). Finally, there is the concept, put forward by Carey and his co-workers in a series of papers from 1941 to 1948, that end-plates alter their form according to their physiological activity.

Each of these possible explanations will be examined and, since the 'replacement' hypothesis is the only one which takes account of the growth and degeneration of end-plates, it will be discussed first and in greater detail than the alternatives.

3.1 The 'replacement' hypothesis

Sprouting and degeneration of terminal axons and end-plates has long been known in experimental and pathological conditions, but it was not until the work of Barker & Ip (1965, 1966) that both of these phenomena were recognized in normal mammalian muscles. Barker & Ip postulated a causal relationship

between the degeneration of end-plates and the formation of sprouts by the terminal axon. Thus, end-plates were considered to have a 'limited life-span' at the end of which they degenerate and are replaced. The relationship of the observations of the present study to this concept has been briefly discussed elsewhere (Results, 4); it will now be examined in detail with reference to each of the possible modes of 'replacement' proposed by Barker & Ip (1966), see Fig. 17).

3.11 Rejuvenation. Barker & Ip (1966) suggested that 'a sole-plate may receive a new ending from a sprout derived from the same terminal axon as the old ending, which degenerates.' (p. 551). This process is illustrated in Fig. 17a - c and described in the terms used in this account in the legend. It was Barker & Ip's 'impression' that sole-plates were 'more often 'rejuvenated' than abandoned.' (loc. cit., p. 549).

In the present study many examples of the type of configuration shown in Fig. 17a and b were encountered (e.g. Plates VI - VII), but the incidence of degenerating end-plates receiving sprouts or contributions was much lower than would be expected if rejuvenation were the principal means of end-plate replacement. In that event, at least a large majority of degenerating end-plates would receive a growth configuration. In fact, the greatest proportion observed was 30% (young adult PDQ) and was only about 10% in the other muscles examined. Moreover, in every case where a contribution was associated with a degenerating end-plate, it too was affected by the degeneration process (it is, of course, impossible to tell

whether a sprout is degenerating). Hence, the conclusion that the observed configurations do not support the existence of rejuvenation is inescapable.

3.12 Substitution. Besides rejuvenating an old sole-plate, 'a sprout may establish a new plate alongside the old plate belonging to the same terminal branch' (Barker & Ip, 1966, p. 551). This process may be described as the 'substitution' of a new end-plate for an old one on the same muscle fibre and the necessary stages are shown diagrammatically in Fig. 17d - f.

It has been repeatedly emphasized that all the sprouts and contributions ended on the sole-plate of the parent ending. That is, the intermediate forms in the process of substitution (Fig. 17b - f) were never encountered.

The final stage of this process (Fig. 17f) is not unlike the duplex form of the end-plate (Fig. 2d). However, only one such end-plate was observed in young adult PDQ muscles, and none at all in those included in the detailed survey of end-plate morphology. So, as with rejuvenation, the configurations seen in normal muscles do support the existence of end-plate replacement by this mode.

3.13 Collateral sprouting. Thus, it has been demonstrated that end-plates are not replaced by outgrowths from the parent axon. The alternative is for them to be replaced by outgrowths from an adjacent intact axon or its ending. Barker & Ip (1965, 1966) have pointed out the similarity of this mode to that of collateral regeneration,

the means by which the residual axons in a partially denervated muscle make new connexions with denervated sole-plates (for reviews see Edds, 1953; Wohlfart, 1958). For the sake of comparison, the events occurring in collateral regeneration are illustrated diagrammatically in Fig. 18.

However, in all the cases in which terminal axons supplied end-plates to more than one muscle fibre, all the endings were well-formed and could not be considered as young end-plates. Moreover, in some cases, both end-plates derived from the same parent axon were of a complex form (Plate IIIb; see also Tuffery, 1971, Fig. 10). The only possible exceptions to this might be those collateral end-plates formed by several non-myelinated outgrowths from a node (Plate VIIIc and Fig. 8a), but such cases constituted less than 1% of all endings examined.

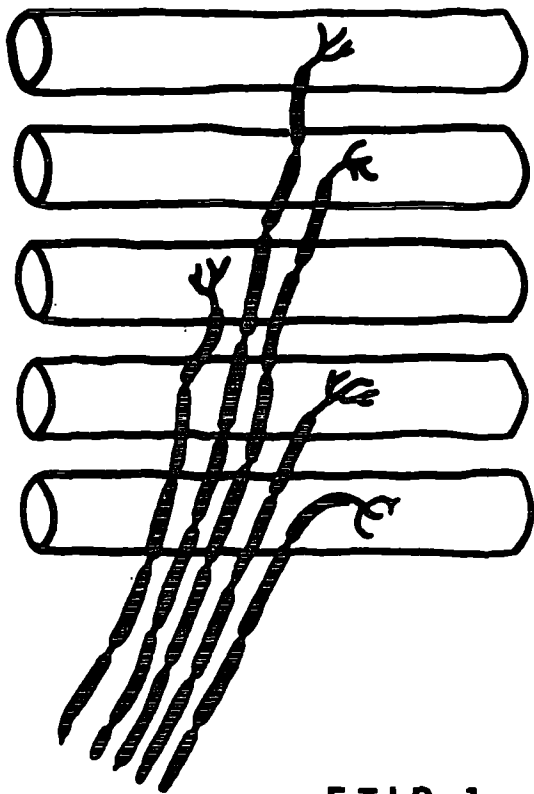
The most critical configurations for the demonstration of collateral re-innervation of degenerating end-plates or denervated sole-plates would be those in which sprouts pass to a muscle fibre other than the one bearing the parent ending (cf. Fig. 18c). Only one such case was seen and the sprout did not appear to make a functional contact with the muscle fibre (Fig. 8e), and is therefore regarded as an example of the 'spurious' sprouting seen in muscles from ageing animals (infra, 4.1).

The examination of the terminal innervation of ageing cats provided the key piece of evidence concerning the existence of collateral sprouting in normal muscles. Clearly, if it did occur, then the F.T.I.R. would be elevated as it is after collateral regeneration in partially denervated muscles (Edds, 1950; Wohlfart, 1958; see Fig. 2). Since the F.T.I.R. is plainly not elevated (Tables 3 - 4), it seems highly improbable that collateral sprouting occurs.

FIGURE 18. Schematic representation of collateral regeneration

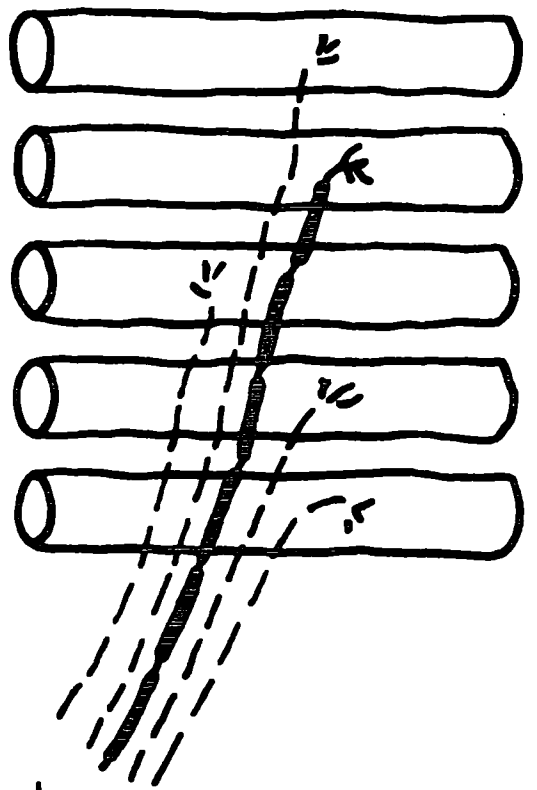
(Redrawn from Coers & Woolf, 1959)

- a) The normal pattern of innervation with each terminal axon forming one end-plate. This results in a ratio of muscle fibres to terminal axons (Functional Terminal Innervation Ratio or F.T.I.R.) of unity.
- b) In partial denervation many of the end-plates and their terminal axons degenerate (broken lines).
- c) The surviving end-plates and terminal axons form numerous fine outgrowths (sprouts).
- d) The sprouts establish contact with the denervated sole-plates of the original end-plates (Iwayama, 1969; Lullman-Rauch, 1971). This results in a changed pattern of terminal innervation with an increased F.T.I.R.

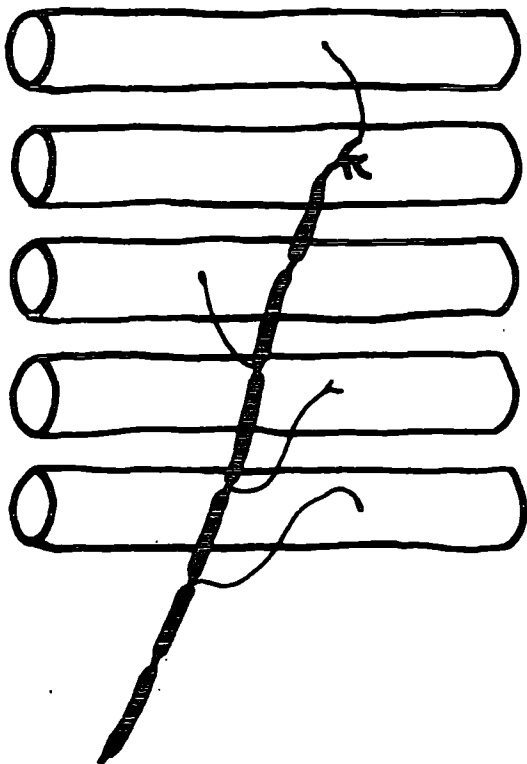


a

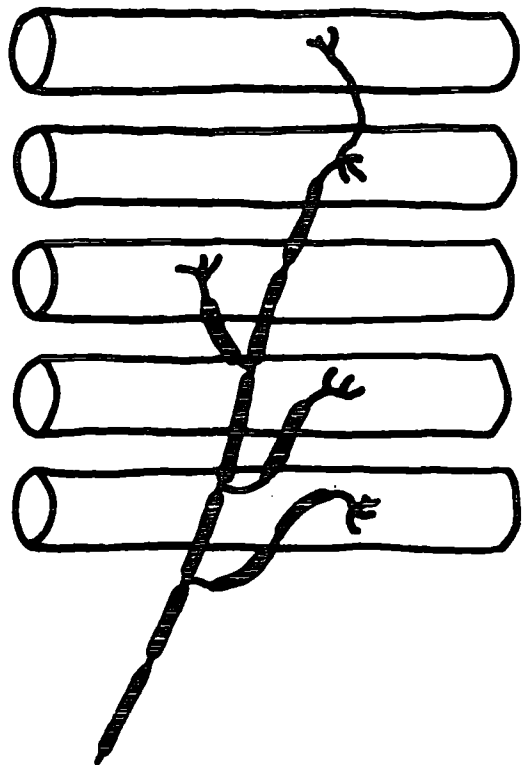
F.T.I.R.=1



b



c



d

F.T.I.R.=5

The possibility that the degeneration of end-plates takes place in such a way that the F.T.I.R. remains constant would seem to be remote since the susceptibility to degeneration and the ability to re-innervate muscle fibres are antagonistic properties (McComas, Sica & Campbell, 1971). Even in this unlikely event, one would expect to find individual axons supplying end-plates more than the two muscle fibres typical in the muscles of young adult animals. But, only two terminal axons supplied end-plates to three muscle fibres, hence the only evidence for the existence of collateral sprouting rests solely on these two cases. Consequently, it cannot be said that this process occurs to a significant extent.

3.14 Conclusions. A detailed examination of the possible modes of 'replacement' of degenerating motor end-plates in the light of the results of the present study shows that the growth configurations observed are inconsistent with these processes. It is suggested that in their original study Barker & Ip (1965, 1966) were not sufficiently quantitative in their approach and were therefore misled as to the significance of those degenerating end-plates receiving growth configurations. Be that as it may, the 'replacement' hypothesis is no longer tenable and it seems that growth and degeneration are not causally related, but that they are two entirely discrete processes. In the ensuing sections other possible explanations of the morphological variation of end-plates will be examined.

3.2 Muscle fibre types

That nerves and muscles are mutually dependent and have a continuing effect upon each other has not been in dispute since the earliest studies of the effects of nerve section. This relationship has been shown by the classical cross-innervation experiments of Buller, Eccles & Eccles (1960) to be extended to the control of the physiological characteristics of the muscle, which are reflected in the histochemical profiles of the muscle fibres (Romanul & van der Meulen, 1967; Yellin, 1967). The means by which this relationship is effected is the subject of much controversy and is outside the scope of this discussion. The pertinent point for the present study is whether the morphology of the end-plates in some way reflects the characteristics of the muscle fibre on which it lies. The main attempts to relate these parameters have been described above (Results, 8) and may be classified into those using the muscle fibre diameter as a criterion of its type and those using the contraction characteristics of the muscle as a whole.

It has been clearly demonstrated that muscle fibre diameter is not a reliable criterion of histochemical type (Fig. 14), and an analysis of diameter measurements of fibres of known histochemical type in various muscles of the cat (Nystrom, 1968c) and rabbit (Baldock, unpublished) confirms this view. Indeed, although the mean diameter of A fibres is always greatest, the relative ranking of B and C fibres is variable in different muscles. The fact that no correlation can be drawn between the incidence of the various morphological

forms of the end-plate and the proportions of the three types of muscle fibre also militates strongly against this type of relationship.

Although it is well-known that soleus is a slow-contracting muscle which is subject to constant excitation, there appear to be no data concerning the physiological characteristics of the peroneal muscles. However, since B fibres probably have the slowest contraction time (Edgerton & Simpson, 1971; Barnard, Edgerton, Furukawa & Peter, 1971), it may be assumed that PB, which has the greater proportion of B fibres, contracts somewhat more slowly than PDQ. In that event, the fact that PDQ has a significantly greater mean end-plate diameter than PB or soleus supports the findings of Gerebtzoff et al., (1954) that fast muscles have larger end-plates.

Gruber (1966) noted that there was a tendency for the mean size of the end-plate to increase relative to that of the muscle fibre as the speed of contraction of the muscle increased. Certainly, the percentage ratios of the three muscles examined in this study are in agreement with this view. However, ultrastructural observations of the differences between end-plates from muscle fibres of different properties make comparisons based on light microscopy seem somewhat academic, since they imply that variations in synaptic surface area may be independent of the end-plate size (Duchen, 1971a).

To sum up, it must be concluded that there is certainly no relation between end-plate morphology and muscle fibre type and no clear-cut relation between the cruder parameter of end-plate size and the contraction characteristics of the muscle as a whole.

3.3 The 'functional state' of the motor end-plate

In a series of papers from 1941 to 1948 Carey and his co-workers reported the results of their examination of thousands of end-plates taken from various normal and experimental muscles. There is considerable difficulty in evaluating both the results and the interpretation of these studies, because, as Tiegs (1953) expressed it, 'the subjective account so obscures the factual that any value they have is largely hidden.' (p. 127). Several other workers have criticized the general lack of statistical treatment of the data in Carey's reports, and particularly the failure to specify the normal range of variation (e.g. Denz, 1951; Harris, 1954; Coers, 1955). However, their view appears to be that end-plates expand and contract according to their activity, or 'functional state', like 'biologic jet-pumps' (Carey, Massopust, Haushalter, Sweeney, Sarabilis & Raggio, 1946, p. 1226), and that their degree of retraction is related to the degree of contraction of the muscle fibre on which they lie.

This view of the end-plate does nothing to explain the complex forms of the end-plate or the presence of growth configurations but it may be relevant to the question of the retracted degenerating endings. However, since all the muscles from young adult cats were removed under deep surgical anaesthesia, it can be assumed that the 'functional states' of all the muscle fibres were similar and cannot therefore be invoked to explain the occurrence of retracted endings.

4. Ageing

The changes occurring with increasing age will be considered under two sub-headings; firstly, the changes in the morphology of the end-plates and, secondly, the loss of muscle fibres.

4.1 End-plate morphology

There appear to have been only three studies of the morphology of motor end-plates in ageing animals. Harriman et al., (1970), after a study of many vitally-stained biopsies of human muscles, concluded that 'axonic swellings, sprouting of subterminal axons and elaboration of the end-plates are all manifestations of ageing of the lower motor neuron' (p. 402). (The term 'elaboration' is used in the same way as in the present account to mean an increase in the proportion of more complex end-plates.)

The two remaining studies are on various muscles of the rat using the cholinesterase reaction, silver-impregnated sections (Gutmann & Hanzlikova, 1965) and the electron microscope (Gutmann, Hanzlikova & Vyskocil, 1971). In the former report many of the changes are strongly reminiscent of those described above (Results, 5). Thus, there is considerable irregularity in the form of the SNA, suggestive of the formation of more complex endings, and there is a tendency for them to become more rounded as shown by the reduced axial ratio in PDQ muscles of the cat (Results, 5.21). In silver-impregnated sections, 'bulbous endings' resembling vesicular axonic swellings were observed. Gutmann &

Hanzlikova (1965) also noted the apparent increase in the numbers of nuclei at the end-plate similar to that described above (Results, 5.12). The ultrastructure of end-plates from ageing rats resembled that seen in the early stages after denervation (Gutmann et al., 1971). This study also demonstrated the irregularities in the synaptic folds which might be expected from the earlier examination of the SNA. A striking 'agglutination' of synaptic vesicles, similar to that seen in the early stages of denervation, was present but no axonal degeneration was seen. Together with the electrophysiological and pharmacological observations from the same study (Gutmann et al., 1971) the observations suggest a slow reduction of the synaptic contact.

Vesicular axonic swellings have been reported on the non-myelinated parts of γ fusimotor fibres in the equatorial region of young adult cat spindles (Barker et al., 1970), as well as in a variety of normal and pathological human limb muscles (Coers & Woolf, 1959). Barker et al. suggested that they might be indicative of abortive growth. This idea is in harmony with the generally bizarre form of the end-plates in older animals and the increased evidence of growth, some of which certainly appears to be abortive (e.g. Fig. 8e). Further, the end-plates of the soleus muscle of the 18 year old cat which was the only animal showing senile wasting had an extremely high proportion (32.6%) of growth configurations (Table 4).

The absence of any evidence of collateral regeneration in the muscles of ageing cats is somewhat puzzling in view of the loss of muscle fibres. Gutmann & Hanzlikova (1965) noted

a spread in the zone of innervation in the soleus muscle of ageing rats, but this could be due to differential growth and atrophy of muscle fibres rather than to the formation of new end-plates. Such a change in the arrangement of end-plates and muscle fibres has been invoked by Sacco, Buchthal & Rosenfalck (1962) to explain the increase in the mean size of motor units after the sixth decade of life in man.

A similar increase in the mean size of motor units in the extensor digitorum brevis (EDB) muscle of older subjects has been observed by Campbell & McComas (1970) who regard collateral regeneration as the most likely explanation. This view is supported by the grouping of muscle fibres of different histochemical types in EDB (Jennekens, Tomlinson & Walton, 1971) as found in re-innervated muscles (Romanul & van der Meulen, 1967; Yellin, 1967). However, Jennekens et al. (1971) raise the possibility that the marked type grouping in EDB may be the result of trauma due to pressure from shoes on the muscle or its nerve. That pressure can cause deleterious changes in the properties of nerve fibres has been shown by Fullerton & Gilliat (1967). Nonetheless, other muscles, less obviously subject to trauma, showed similar, less marked, grouping, and McComas considers that vascular insufficiency may be significant (personal communication).

Thus, the possibility that at least some of the variations in the morphology of motor end-plates may be due to the effects of trauma must be considered, and may be of special importance in older animals which have not been reared under laboratory conditions. However, it seems unlikely that direct injury of the muscle can be an important source of

variation, since end-plates showing evidence of growth or degeneration and complex endings are usually found in terminal sprays containing normal, simple T1 end-plates. The possibility of a more diffuse change in end-plates resulting from nerve trauma or vascular insufficiency cannot be excluded.

4.2 Muscle fibres

The two most striking features of the muscle fibres in ageing animals were the diminution in their numbers and their increased mean diameter. A loss of muscle fibres with ageing has been reported in various limb muscles of the rat on the basis of both histological observations (Yiengst, Barrows & Shock, 1959; Gutmann & Hanzlikova, 1966; Rowe, 1969) and biochemical data (Andrew et al., 1959). A reduction in the numbers of muscle fibres in some human muscles is indicated by the smaller twitch tensions in muscles of older subjects (Campbell & McComas, 1970). The mechanism of this fibre loss is unknown and although early estimations of the numbers of fibres in human ventral roots showed a decline with ageing (Duncan, 1934; Gardner, 1940), a similar study in the cat failed to reveal a statistically significant decrease (Moyer & Kaliszewski, 1958; Moyer, 1959), despite the 'not uncommon' occurrence of degenerating fibres. Gutmann & Hanzlikova (1966) were also unable to show a decline in the number of α nerve fibres in the muscle nerves of senile rats. However, it is clear that the loss of a very small number of motoneurons would suffice to account for the observed degenerating end-plates and the loss of muscle fibre^s, since each may form

over 500 end-plates (McPhedran, Wuerker & Henneman, 1965; Wuerker, McPhedran & Henneman, 1965). It is therefore possible that the variation between individuals in the number of cells or fibres is great enough to mask small decrements.

Even if there is no demonstrable loss of neural elements in ageing, the deleterious changes in the neuromuscular system may be due to the impaired metabolism of the motoneurone, as suggested by Gutmann, Hanzlikova & Jakoubek (1968). A similar concept of 'sick' motoneurons has been proposed by McComas et al. (1971) to explain the underlying mechanism of neuromuscular disease, and has been extended to cover the changes occurring during the ageing process (McComas, personal communication).

Finally, the possibility of some kind of vascular insufficiency must be considered in view of some observations on ageing human subjects. Thus, the blood vessels of peripheral nerves often have thickened walls, occasionally leading to complete occlusion (Cottrell, 1940), while the maximal rate of blood flow is significantly reduced in the foot and the peripheral resistance of the whole limb is significantly increased (Allwood, 1958).

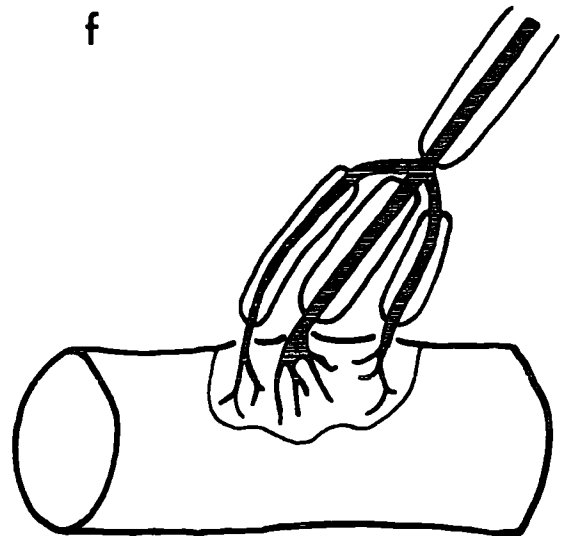
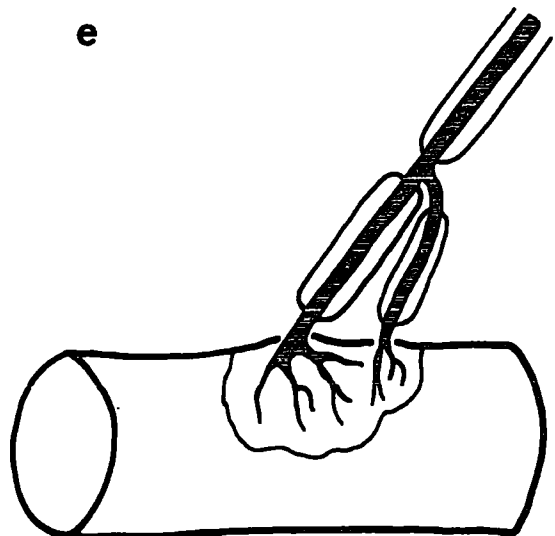
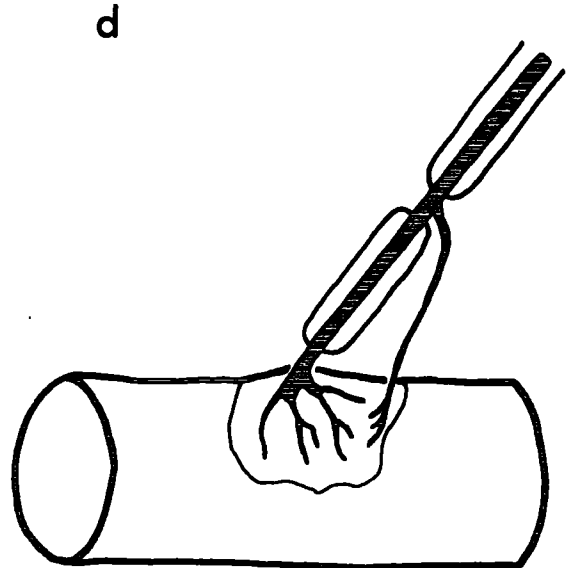
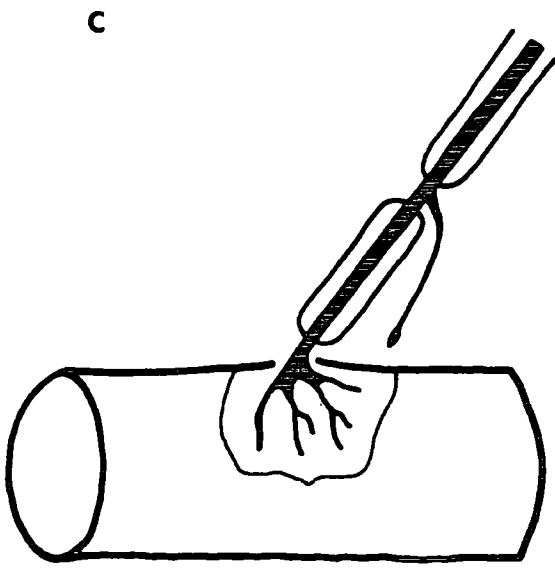
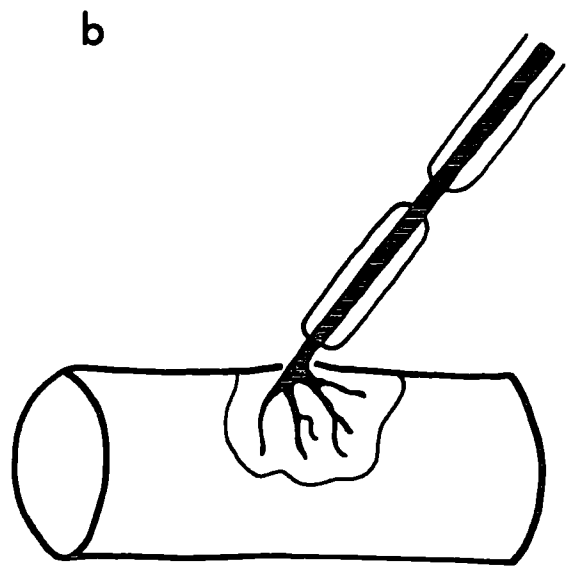
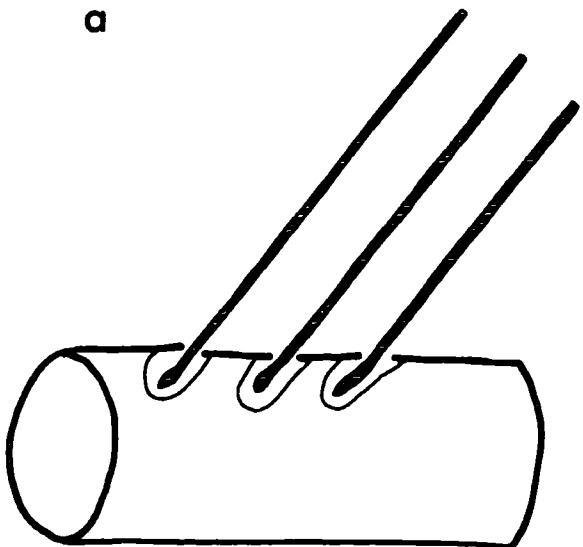
The increased mean muscle fibre diameter in older cats is a slightly unexpected finding, since muscle wasting is a characteristic feature of ageing. Various workers have reported hypertrophied muscle fibres in elderly subjects (Rubinstein, 1960; Serratrice, Roux & Aquaron, 1968; Jennekens et al., 1971) and Rubinstein has suggested that they are compensating for the atrophy and loss of other muscle fibres. Serratrice et al. (1968) also noted the occurrence of fibre splitting which has been associated with increasing functional

demands upon the muscle (van Linge, 1962), but they were unable to exclude an ischaemic factor in their patients.

The increased muscle fibre diameter with a shift to the right of the distribution (Fig. 10) resembles that seen in rat muscles after surgically-induced hypertrophy (Rowe & Goldspink, 1968) and exercise (Goldspink, 1964). This question of increasing functional demands on the muscle will be returned to in the subsequent section.

FIGURE 19. Schema of the hypothesis of end-plate elaboration

- a) Early in development the muscle fibres apparently receive multi-axon terminals (Redfern, 1970; Fidzianska, 1971).
- b) This is subsequently reduced to the adult end-plate, typically of the T1 form.
- c) A sprout grows out from a node towards the parent ending.
- d) The nodal sprout contributes axon terminals to the parent ending.
- e) Subsequent myelination of the contribution leads to the formation of a T2 end-plate.
- f) Further elaboration in this way results in the formation of more complex end-plates.



5. The elaboration hypothesis

The hypothesis that the growth configurations observed in the muscles of young adult cats are successive stages in a process leading to the formation of more complex end-plates has been briefly stated above (Results, 4), and is illustrated diagrammatically in Fig. 19. This concept was formulated to account for all the observations, especially the increased occurrence of complex end-plates in ageing animals and will now be examined in detail.

It has been demonstrated that surgically-induced hypertrophy of the muscle increases the proportions of the more complex forms of the end-plate (Results, 7), and it is suggested that the formation of complex end-plates is a response to the increasing demands made upon the neuromuscular system. In the following paragraphs it will be shown that increasing functional demands are in fact being made throughout the life of the cat.

It is known that the end-plates of immature animals are very small, often consisting of a single axon terminal, and have simple SNA (Coers, 1955; Nystrom, 1968a, b). Subsequently, they assume the more complex adult form with several axon terminals and a sub-divided SNA. It is interesting that end-plates of the T2 form were seen in muscles from kittens of 10 weeks old, about the time that the end-plates are becoming fully differentiated (Nystrom, 1968a, b). Clearly, at the same time there is a considerable increase in the work-load imposed upon both muscle fibres and end-plates as the animal becomes larger and more active. The increase in the area of synaptic

contact by the development of greater numbers of axon terminals can be seen as a response to this increasing load, and the later involvement of the more proximal parts of the terminal axon to form more complex end-plates as an extension of this process.

The presence of T2 end-plates in such young animals indicates that some endings are very sensitive to the increased demands made upon them. Alternatively, some T2 endings may arise due to 'accidents of development' in the same way that the collateral branching of terminal axons does. The presence of an unspecified proportion of complex end-plates early in development in no way undermines the concept of end-plate elaboration, since it rests principally upon the unequivocal increase in the incidence of such forms with increasing age.

The body weights of the 6, 10, 15 and 18 year old cats of the present study were 5.53, 4.40, 2.60 and 2.25kg, respectively. This indicates that it continues to rise throughout adulthood, beyond the normal life span of 10 years, after which senile wasting occurs. Similar observations on the rat have been recorded (Rowe, 1969). An increasing body weight will impose a greater functional load upon the neuromuscular system and may be to some extent independent of the activity of the animal.

The response of muscle fibres to an increased workload is an increase in the amount of contractile substance, resulting in a greater mean fibre diameter and an increased muscle weight. The fact that the distribution of the muscle fibre diameters changes in a manner analogous to that seen after hypertrophy has been discussed earlier and supports


the idea of a continuously increasing work-load. Further support can be adduced from the highly significant correlation between muscle weight and body weight over the complete range of ages examined (Fig. 20). Moreover, if the frequencies of growth configurations and complex end-plates in soleus muscles are reviewed from this standpoint, there is a good correlation with body weight, assuming that senile wasting has occurred in the 18 year old animal (Table 4).

As a postscript to the elaboration hypothesis, it should be added that the 'turnover' of individual axon terminals cannot be excluded despite the failure to find degenerating forms in the ultrastructural part of this study. Indeed, growth of individual axon terminals is given circumstantial support by the occasional occurrence of dense core vesicles, which have been implicated in the growth and regeneration of nerve fibres (Lullman-Rauch, 1971; Duchon, 1971b).

5.1 A possible cause of elaboration

Accepting that end-plates become more elaborate as a response to increasing demands upon the neuromuscular system, it is possible to speculate about the causes of the process.

When a muscle fibre and its end-plate are called upon to be more active than before (i.e. when the frequency of excitation is greater or more prolonged), a condition resembling a partial block of transmission may obtain. Thus, in a state of partial block, the rate of stimulation remains constant while the functional synaptic area is



effectively reduced, but, in normal muscles, if the rate of stimulation is increased, the existing synaptic area may be inadequate, resulting in an analogous situation.

Now, a striking feature of end-plates whose transmission has been blocked by toxins is an extensive sprouting of the terminal axons (Duchen & Strich, 1968; Duchen, 1971b; Duchen, Stolkin & Tonge, 1972). Hence, it may be inferred that elaboration is a much more limited version of the same process, resulting in a higher density of axon terminals for the same, or a slightly enlarged, total end-plate area. This increased density of axon terminals would result in an increase in the functional synaptic surface area of the end-plate, thus overcoming the partial block.

It is conceivable that the addition of a non-myelinated contribution may be sufficient to cope with a small functional deficit by conducting some, but not all, of the impulses from the parent nerve fibre (cf. Morris & Woolf, 1970), hence some contributions may be semi-permanent. However, a further increase would require improved conduction properties and myelination would occur.

In truly senile animals, where there is a decline in the demands made upon the neuromuscular system, growth may still occur as a response to impaired neuromuscular transmission caused by the deleterious changes in the ultrastructure of the end-plate (Gutmann et al., 1971) or in the neurone itself (Gutmann et al., 1968). Again, the apparently abortive sprouting seen in the muscles of ageing cats is reminiscent of that seen after blocking neuromuscular transmission.

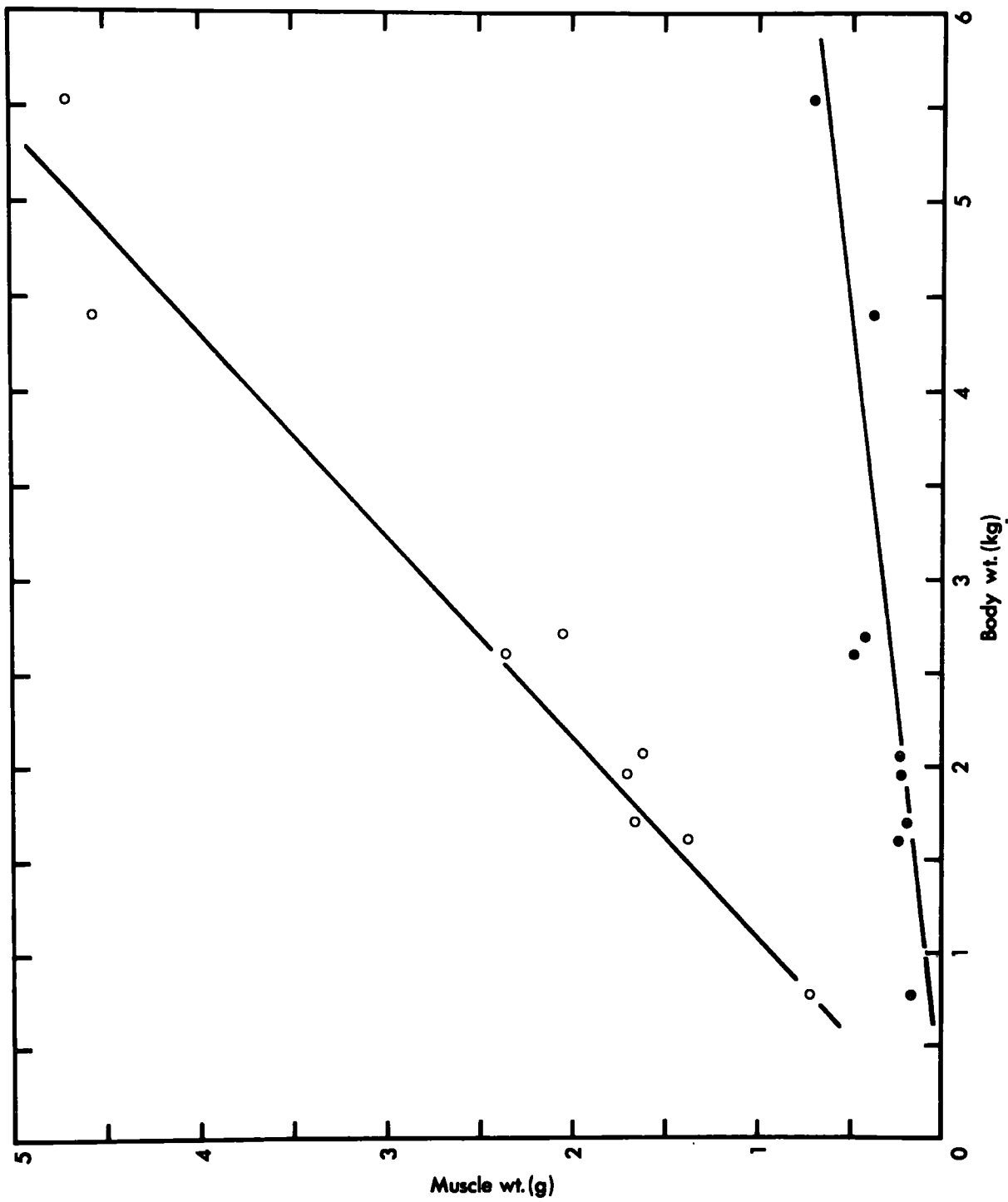
FIGURE 20. Graph of the weights of PDQ and soleus muscles against body weight

The mean weights (g) of both PDQ (filled circles) and soleus (open circles) muscles of each of nine cats aged 15 days to 19 years are plotted against the body weights (kg). The correlations for both muscles with body weight are highly significant :-

$$\text{PDQ, } r = 0.80, P < 0.001, y = 0.13x - 0.05;$$

$$\text{soleus, } r = 0.84, P < 0.001, y = 0.97x - 0.25$$

The same relationship exists for other hindlimb muscles not shown in the figure.



6. Concluding remarks

There are two aspects of wider interest which may be noted at this juncture. Firstly, the development of a descriptive nomenclature has made it possible to quantify in considerable detail the morphology of motor end-plates. From this quantification have emerged clear differences in the morphology of end-plates from different muscles. Such differences make it essential that all future studies of the effects of experimental or pathological conditions on the morphology of the terminal innervation should include an analysis of the range of variation in the normal muscle.

Secondly, the modern view of the terminal innervation, and in particular the motor end-plate, as a labile entity, is fully confirmed by the present study. Moreover, this lability is understandable in terms of an adaptive response to a physiological need, which is all the more impressive because it takes place at the lowest level of the hierarchy of the motor system (Weiss, 1941).

REFERENCES

- ADAL, M.N. & BARKER, D. (1967). The fine structure of cat fusimotor endings. *J. Physiol., Lond.* 192, 50 - 52P.
- ADAMS, R.D., COERS, C. & WALTON, J.N. (1968). Report of a sub-committee on quantitation of muscle biopsy findings. Appendix B to the Minutes of the Research Group on Neuromuscular Diseases. *J. neurol. Sci.* 6, 179 - 188.
- ALLEN, D.E., JOHNSON, A.G. & WOOLF, A.L. (1969). The intramuscular nerve endings in dystrophia myotonica - a biopsy study by vital staining and electron microscopy. *J. Anat.* 105(1), 1 - 26.
- ALLWOOD, M.J. (1958). Blood flow in the foot and calf in the elderly; a comparison with that in the young adult. *Clin. Sci.* 17, 331 - 338.
- ANDREW, W., SHOCK, N.W., BARROWS, C.H. & YIENGST, M.J. (1959). Correlation of age changes in histological and chemical characteristics in some tissues in the rat. *J. Geront.* 14(4), 405 - 414.
- BARKER, D. (1964). The structure and distribution of muscle receptors. In Symposium on Muscle Receptors, ed. BARKER, D., pp. 227 - 240. Hong Kong University Press.

- BARKER, D. & IP, M.C. (1963). A silver method for demonstrating the innervation of mammalian muscle in teased preparations. *J. Physiol., Lond.* 169(3), 73 - 74P.
- BARKER, D. & IP, M.C. (1965). The probable existence of motor end-plate replacement. *J. Physiol., Lond.* 176, 11 - 12P.
- BARKER, D. & IP, M.C. (1966). Sprouting and degeneration of mammalian motor axons in normal and de-afferentated skeletal muscle. *Proc. R. Soc. B.* 163(993), 538 - 554.
- BARKER, D., STACEY, M.J. & ADAL, M.N. (1970). Fusimotor innervation in the cat. *Phil. Trans. R. Soc. Lond. B.* 258(825), 315 - 342.
- BARNARD, R.J., EDGERTON, V.R., FURUKAWA, T. & PETER, J.B. (1971). Histochemical, biochemical and contractile properties of red, white and intermediate fibers. *Am. J. Physiol.* 220(2), 410 - 414.
- BETHLEM, J. (1970). Muscle Pathology : Introduction and Atlas. Amsterdam : North-Holland Publishing Co.
- BOEKE, J. (1911). Beitrage zur Kenntniss der motorischen Nervenendigungen. *Int. Mschr. Anat. Physiol.* 28, 377 - 443.

- BULLER, A.J. (1965). Mammalian slow and fast skeletal muscle. In Studies in Physiology, ed. CURTIS, P.R. & McINTYRE, A.K., pp. 24 - 28. Berlin : Springer-Verlag.
- BULLER, A.J., ECCLES, J.C. & ECCLES, R.M. (1960). Interactions between motoneurons and muscles in respect of the characteristic speeds of their responses. *J. Physiol., Lond.* 150, 417 - 439.
- BULLER, A.J. & LEWIS, D.M. (1965). Some observations on the effects of tenotomy in the rabbit. *J. Physiol., Lond.* 178, 326 - 342.
- CAMPBELL, M.J. & McCOMAS, A.J. (1970). The effects of ageing on muscle function. In Abstracts of the 5th Symposium on Current Research on Muscular Dystrophy and Related Diseases. Muscular Dystrophy Group of Great Britain.
- CAREY, E.J. (1941). Experimental pleomorphism of motor nerve plates as a mode of functional protoplasmic movement. *Anat. Rec.* 81, 393 - 413.
- CAREY, E.J., DOWNER, E.M., TOOMEY, F.B. & HAUSHALTER, E. (1946). Morphologic effects of DDT on nerve endings, neurosomes and fiber types in voluntary muscles. *Proc. Soc. exp. Biol. Med.* 62, 76 - 83.

- CAREY, E.J., MASSOPUST, L.C., HAUSHALTER, E., SWEENEY, J., SARIBALIS, C. & RAGGIO, J. (1946). Studies on amoeboid motion and secretion of motor end-plates. VIII. Experimental morphology and pathology of the chemical transmitter of nerve impulses in the course of Wallerian degeneration. *Am. J. Path.* 22, 1205 - 1258.
- CARELTON, H.M. & DRURY, R.A.B. (1957). Histological Technique for Normal and Pathological Tissues and the Identification of Parasites, 3rd edn. Oxford : University Press.
- CASSIE, R.M. (1954). Some uses of probability paper in the analysis of size frequency distributions. *Austral. J. mar. Freshwat. Res.* 5(3), 513 - 522.
- COERS, C. (1955). Les variations structurelles normales et pathologiques de la jonction neuromusculaire. *Acta neurol. psychiat. belg.* 55, 741 - 866.
- COERS, C. & WOOLF, A.L. (1959). The Innervation of Muscle. A Biopsy Study. Oxford : Blackwell Scientific Publications.
- COLE, W.V. (1955). Motor endings in the striated muscle of vertebrates. *J. comp. Neurol.* 102, 671 - 716.
- COLE, W.V. (1957). Structural variations of nerve endings in the striated muscles of the rat. *J. comp. Neurol.* 108, 445 - 463.

COMFORT, A. (1956). Maximum ages reached by domestic cats.

J. Mammal. 37(1), 118 - 119.

COTTRELL, L. (1940). Histologic variations with age in apparently normal peripheral nerve trunks.

Arch. Neur. Psychiat., Chicago 43, 1138 - 1150.

Cited in KORENCHEVSKY, V. (1961). Physiological and Pathological Ageing, p. 459. Basel : S. Karger.

CROWE, A. & RAGAB, A.H.M.F. (1970). The structure, distribution and innervation of spindles in the extensor digitorum brevis muscle of the tortoise Testudo graeca.

J. Anat. 106(3), 521 - 538.

DENZ, F.A. (1951). Myoneural junction and toxic agents.

J. Path. Bact. 63, 235 - 247.

von DOYERE, M. (1840). Memoire sur les tardigrades.

Annls. Sci. nat. 2nd series 14, 269 - 361.

DUCHEN, L.W. (1971a). An electron microscopic comparison of motor end-plates of slow and fast muscle fibres of the mouse. J. neurol. Sci. 14(1), 37 - 46.

DUCHEN, L.W. (1971b). An electron microscopic study of the changes induced by botulinum toxin in the motor end-plates of slow and fast skeletal muscle fibres of the mouse. J. neurol. Sci. 14(1), 47 - 60.

- DUCHEN, L.W. & STRICH, S.J. (1968). The effects of botulinum toxin on the pattern of innervation of skeletal muscle in the mouse. *Q. Jl. exp. Physiol.* 53, 84 - 89.
- DUCHEN, L.W., STOLKIN, C. & TONGE, D.A. (1972). Light and electron microscopic changes in slow and fast muscle fibres and their end-plates in the mouse after local injection of tetanus toxin, *J. Physiol., Lond.* 222(2), 147 - 148P.
- DUNCAN, D. (1934). A determination of the number of nerve fibres in the eighth thoracic and the largest lumbar ventral roots of the albino rat. *J. comp. Neurol.* 59, 47 - 60.
- EDDS, M. (1950). Collateral regeneration of residual motor axons in partially denervated muscles. *J. exp. Zool.* 113, 517 - 552.
- EDDS, M. (1953). Collateral nerve regeneration. *Q. Rev. Biol.* 28, 260 - 276.
- EDGERTON, V.R. & SIMPSON, D.R. (1969). The intermediate muscle fibres of rats and guinea pigs. *J. Histochem. Cytochem.* 17, 828-838.
- EDGERTON, V.R. & SIMPSON, D.R. (1971). Dynamic and metabolic relationships in the rat EDL muscle. *Expl. Neurol.* 30(2), 374 - 376.

- EDSTROM, L. & TORLEGARD, K. (1969). Area estimation of transversely sectioned muscle fibres. *Z. wiss. Mikrosk.* 69, 166 - 178.
- ENGEL, W.K. (1965). Histochemistry of neuromuscular diseases, significance of muscle fibre types. In Proceedings of the 8th International Congress of Neurology, vol. 2, pp. 67 - 101. Amsterdam : Excerpta Medica.
- ENGEL, W.K., BROOKE, M.H. & NELSON, P.G. (1965). Histochemical studies of denervated or tenotomized cat muscle. Illustrating difficulties in relating experimental animal conditions to human neuromuscular disease. *Ann. N. Y. Acad. Sci.* 138, 160 - 186.
- ENGEL, W.K. & CUNNINGHAM, G.G. (1963). Rapid examination of muscle tissue. An improved trichrome method for rapid diagnosis of muscle fresh-frozen biopsy sections. *Neurology, Minneap.* 13(11), 919 - 923.
- ERANKO, O. & PALKAMA, A. (1961). Improved localization of phosphorylase by the use of polyvinyl pyrrolidone and high substrate concentration. *J. Histochem. Cytochem.* 9, 585.
- FALIN, L. (1935). Sur les changements dans les terminations motrices des nerfs pendant l'atrophie experimentale de la fibre musculaire striee. *Bull. Histol. appl. Physiol. Path.* 12, 234 - 253.

- FIDZIANSKA, A. (1971). Electron microscopic study of human foetal muscle, motor end-plate and nerve. Preliminary report. *Acta neuropath.* 17(3), 234 - 237.
- FISHER, R.A. & YATES, F. (1957). Statistical Tables for Biological, Agricultural and Medical Research, 5th edn. London : Oliver & Boyd.
- FULLERTON, P.M. & GILLIATT, P.W. (1967). Pressure neuropathy in the hind foot of the guinea-pig. *J. Neurol. Neurosurg. Psychiatr.* 30, 18 - 25.
- GAIRNS, F.W. (1930). A modified gold chloride method for the demonstration of nerve endings. *Q. Jl. microsc. Sci.* 74, 151 - 154.
- GARDNER, E. (1940). Decrease in human neurones with age. *Anat. Rec.* 77, 529 - 536.
- GEREBTZOFF, M.A., PHILIPOTT, E. & DALLEMAGNE, M.J. (1954). Recherches histochemiques sur les acetylcholine-et choline-esterases 2. Activite enzymatique dans les muscles lents et rapides des mammiferes et des oiseaux. *Acta Anat.* 20, 145 - 151.
- GLADDEN, M.H. (1971). The Development of Innervation in Tenotomised Muscles of the Rat. Ph.D. Thesis : University of Liverpool.

- GOLDSPINK, G. (1964). The combined effects of exercise and reduced food intake on skeletal muscle fibres.
J. cell. comp. Physiol. 63, 209 - 216.
- GORDON, E.E. (1967). Anatomical and biochemical adaptations of muscle to different exercises.
J. Am. med. Ass. 201, 755 - 758.
- GRANBACHER, N. (1971). Uber die Grossenbeziehungen der Muskelfasern zu ihren motorischen Endplatten und Nerven bei Hypertrophie und Atrophie. Z. Anat. EntwGesch. 135, 76 - 87.
- GREENFIELD, J.G., SHY, G.M., ALVORD, E.C. & BERG, L. (1957). An Atlas of Muscle Pathology. Edinburgh : E. & S. Livingstone.
- GRUBER, H. (1966). Die Grossebeziehung von Muskelfaservolumen und Fläche der motorischen Endplatte bei verschiedenen Skelet-muskeln der Ratte. Acta anat. 64, 628 - 633.
- GUTH, L. & SAMAHA, F.J. (1969). Qualitative differences between actomyosin ATPase of slow and fast mammalian muscles. Expl. Neurol. 25, 138 - 152.
- GUTH, L. & SAMAHA, F.J. (1970). Procedure for the histochemical demonstration of actomyosin ATPase. Expl. Neurol. 28(2), 365 - 367.

- GUTH, L. & YELLIN, H. (1971). The dynamic nature of the so-called "fibre types" of mammalian skeletal muscle. *Expl. Neurol.* 31, 277 - 300.
- GUTMANN, E. & HANZLIKOVA, V. (1965). Age changes of motor endplates in muscle fibres of the rat. *Gerontologia.* 11, 12 - 24.
- GUTMANN, E. & HANZLIKOVA, V. (1966). Motor unit in old age. *Nature, Lond.* 209, 921 - 922.
- GUTMANN, E., HANZLIKOVA, V. & JAKOUBEK, B. (1968). Changes in the neuromuscular system during old age. *Exp. Gerontol.* 3, 141 - 146.
- GUTMANN, E., HANZLIKOVA, V. & VYSKOCIL, F. (1971). Age changes in cross-striated muscle of the rat. *J. Physiol., Lond.* 216(2), 331 - 334.
- HARDING, J.P. (1949). The use of probability paper for the graphical analysis of polymodal frequency distributions. *J. mar. biol. Ass. U.K.* 28, 141 - 153.
- HARRIMAN, D.G.F., TAVERNER, D. & WOOLF, A.L. (1970). Ekbohm's syndrome and burning paraesthesiae. A biopsy study by vital staining and electron microscopy of the intramuscular innervation with a note on age changes in motor nerve endings in distal muscles. *Brain.* 93(2), 393 - 406.

- HARRIS, C. (1954). The morphology of the myoneural junction as influenced by neurotoxic drugs. *Am. J. Path.* 30, 501 - 508.
- HENNEMANN, E. & OLSON, C.B. (1965). Relations between structure and function in the design of skeletal muscles. *J. Neurophysiol.* 28(3), 581 - 598.
- HOFFMAN, H. (1951). Fate of interrupted nerve-fibres regenerating into partially denervated muscles. *Aust. J. exp. Biol. med. Sci.* 29, 211 - 219.
- HOFFMAN, H. (1953). The persistence of hyperneurotized endings in mammalian muscles. *J. comp. Neurol.* 99, 331 - 346.
- HUMASON, G.L. (1962). Animal Tissue Techniques. London : W. H. Freeman & Co.
- IP, M.C. (1967). A combined method for demonstrating the cholinesterase activity and the nervous structure of mammalian peripheral motor endings in teased preparations. *J. Physiol., Lond.* 192, 801 - 803.
- IWAYAMA, T. (1969). Relation of regenerating nerve terminals to original end-plates. *Nature, Lond.* 224(5214), 81 - 82.

- JENNEKENS, F.G.I., TOMLINSON, B.E. & WALTON, J.N. (1971).
Histochemical aspects of five limb muscles in old age.
An autopsy study. *J. neurol. Sci.* 14(3), 259 - 276.
- JOUBERT, D.M. (1956). An analysis of factors affecting
post-natal growth and development of the muscle fibre.
J. agric. Sci., Camb. 47, 59 - 102.
- KARNOVSKY, M.J. & ROOTS, I. (1964). A 'direct-colouring'
thiocholine method for cholinesterases.
J. Histochem. Cytochem. 12(3), 219 - 221.
- KRAUSE, W. (1863). Ueber die Endigung der Muskelnerven.
Z. rat. Med. 18, 136 - 160.
- KRUGER, P. (1960). Die Innervation phasisch bzw. tonisch
reagierender Muskeln von Säugetieren und des Menschen.
Acta anat. 40, 186 - 210.
- KUHNE, W. (1887). Neue Untersuchungen über motorische
Nervenendigung. *Z. Biol.* 23, 1 - 148.
- KUPFER, C. (1960). Motor innervation of extraocular muscle.
J. Physiol., Lond. 153, 522 - 526.
- LANSING, A.I. (1959). General biology of senescence.
In Handbook of Aging and the Individual.
Psychological and Biological Aspects, ed. BIRREN, J.E.,
p. 121. Chicago : Chicago University Press.

- van LINGE, B. (1962). The response of muscle to strenuous exercise. An experimental study in the rat. *J. Bone Jt. Surg.* 44B(3), 711 - 721.
- LULLMAN-RAUCH, R. (1971). The regeneration of neuromuscular junctions during spontaneous re-innervation of the rat diaphragm. *Z. Zellforsch. mikrosk. Anat.* 121, 593 - 603.
- MAVRINSKAYA, L.F. (1962). Evolutionary and morphological changes in vertebrate junctions. *Arkh. Anat. Gistol. Embriol.* 43, 3 - 15 (in Russian), trans. in *Fedn. Proc. Fedn Am. Socs. exp. Biol.* 994 - 1008, 1963.
- MAXWELL, A., WARD, H.A. & NAIRN, R.C. (1966). Freezing in an isopentane-liquid nitrogen mixture and storage in 2-octanol : technical improvements for immunofluorescence. *Stain Technol.* 41, 305.
- MCCOMAS, A.J., SICA, R.E.P. & CAMPBELL, M.J. (1971). "Sick" motoneurons. A unifying concept of muscle disease. *Lancet* 1(7694), 321 - 325.
- MCPHEDRAN, A.M., WUERKER, R.B. & HENNEMAN, E. (1965). Properties of motor units in a homogeneous red muscle (soleus) of the cat. *J. Neurophysiol.* 28(1), 71 - 84.

- MIVART, St.G. (1881). The Cat. An Introduction to the Study of Backboned Animals especially Mammals, pp. 154 - 164.
London : John Murray.
- MORONEY, M.J. (1956). Facts from Figures, 3rd edn.
London : Penguin.
- MORRIS, C.J. & WOOLF, A.L. (1970). Mechanism of type I muscle fibre grouping. *Nature, Lond.* 226(5250), 1061 - 1062.
- MOYER, E.K. (1959). In The Process of Aging in the Nervous System, ed. BIRREN, J.E., IMUS, H.A. & WINDLE, W.E., pp. 64. Springfield : Charles C. Thomas.
- MOYER, E.K. & KALISZEWSKI, B.F. (1958). The number of nerve fibres in motor spinal roots of young, mature and aged cats. *Anat. Rec.* 131, 681 - 699.
- NACHLAS, M.M., TSOU, K.-C., de SOUZA, E., CHENG, C.-S. & SELIGMAN, A.M. (1957). Cytochemical demonstration of succinic dehydrogenase by the use of a new p-nitrophenyl substituted ditetrazole. *J. Histochem. Cytochem.* 5, 420 - 436. Cited in PEARSE, A.G.E. (1961). Histochemistry, Theoretical and Applied, 2nd edn., p. 910.
London : Churchill.
- NYSTROM, B. (1968a). Histochemical studies of end-plate bound esterases in "slow-red" and "fast-white" cat muscles during postnatal development. *Acta neurol. scand.* 44(3), 295 - 318.

- NYSTROM, B. (1968b). Postnatal development of motor nerve terminals in "slow-red" and "fast-white" cat muscles. *Acta neurol. scand.* 44(3), 363 - 383.
- NYSTROM, B. (1968c). Histochemistry of developing cat muscles. *Acta neurol. scand.* 44(4), 405 - 439.
- OGATA, M. (1965). A histochemical study on the structural differences of motor endplate in the red, white and intermediate muscle fibres of mouse limb muscle. *Acta Med. Okayama* 19, 149 - 153.
- PADYKULA, H.A. & GAUTHIER, G.F. (1970). The ultrastructure of the neuromuscular junction of mammalian red, white, and intermediate skeletal muscle fibers. *J. cell Biol.*, 46, 27 - 41.
- PEARSE, A.G.E. (1961). Histochemistry, Theoretical and Applied, 2nd edn. London : Churchill.
- RAGAB, A.H.M.F. (1970). The Structure and Innervation of Tortoise Muscle Spindles. Ph.D. Thesis, University of Durham.
- REDFERN, P.A. (1970). Neuromuscular transmission in newborn rats. *J. Physiol., Lond.* 209, 701 - 709.
- RESKE-NIELSEN, E., HARMSSEN, A. & HOJGAARD, J. (1969). Modified technique of muscle biopsy. *Acta path. microbiol. scand.* 77(4), 578 - 586.

RESKE-NIELSEN, E., COERS, C. & HARMSSEN, A. (1970).

Qualitative and quantitative histological study of neuromuscular biopsies from healthy young men.

J. neurol. Sci. 10, 369 - 384.

ROMANUL, F.C.A. (1964). Anzymes in muscle. I. Histochemical studies of enzymes in individual muscle fibres.

Archs. Neurol., Chicago 11, 355 - 368.

ROMANUL, F.C.A. & van der MEULEN, J.P. (1967). Slow and fast muscles after cross innervation. Archs. Neurol.,

Chicago 17, 387 - 401.

ROWE, R.W.D. (1969). The effect of senility on skeletal muscles in the mouse. Exp. Gerontol. 4, 119 - 126.

ROWE, R.W.D. & GOLDSPIK, G. (1968). Surgically induced hypertrophy in skeletal muscles of the laboratory mouse. Anat. Rec. 161, 69 - 75.

RUBINSTEIN, L.J. (1960). Aging changes in muscle.

In Structure and Function of Muscle, vol. 3,

ed. BOURNE, G.H., pp. 202 - 226. New York : Academic.

SACCO, G., BUCHTHAL, F. & ROSENFALCK, P. (1962). Motor unit potentials at different ages. Archs Neurol.,

Chicago 6, 366 - 373.

- SALMON^S, S. & VRBOVA, G. (1969). The influence of activity on some contractile characteristics of mammalian fast and slow muscles. *J. Physiol., Lond.* 201, 535 - 549.
- SERRATRICE, G., ROUX, H. & AQUARON, R. (1968). Proximal muscular weakness in elderly subjects. Report of 12 cases. *J. neurol. Sci.* 7, 275 - 299.
- SNEDECOR, G.W. (1962). Statistical Methods, 5th edn., pp. 198 - 202. Ames : Iowa State University Press.
- SOKAL, R.R. & ROHLF, F.J. (1969). Biometry. The Principles and Practice of Statistics in Biological Research, pp. 668 - 742. San Francisco : W.H. Freeman & Co.
- STACEY, M.J. (1969). Free nerve endings in skeletal muscle of the cat. *J. Anat.* 105(2), 231 - 234.
- STEIN, J.M. & PADYKULA, H.A. (1962). Histochemical classification of individual skeletal muscle fibers of the rat. *Am. J. Anat.* 110, 103 - 123.
- TERAVAINEN, H. (1967). Electron microscopic localization of cholinesterases in the rat myoneural junction. *Histochemie* 10, 266 - 271.
- TIEGS, O.W. (1953). Innervation of voluntary muscle. *Physiol. Rev.* 33, 90 - 144.

- TUFFERY, A.R. (1971). Growth and degeneration of motor end-plates in normal cat hind limb muscles.
J. Anat. 110(2), 221 - 247.
- VRBOVA, G. (1962). The effect of tenotomy on the speed of contraction of fast and slow mammalian muscles.
J. Physiol., Lond. 161, 25 - 26P.
- WEISS, P. (1941). Self-differentiation of the basic patterns of co-ordination. Comp. Psychol. Monogr. 17(4), 1 - 96.
- WILKINSON, H.J. (1929). The innervation of striated muscle.
Med. J. Austr. 2, 768 - 793.
- WOHLFART, G. (1958). Collateral regeneration in partially denervated muscles. Neurol., Minneap. 8(3), 175 - 180.
- WOOLF, A.L. (1966). The pathology of the intramuscular nerve endings. In Proceedings of the Vth International Congress of Neuropathology, ed. LUTHY, F. & BISCHOFF, A., pp. 641 - 647. London : Excerpta Medica.
- WOOLF, A.L. (1970). The structure and ultrastructure of the myasthenic motor end-plate. In Abstracts of the 5th Symposium on Current Research on Muscular Dystrophy and Related Diseases. Muscular Dystrophy Group of Great Britain.

WUERKER, R.B., McPHEDRAN, A.M. & HENNEMAN, E. (1965).

Properties of motor units in a heterogeneous pale muscle (m. gastrocnemius) of the cat. J. Neurophysiol. 28(1), 85 - 99.

YELLIN, H. (1967). Neural regulation of enzymes in muscle fibers of red and white muscles. Expl. Neurol. 19, 92 - 103.

YIENGST, M.J., BARROWS, C.H. & SHOCK, N.W. (1959).

Age changes in the chemical composition of muscle and liver in the rat. J. Geront. 14, 400 - 404.

ZACKS, S.I. (1964). The Motor End-plate.

Philadelphia : W. B. Saunders.

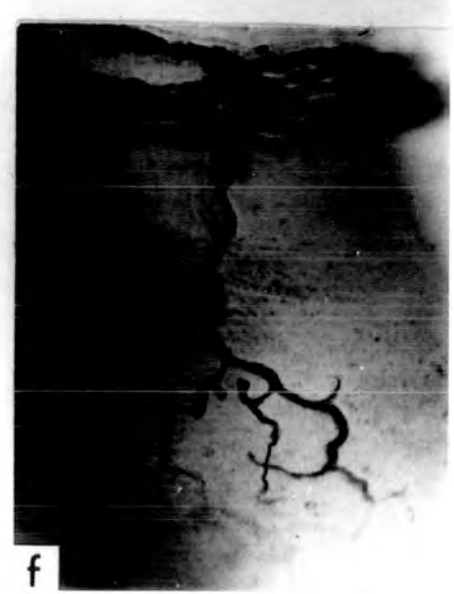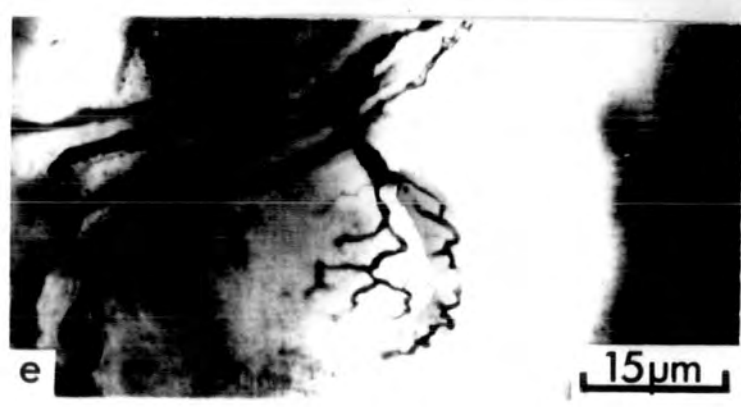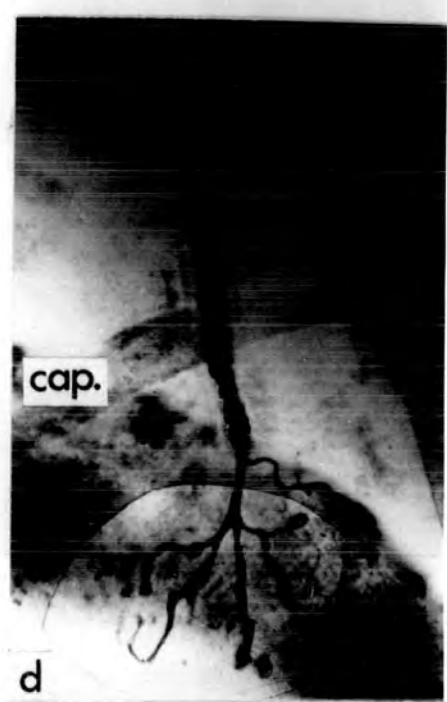
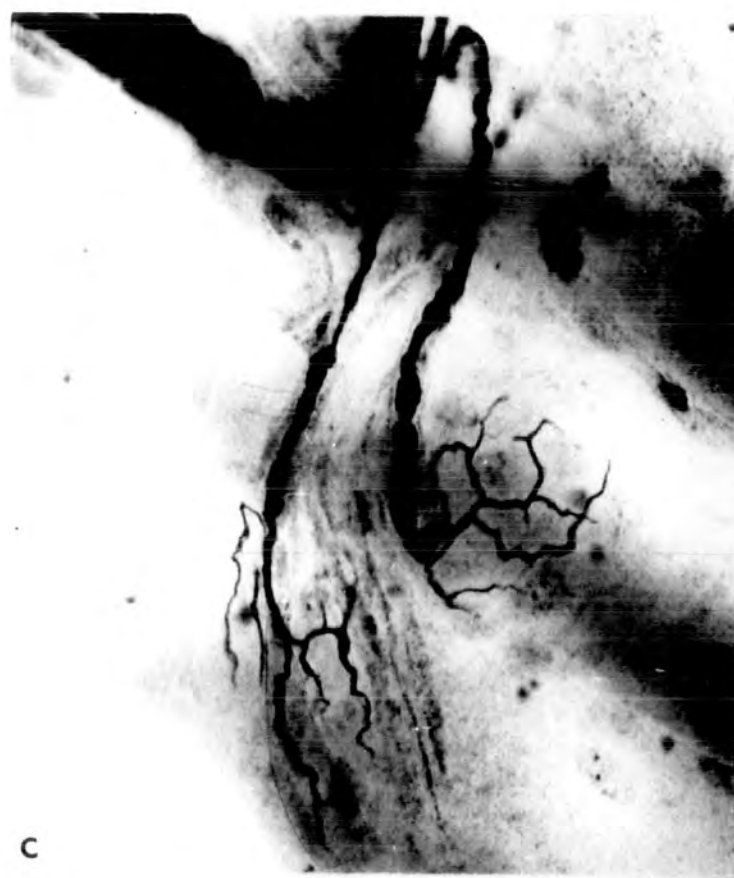
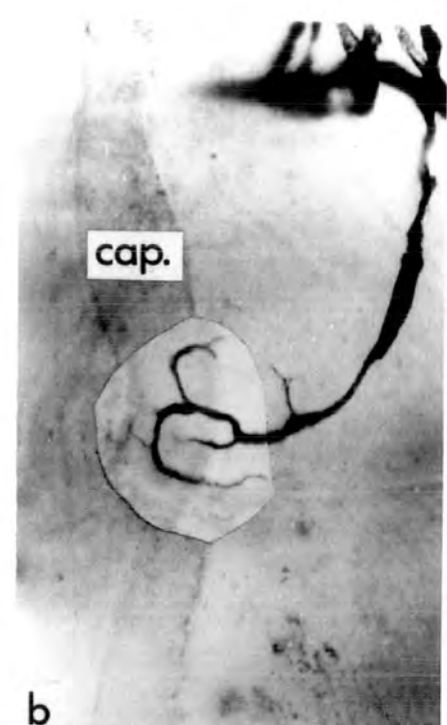
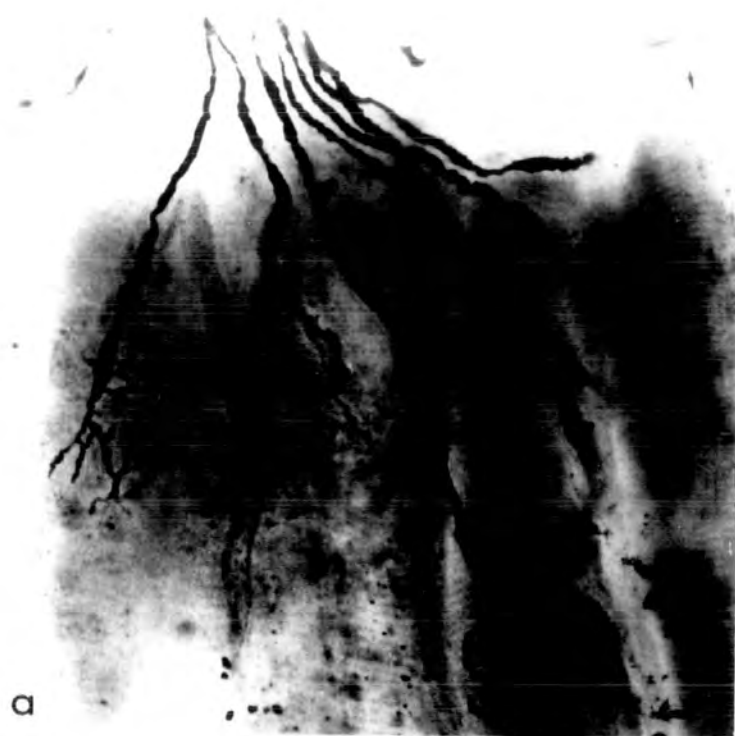PLATE I. Tl end-plates from PDQ muscles of young adult cats

All to the same scale.

The axon terminals are usually fine and end in delicate tapers and are quite numerous. However, knob and ring endings do occur (e - f) and occasionally the axon terminals have a coarser appearance (b).

In (d) one axon terminal takes origin high up on the preterminal region and ends in a slight swelling and could therefore be interpreted as a preterminal sprout (see Results 1.2).

Capillaries (cap.) are frequently associated with end-plates. Figure (a) illustrates a terminal spray of motor end-plates.

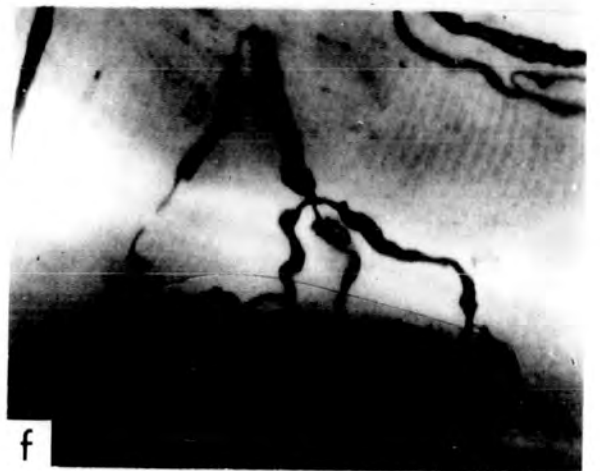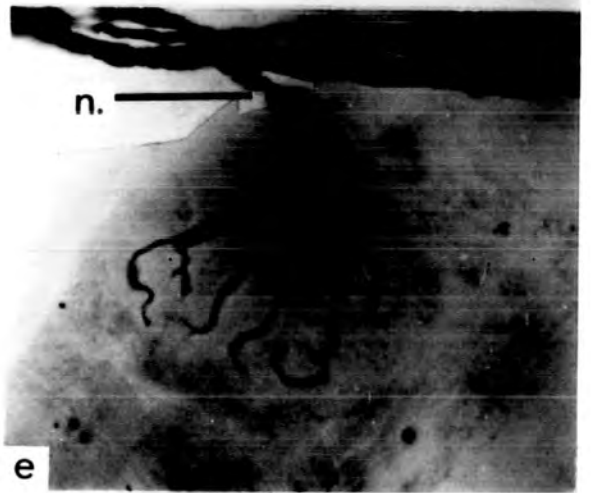
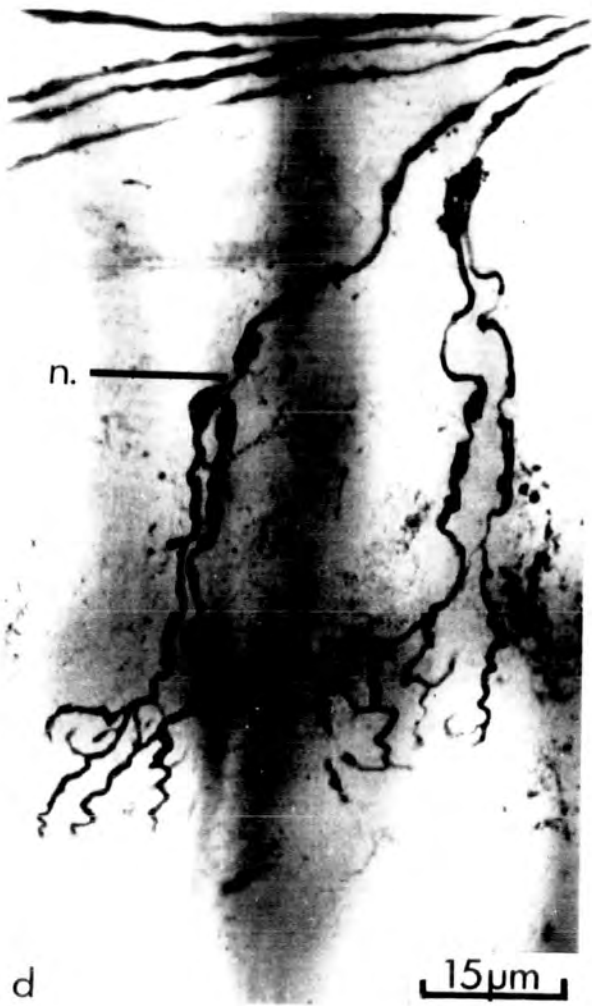
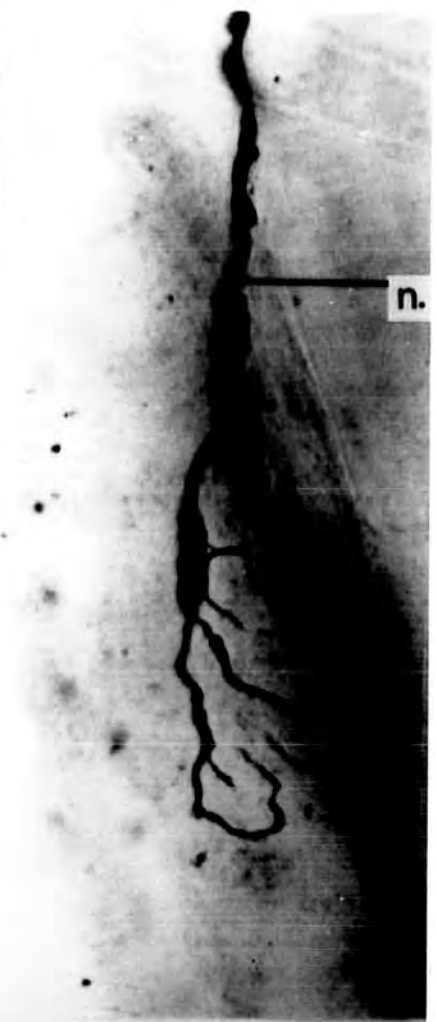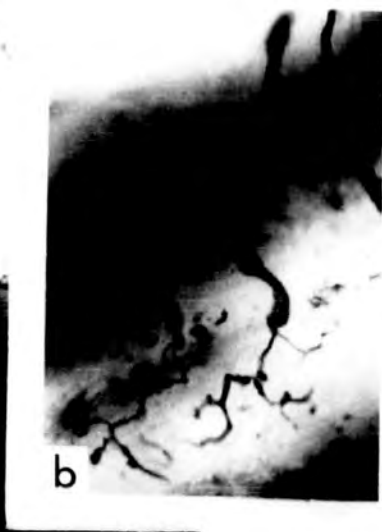
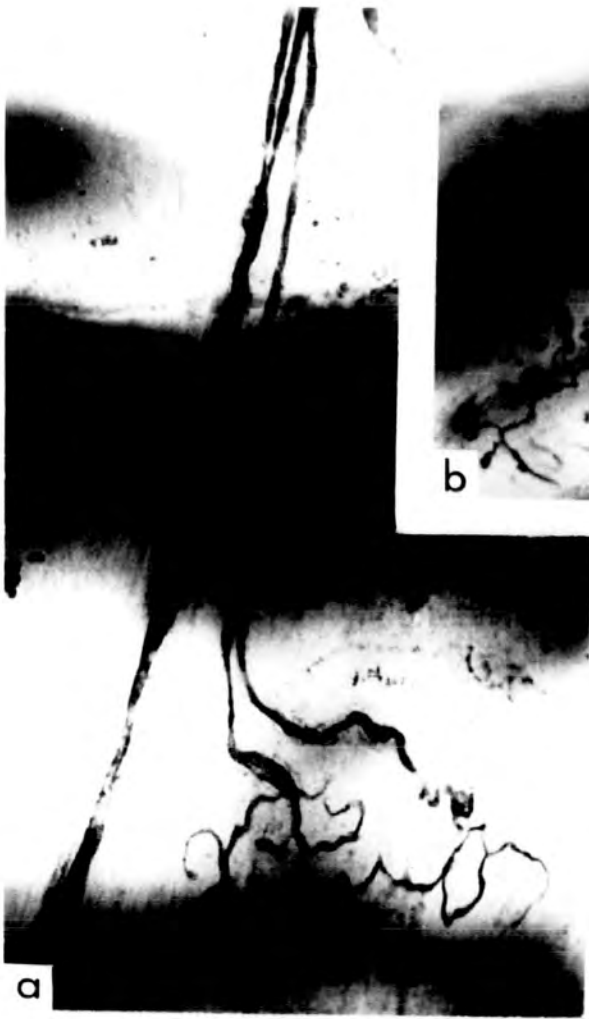


EVANS UNIVERSITY
LIBRARY
21 SEP 1972
EVANS, OHIO

PLATE II. Complex end-plates from PDQ muscles of young adult cats

All to the same scale.

- a) T2 ending. The terminal axon divides at the penultimate node and the two branches bear approximately equal numbers of axon terminals.
- b) T2 ending. The terminal axon divides at the terminal node. The branch to the left bears fewer axon terminals.
- c) T2 ending. The two branches of the terminal axon arise from a node and are of unequal length, the one to the left having a node (n.). The two branches bear approximately equal numbers of axon terminals.
- d) T2 endings. In each case the division of the terminal axon is at a more proximal node (n.) than is commonly found. The numbers of axon terminals formed by each myelinated branch of the terminal axon are approximately equal in the ending to the left, and markedly unequal in the ending to the right.
- e) T3 ending. All three myelinated branches of the terminal axon arise from the same node (n.). The total number of axon terminals is not greater than in T2 end-plates (cf. a - d).
- f) T4 ending. Branching occurs at two separate nodes.

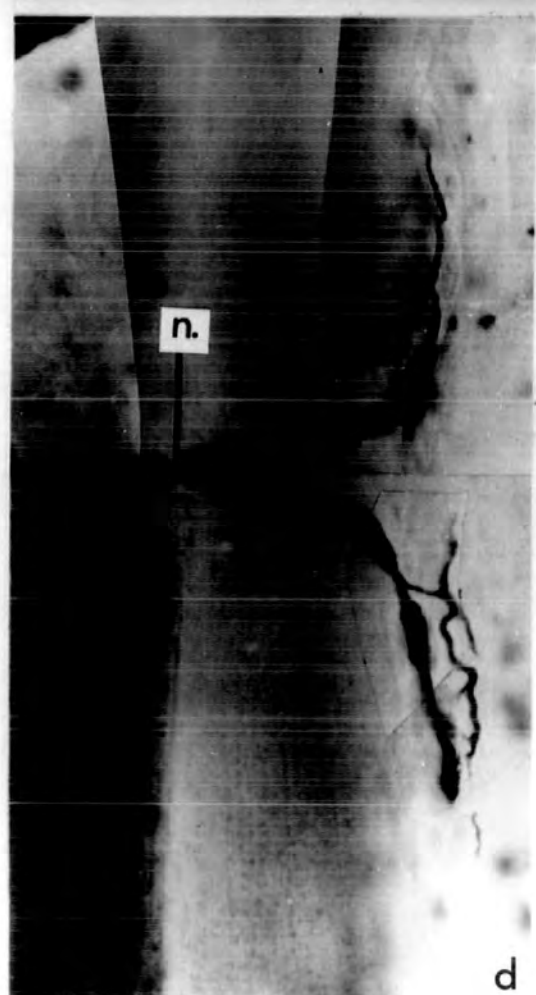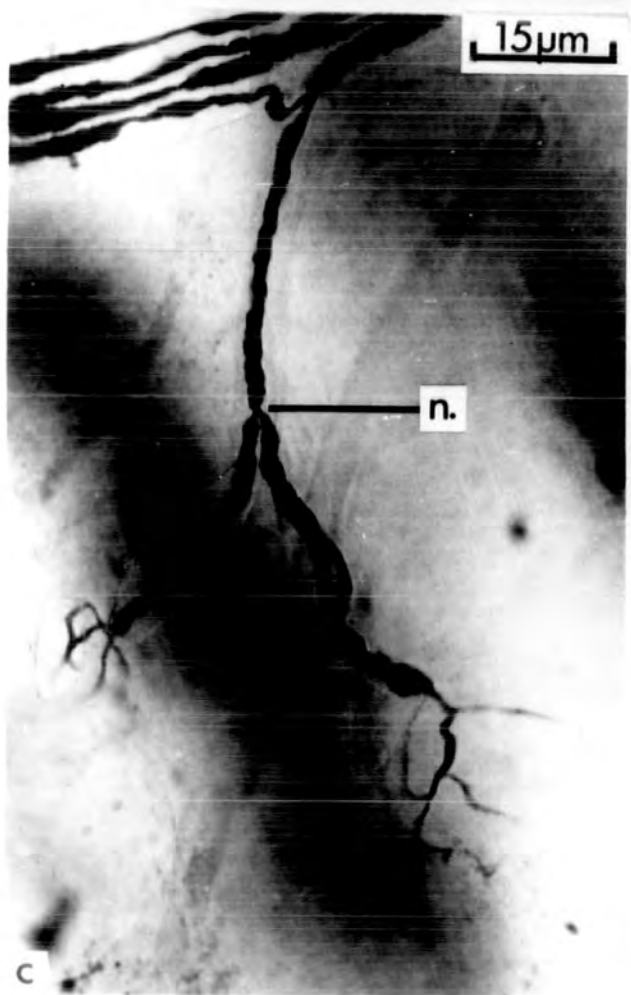
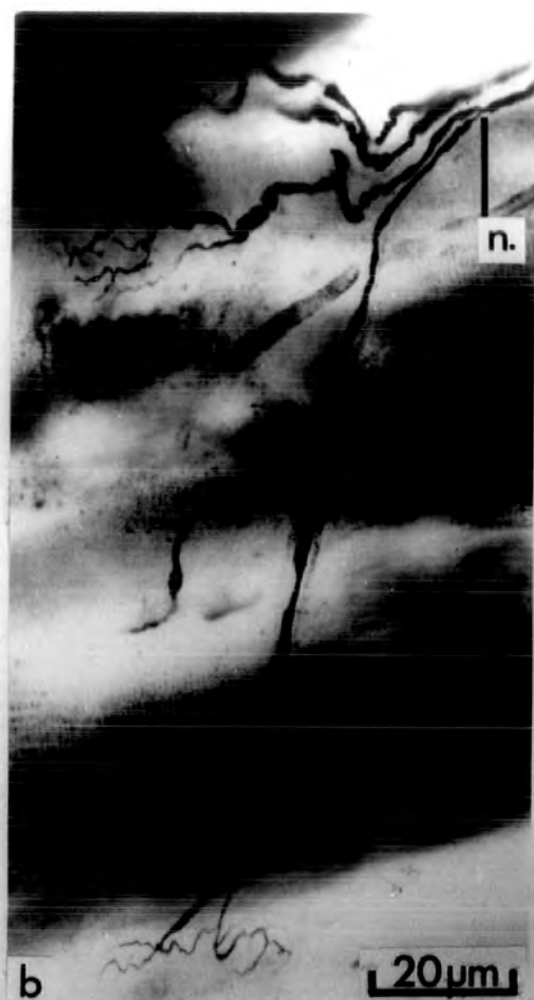

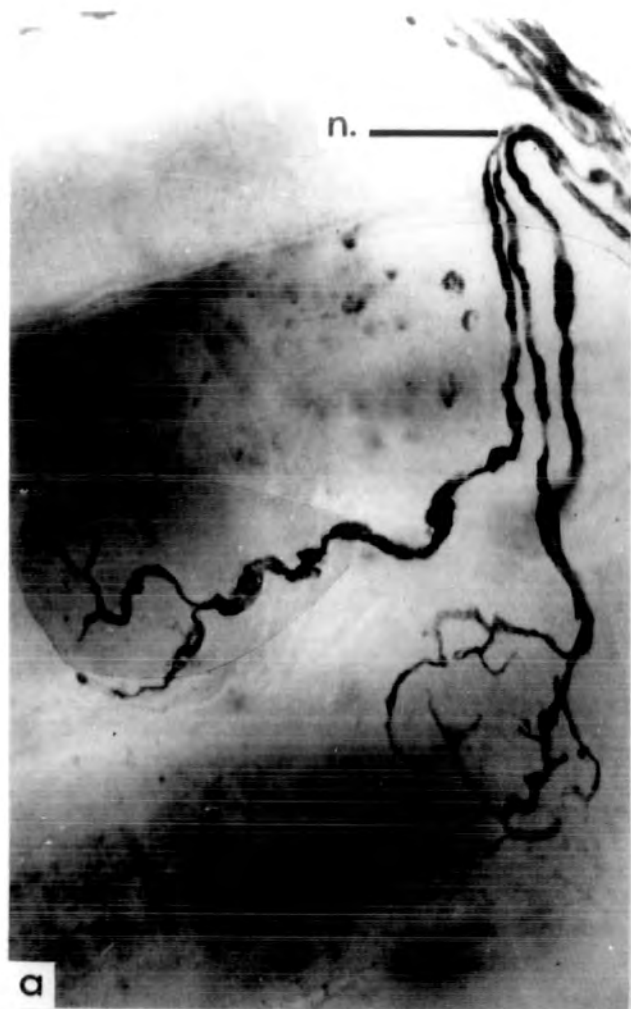
21 SEP 1972
LIBRARY

PLATE III. Collateral branching of terminal axons from
PDQ muscles of young adult cats

In each case the node (n.) at which branching occurs is indicated. Figures a, c and d are to the same scale.

- a) Both end-plates are of the T1 form.
- b) The two collateral end-plates lie on widely separated muscle fibres. Both endings receive contributions showing the thickening interpreted as myelination.
- c) The terminal axon divides in the small intramuscular nerve trunk. One branch forms the two end-plates shown, while the other remains in the terminal nerve bundle and eventually forms a third end-plate.
- d) The branches of the bifurcated terminal axon are short and the end-plates lie very close together on adjacent muscle fibres. Such configurations must be carefully distinguished from the extremely rare duplex endings.



21 SEP 1972
ALBANY LIBRARY

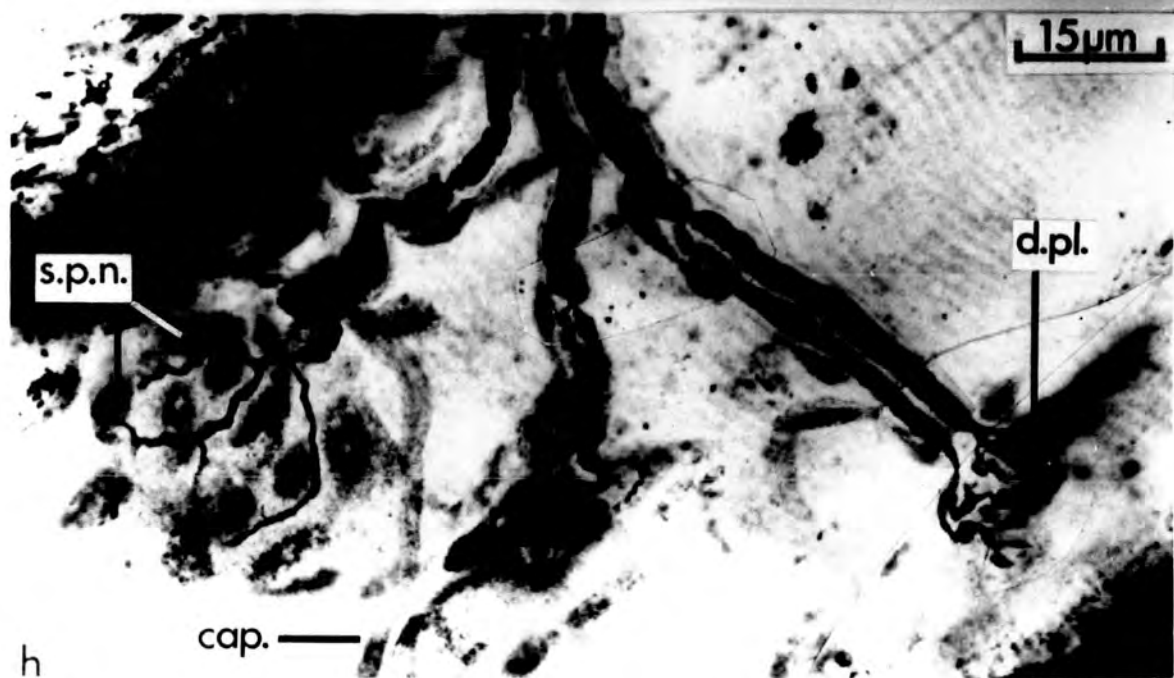
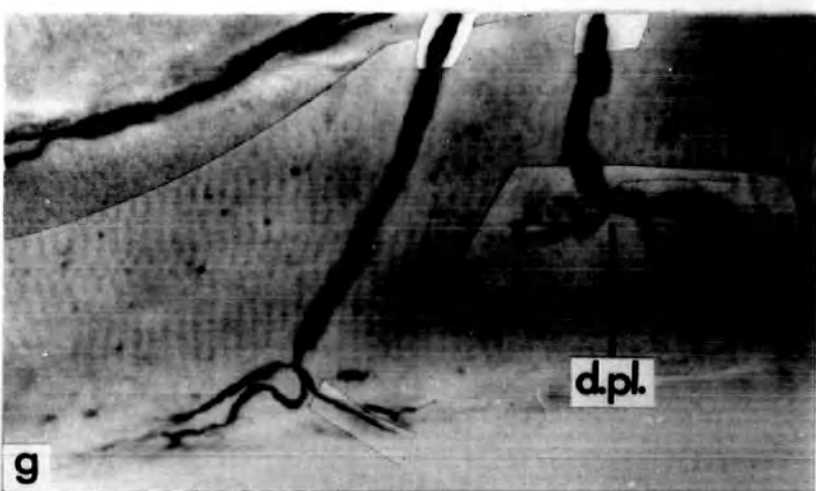
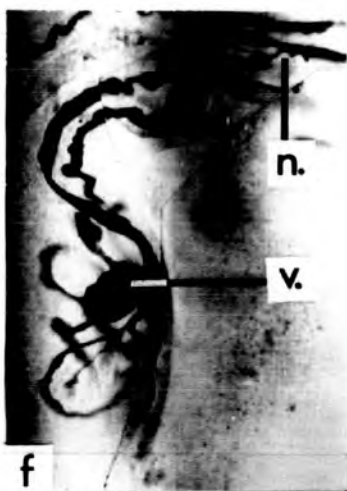
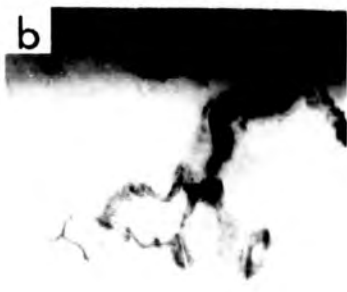
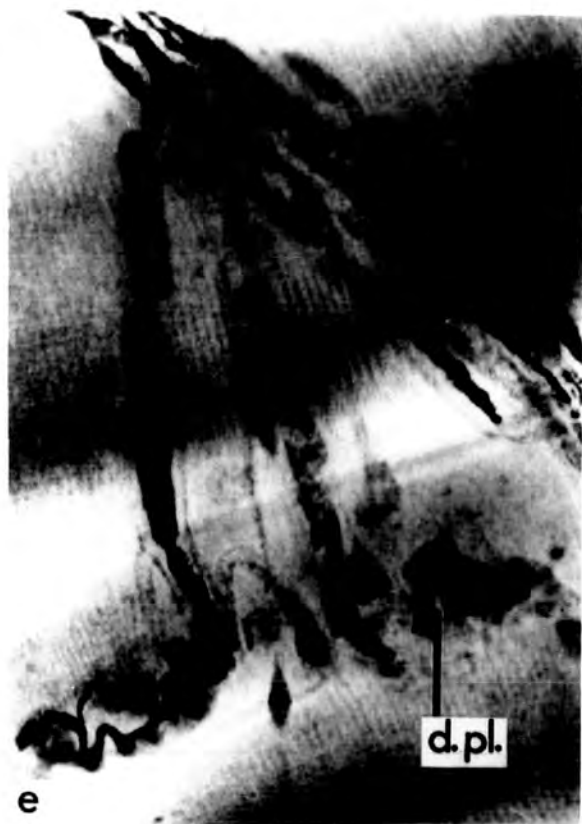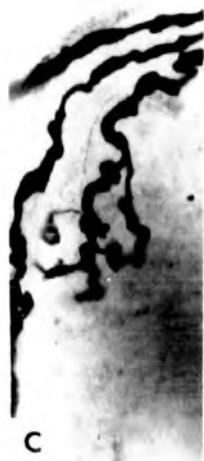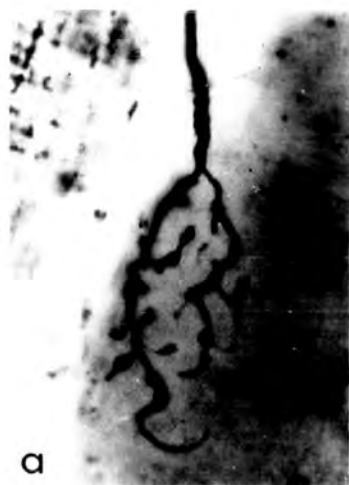PLATE IV. Degenerating motor end-plates from young adult

PDQ muscles

All to the same scale.

- a) Degenerating end-plate from a normal muscle.
The axon terminals have local thickenings, typical of the early phase of degeneration (cf. Fig. c).
- b) Degenerating end-plate from a normal muscle.
The axon terminals have the swollen, slightly retracted appearance characteristic of the middle phase of degeneration.
- c - d) Configurations comparable to Figs. a - b seen 24hr after section of the muscle nerve.
- e) The end-plate (d.pl.) in the centre is completely broken down and the distal axons are replaced by axonal debris. That the changes after nerve section are not synchronous in all end-plates is shown by the intact end-plate on the left (54hr after nerve section).
- f) A T2 end-plate with slightly inflated axon terminals has a vesicular axonic swelling (v.) on an axon terminal. The terminal axon bifurcates at a relatively proximal node (n.) (Unoperated).

Contd.



RECEIVED DIRECTOR
21 SEP 1972
FEDERAL
LIBRARY

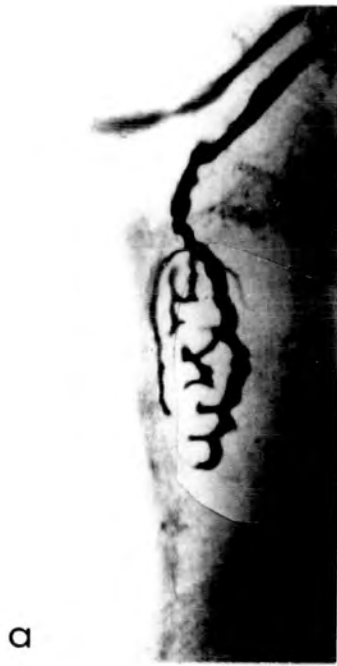- g) A T1 end-plate (d.pl.) in early degeneration adjacent to a normal T1 end-plate (Unoperated).
- h) A T2 end-plate in early degeneration (d.pl.) occurs in a terminal spray containing two normal end-plates, one of which is of the T2 form. The sole-plate nuclei (s.p.n.) are stained, showing that the T2 end-plates each have but a single sole-plate. A capillary (cap.) is also slightly stained (Unoperated).

PLATE V. Degenerating motor end-plates from peroneal muscles
of normal young adult cats

All the figures are from teased silver preparations and are to the same scale.

- a - c) End-plates with coarse, slightly swollen axon terminals, typical of the early phase of degeneration (PDQ).
- d) Two end-plates in a more advanced stage of degeneration, with somewhat inflated and retracted axon terminals. A well-developed contribution (c.) is also degenerating, having already lost its axon terminals. Part of a normal end-plate is included at the upper right for comparison (PDQ).
- e) The upper end-plate has undergone severe retraction and the axon terminals are inflated. The lower end-plate is normal in appearance (PDQ).
- f) The axon terminals of the end-plate to the right of the figure are slightly retracted and inflated. Two fine axon terminals end in swellings. The end-plate to the left is normal.(PL).
- g) Advanced retraction and inflation of the axon terminals has occurred. The nodal sprout (n.sp.) has a coarser appearance than is usual, suggesting that it too is affected by the degeneration process (PDQ).

Contd.



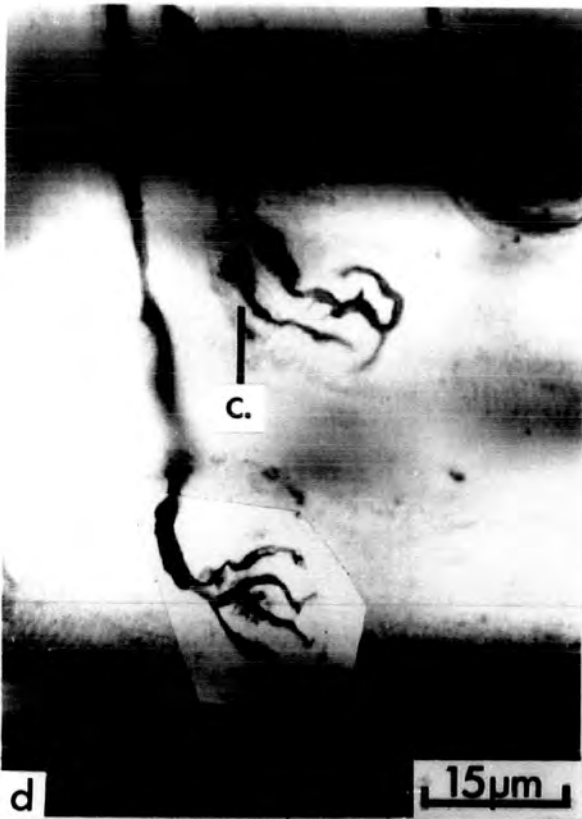a



b

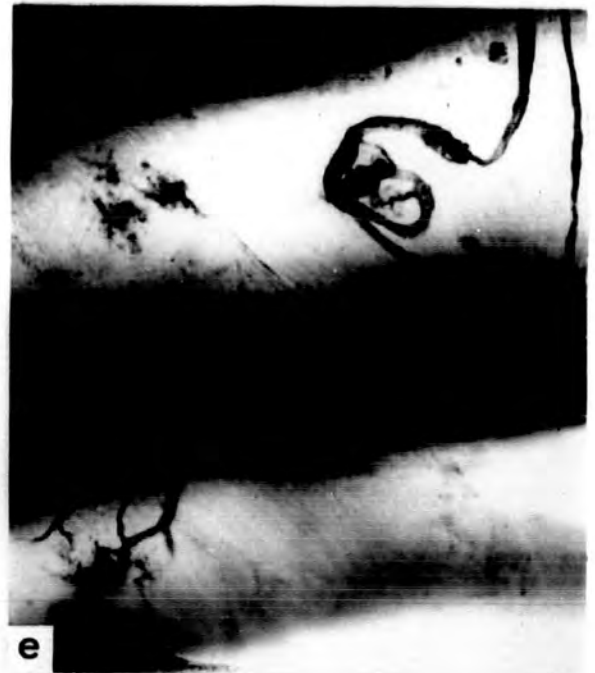

c

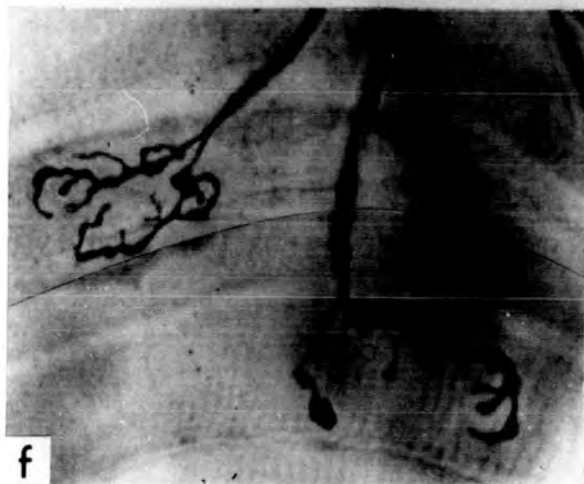


d

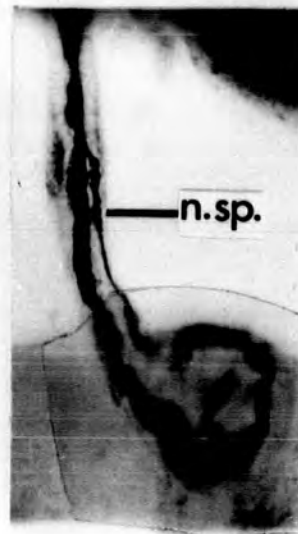
15µm



e



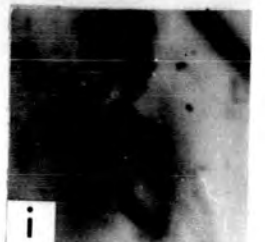f



g



h



i

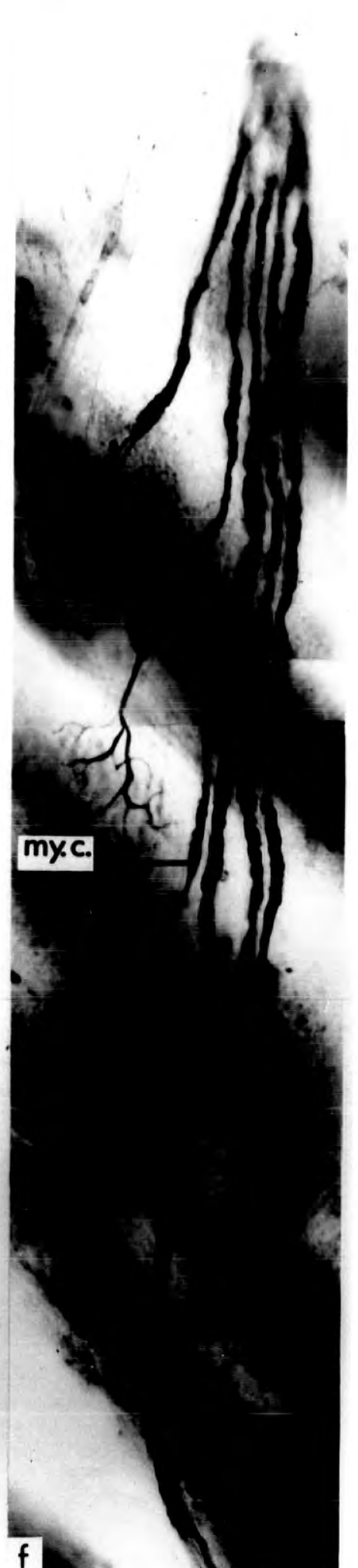
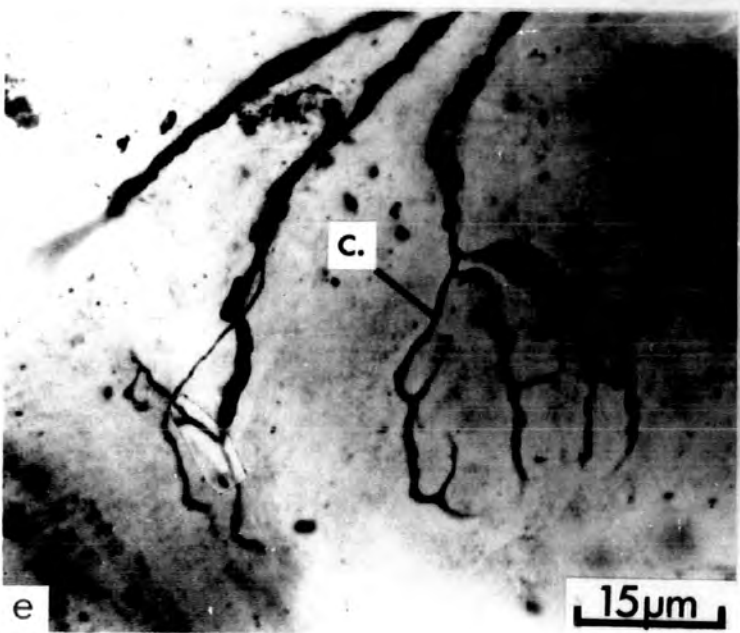
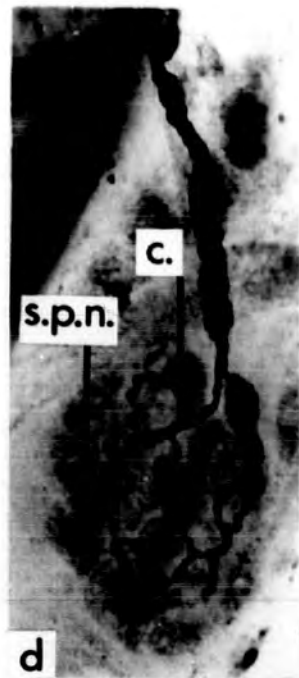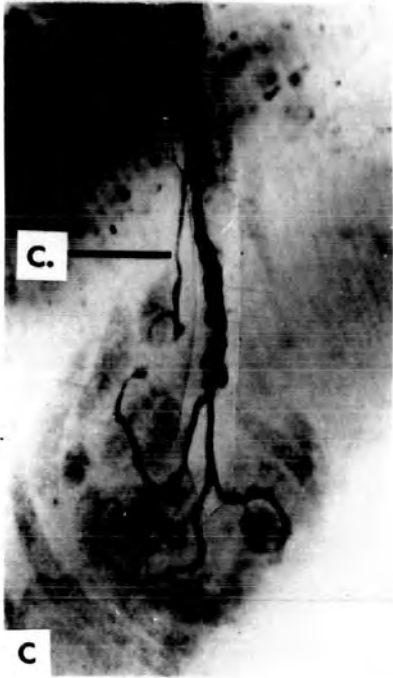
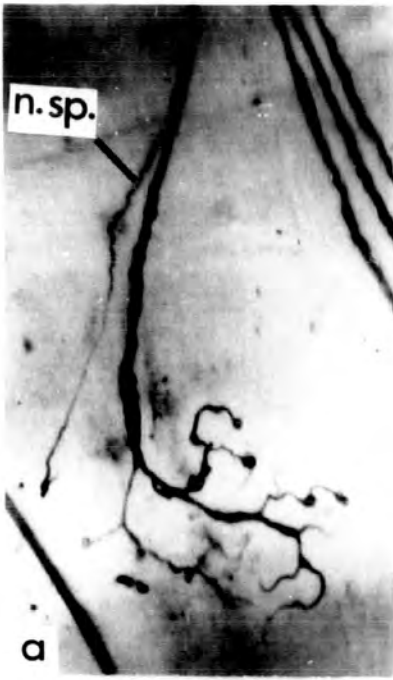UNIVERSITY OF
TORONTO
21 SEP 1972
LIBRARY

- h) Severe retraction of the axon terminals, typical of the middle phase of degeneration (PB).
- i) The axon terminals are almost completely retracted and have the granular appearance characteristic of the late phase of degeneration (PDQ).

PLATE VI. Growth configurations from peroneal muscles of
normal young adult cats

All the figures are from teased silver preparations and are to the same scale.

- a) T1 end-plate receiving a nodal sprout (n.sp.) which arises from the penultimate node and ends in a growth cone close to the axon terminals of the parent ending.
- b) The nodal sprout (n.sp.) arises from the penultimate node and ends very close to the axon terminals of the parent ending.
- c - d) T1 end-plates receiving contributions (c.). The sole-plate nuclei (s.p.n.) are stained, clearly showing that the contributions terminate on the sole-plate of the parent ending. In Fig. d the contribution arises from the terminal node.
- e) A T1 end-plate (left) receives a nodal sprout which arises from the terminal node and ends among the axon terminals of the parent ending. A T2 ending (right) receives a contribution (c.).
- f) Terminal spray of motor end-plates. The two lower end-plates receive contributions with thickened axons, considered as indicating that myelination is occurring (my.c.). The two upper end-plates are simple T1 endings.



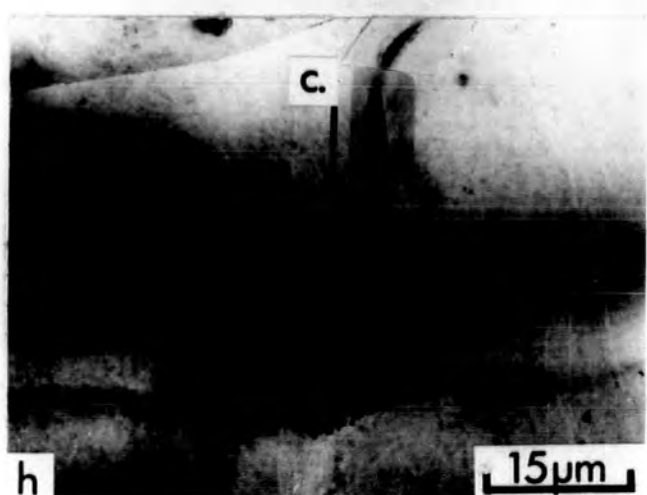
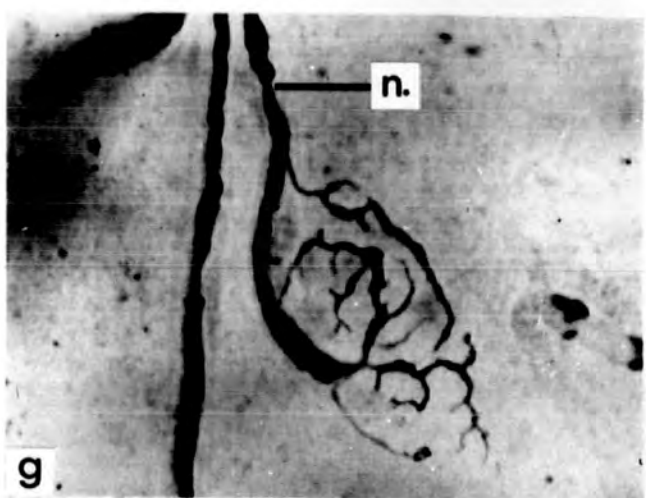
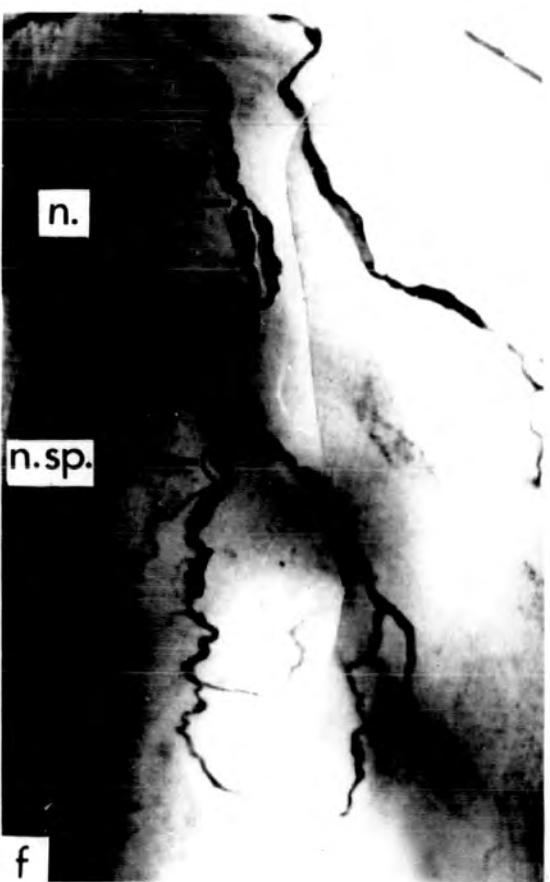
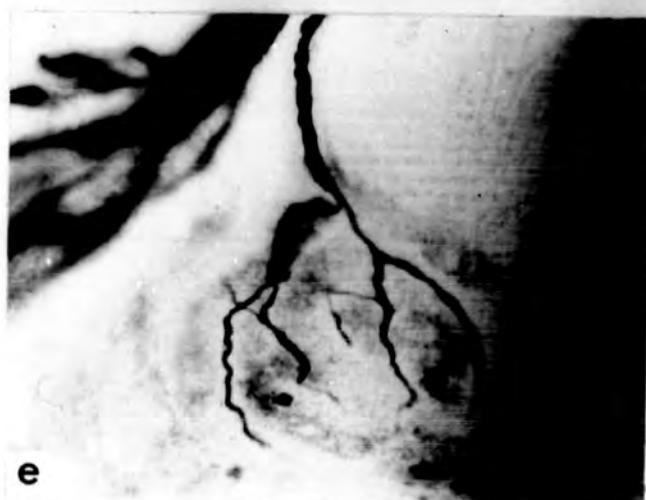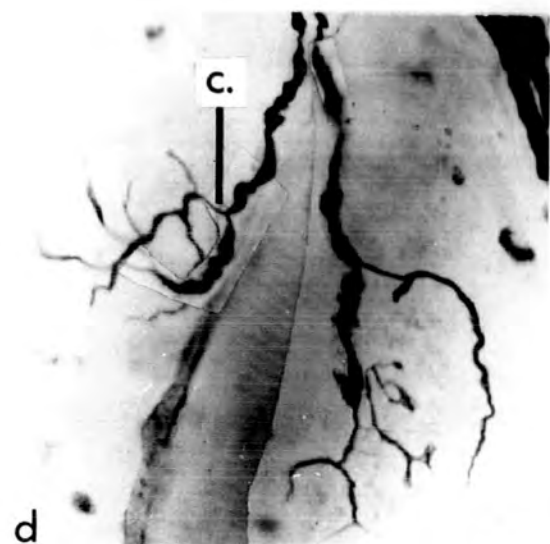
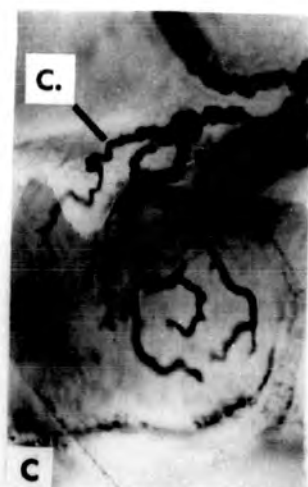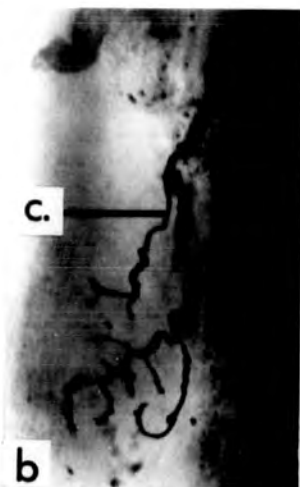
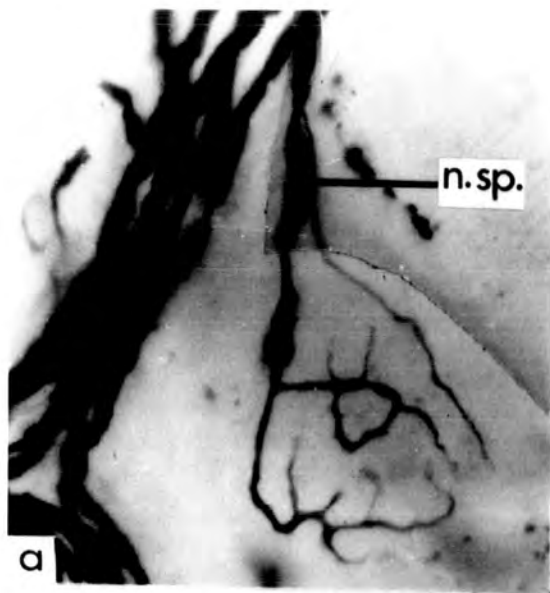
21 SEP 1972
LIBRARY

PLATE VII. Growth configurations from the PDQ muscles
of young adult cats

The ending in Fig. c is from a muscle denervated 24hr before staining; the other endings are from unoperated animals. All the figures are to the same scale.

- a) The T1 end-plate receives a nodal sprout (n.sp.) that ends in a fine taper close to the axon terminals of the parent ending.
- b) T1 end-plate receiving a contribution (c.).
- c) T2 ending receiving a contribution (c.) which shows localised thickening, interpreted as myelination.
- d) The end-plate to the left receives a contribution (c.) that forms more axon terminals than the parent ending. The axon terminals of the parent ending and the contribution are intermingled. The end-plate to the right receives an 'early' contribution that forms only two extremely fine axon terminals.
- e) T1 end-plate with a contribution that forms the same number of axon terminals as the parent ending.
- f) T2 end-plate with a nodal sprout (n.sp.) which arises from a node (n.) distal to the bifurcation of the terminal axon.

Contd.



21 SEP 1972
LIBRARY
21 SEP 1972
LIBRARY

- g) T1 end-plate receiving a contribution which arises from the terminal node (n.) and forms very few axon terminals.
- h) The contribution (c.) forms many more axon terminals than the parent ending.

PLATE VIII. (i) End-plates from the soleus muscle of a normal young adult cat (C254)

a - g) The end-plates are of a generally simpler and coarser appearance than those of PDQ (Plates I - V). Figure (e) shows a collateral end-plate formed by non-myelinated outgrowths from a node (x750).

(ii) End-plates and muscle fibres from teased histochemical preparations

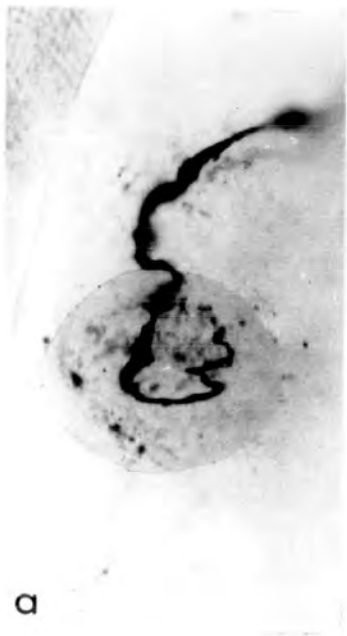h) Sub-neural apparatus (SNA) of a PDQ muscle of a new-born kitten. The SNA are much smaller and simpler than those of the adult (cf. i - l) although some differentiation is distinguishable. Teased AChE preparation (x180).

Figures i - j illustrate examples of SNA and muscle fibres from a combined AChE and SDH preparation of peroneal muscles of a normal young adult cat (x500).

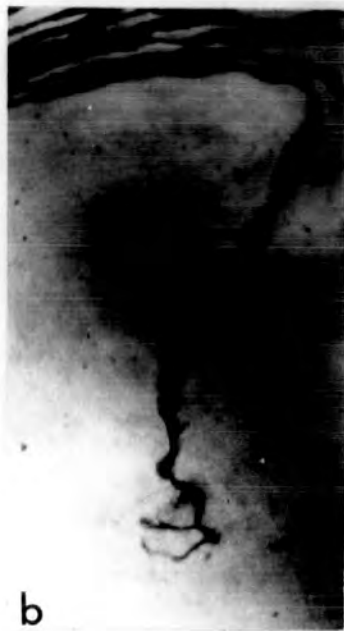i) The uppermost muscle fibre is of intermediate SDH activity, the second and lowest fibres are of high SDH activity (dark). A fibre of low activity (light) is also shown.

j) SNA of a muscle fibre of low SDH activity. It is divided into sub-units.

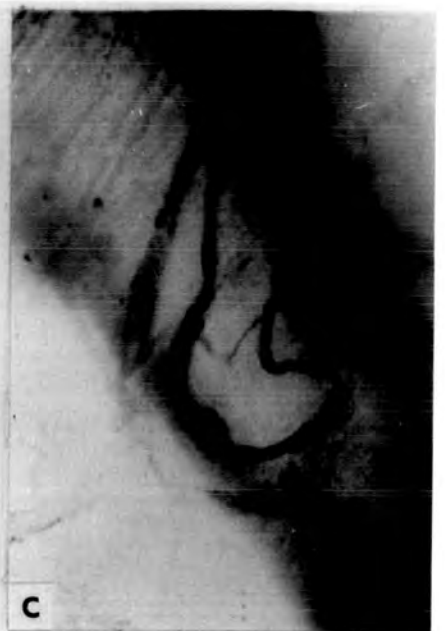Contd.



a



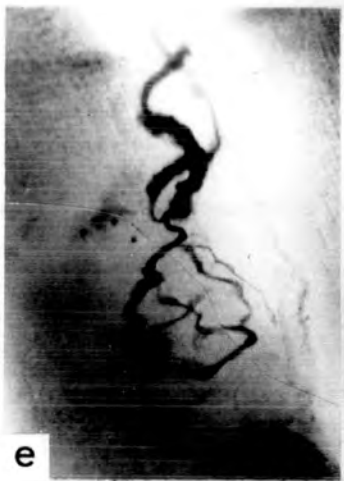b



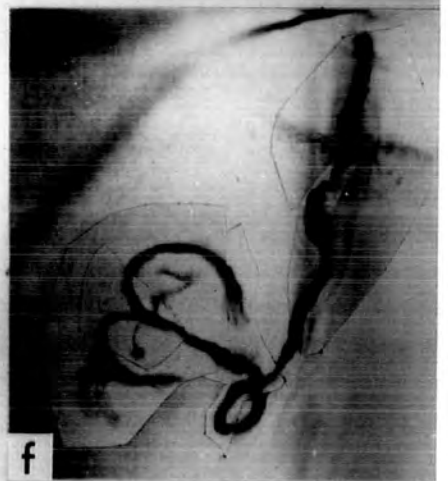
c



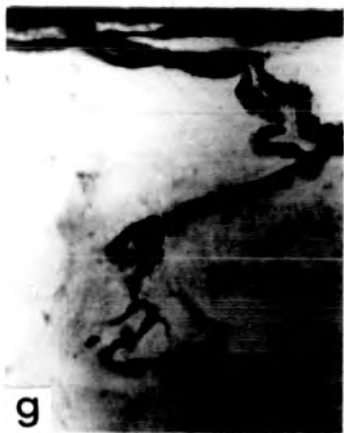d



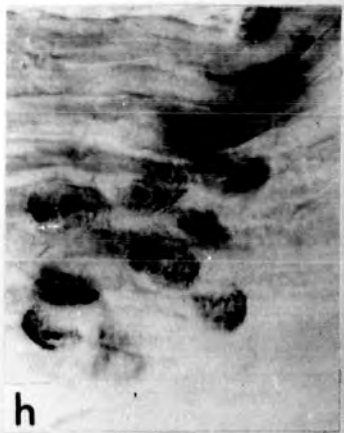e




f



g



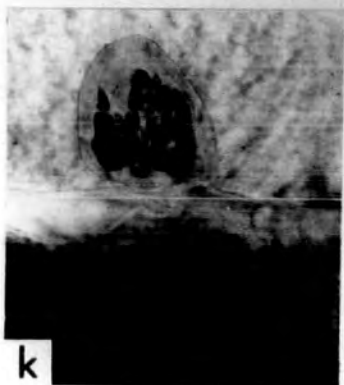
h




i



j



k



l


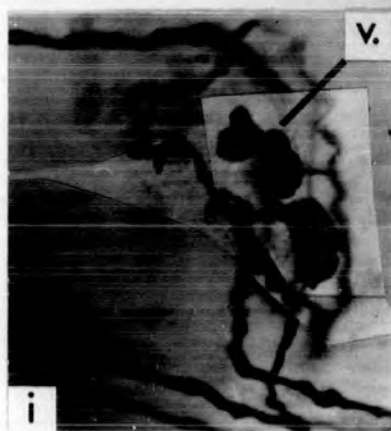
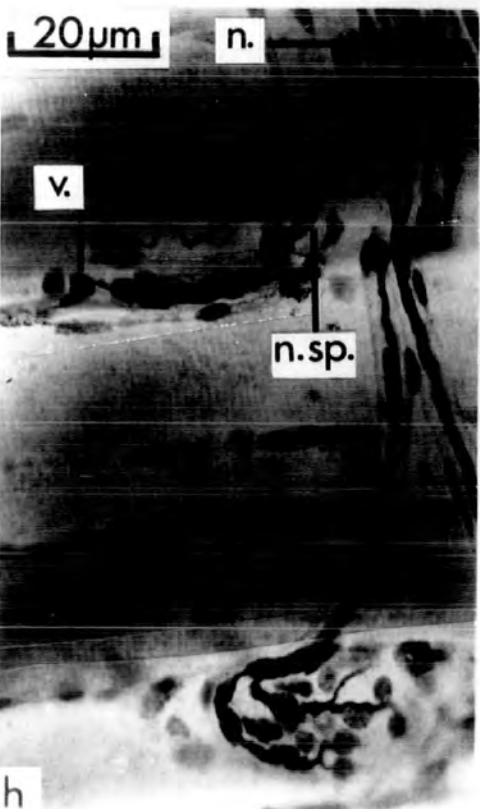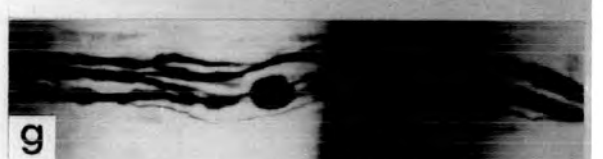
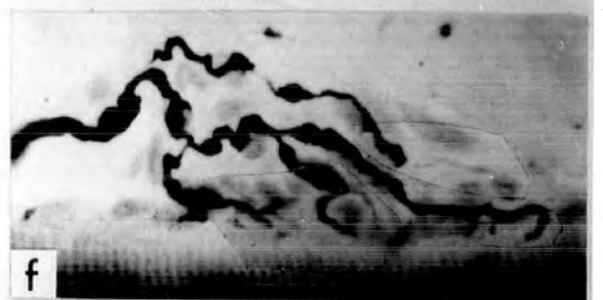
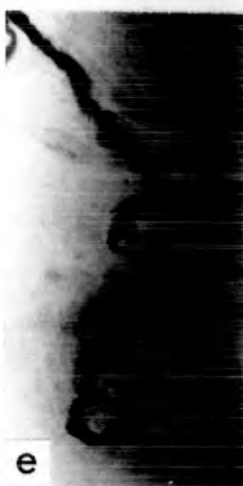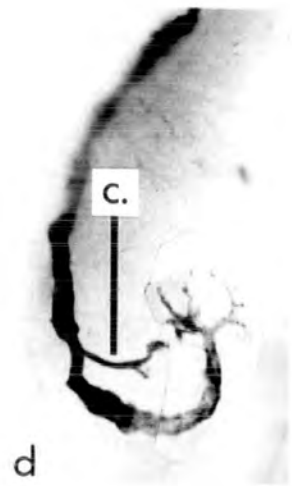
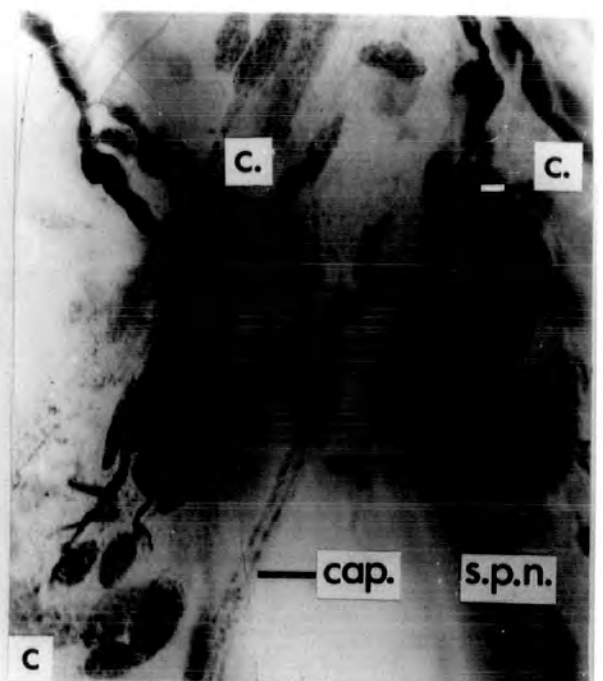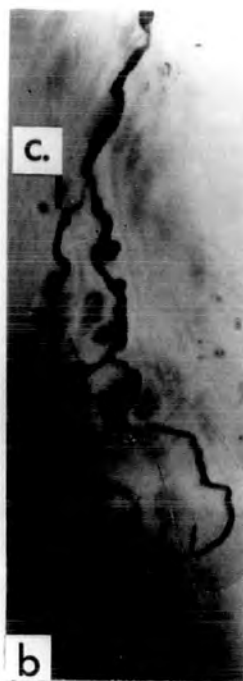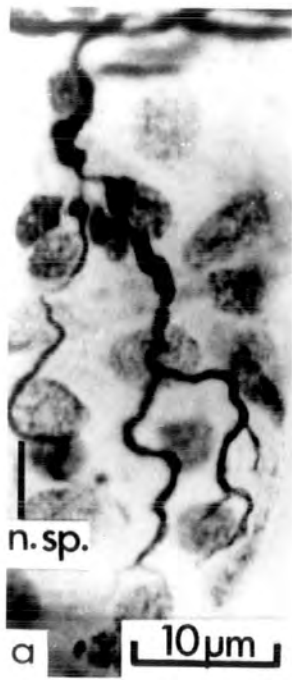21 SEP 1972
LIBRARY

- k) SNA of light (upper) and intermediate (lower) muscle fibres. The latter is more compact.
- l) SNA of light (upper) and dark (lower) muscle fibres. The latter is seen in profile (arrow) and is small and dense.

PLATE IX. Motor end-plates from muscles of a ten year
old cat (C294)

- a) T1 end-plate receiving a nodal sprout (n.sp.), which arises from the terminal node. The numerous sole-plate nuclei are stained, clearly showing that the sprout ends on the sole-plate of the parent ending (PDQ).
- b) T2 ending receiving a contribution (c.) with slight thickening proximally. The terminals of the contribution lie among those of the parent ending (PDQ).
- c) Two end-plates with contributions (c.) which show the thickening of their axons, considered as indicating myelination. The end-plate to the left has two contributions, one from each of the last two nodes. To the right, the axon terminals of the contribution are among those of the parent ending. Sole-plate nuclei and a capillary are visible (PDQ).
- d) A T1 end-plate in the middle phase of degeneration. The terminals of the contribution (c.) are also swollen (PDQ).
- e) Soleus end-plate with the inflated axon terminals of the middle phase of degeneration.
- f) T4 end-plate in profile. The outline of the eminence of Doyere is visible and all the axon terminals lie within it (PDQ).

Contd.



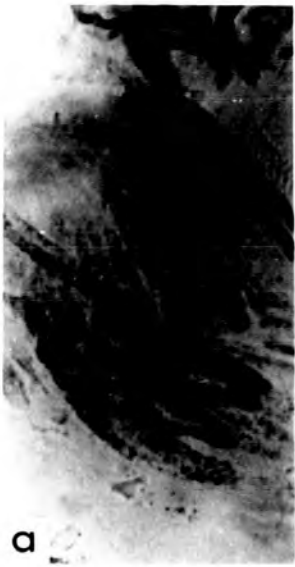21 SEP 1972
JFK

- g) A vesicular axonic swelling on a small intramuscular nerve trunk (PDQ).
- h) A terminal axon branches at a node (n.) giving rise to two end-plates. The upper T1 end-plate receives a bi-furcating nodal sprout (n.sp.) which ends in two vesicular axonic swellings (v.). The lower collateral end-plate is of the T2 form and the two branches clearly end on the same sole-plate (PDQ).
- i) Vesicular axonic swelling (v.) on a coiled terminal axon which forms a normal T1 end-plate (PDQ).
- j) A T2 end-plate with an ultraterminal sprout (u.sp.) which ends in a double vesicular axonic swelling (v.), a short distance from the parent ending (PDQ).

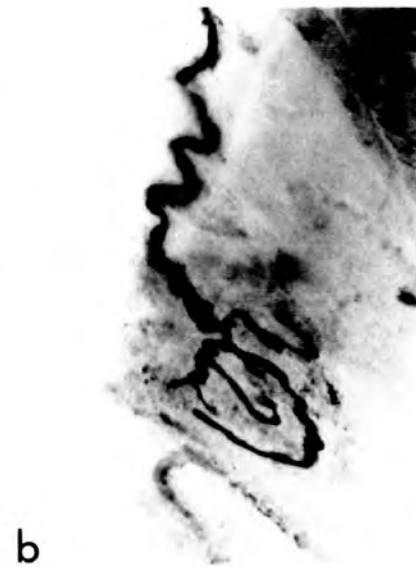PLATE X. End-plates from the soleus muscle of an 18 year
old cat (C296)

All to the same scale.

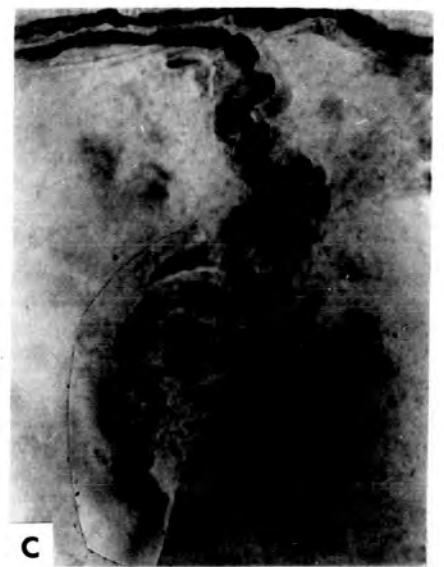- a - b) T1 end-plates of similar appearance to those of young adult muscles.
- c) T2 end-plate with short, coarse axon terminals.
- d - e) T1 end-plates with few axon terminals.
- f) T2 end-plates of similar appearance to those of young adult muscles.
- g) T1 end-plate receiving a thickened contribution (c.) which arises from a proximal node (n.). The axon terminals are few and short (cf. Fig. f).
- h) Two T2 end-plates receiving contributions (c.). In the case of the end-plate to the left, the axon terminals of the contribution lie among those of the parent ending.



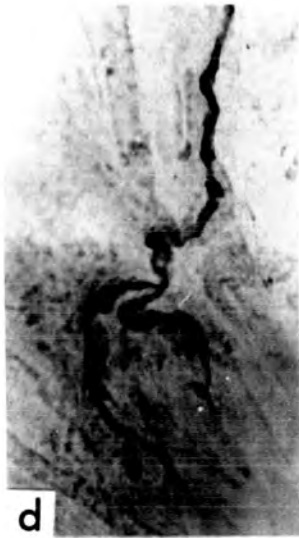a



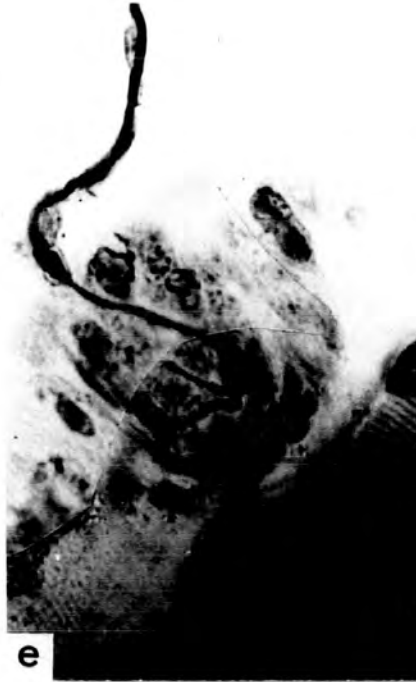b



c



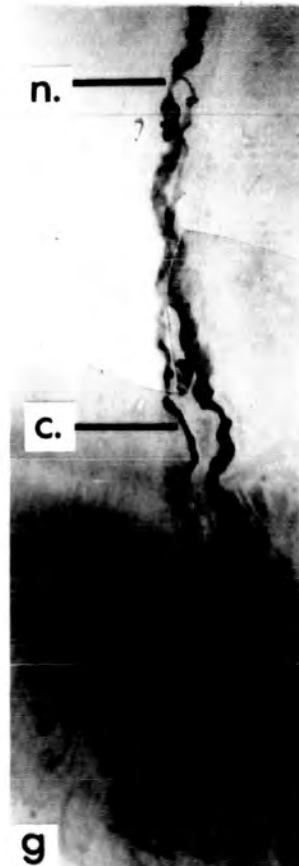d



e



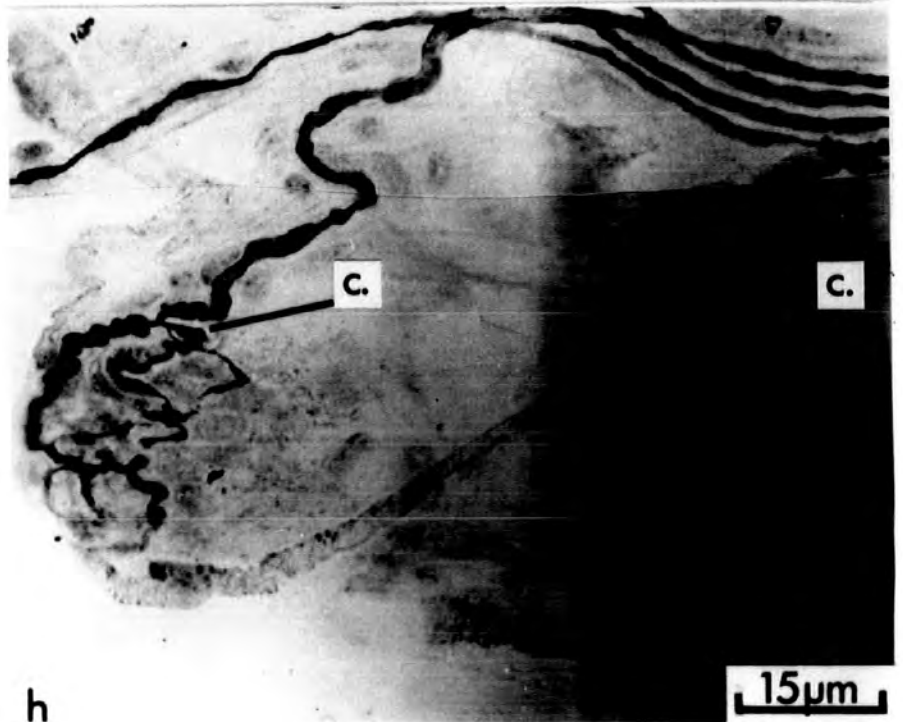
f



n.

c.

g



h

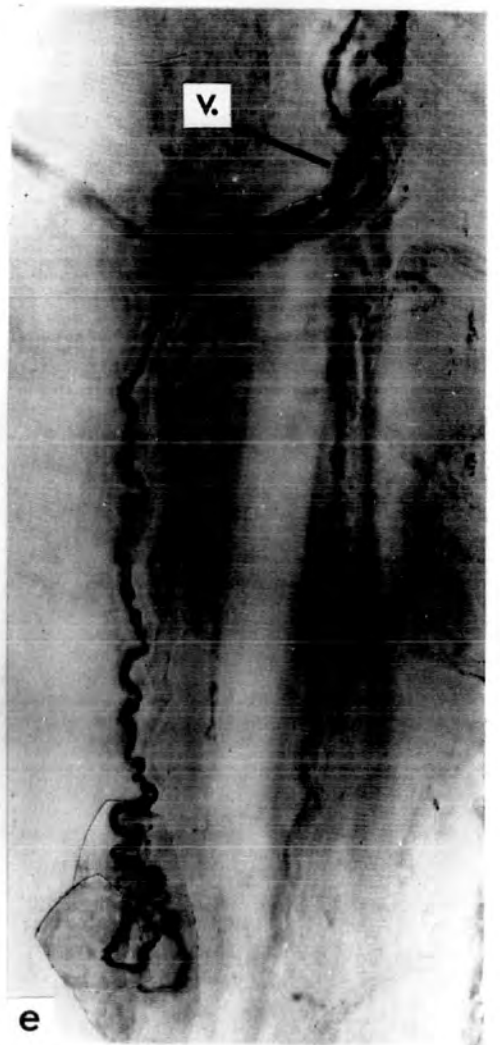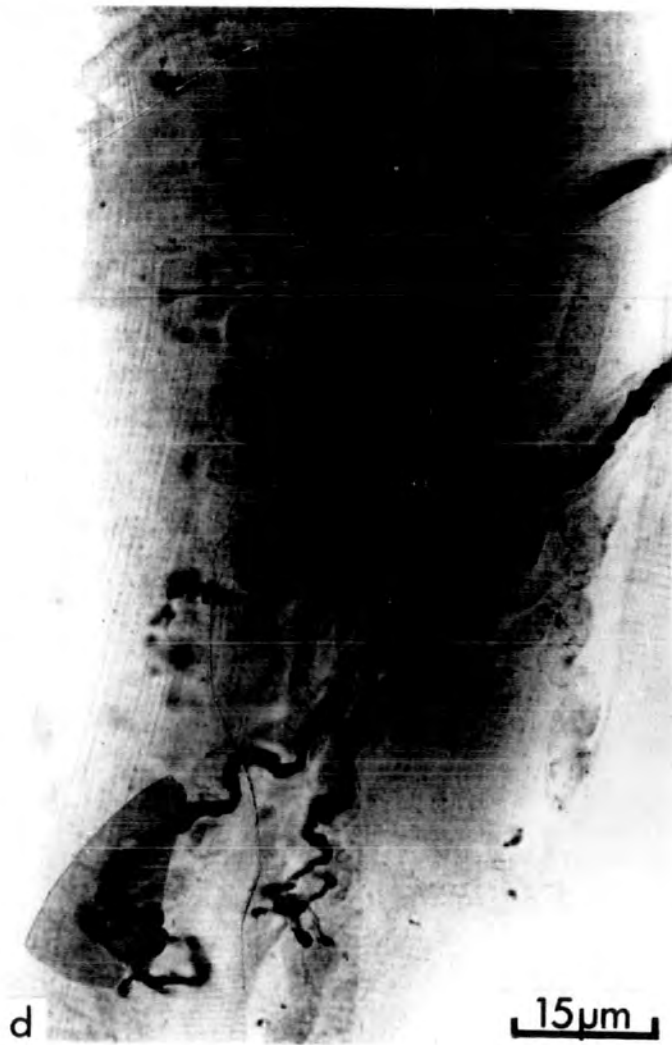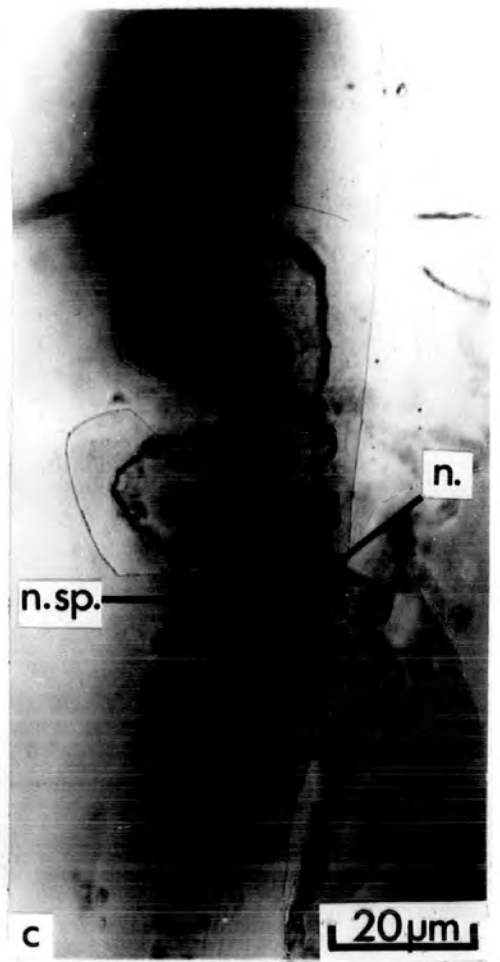
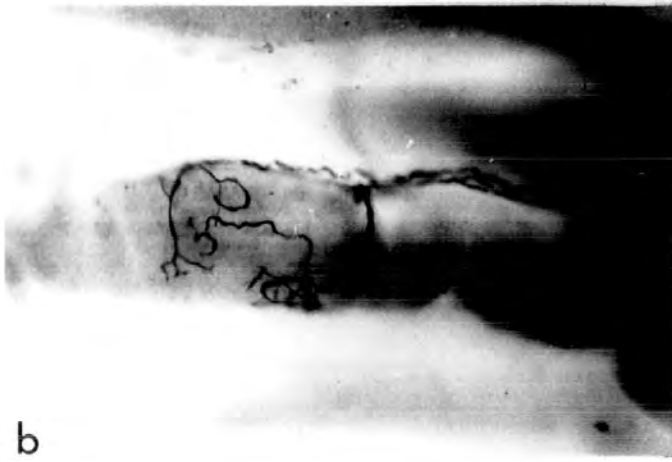
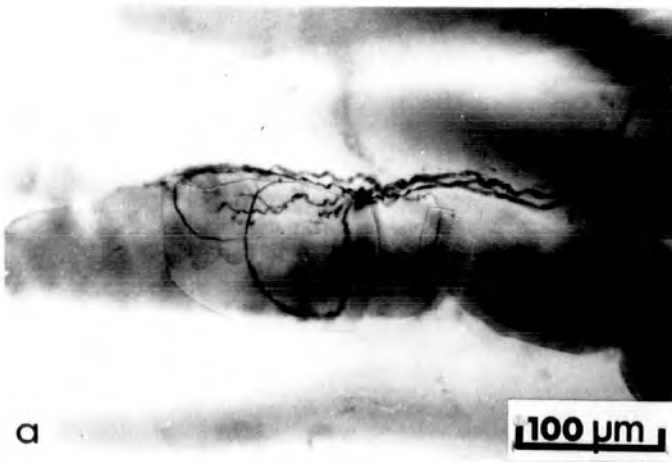
15µm

UNIVERSITY
OF
21 SEP 1972
LIBRARY

PLATE XI. End-plates from the soleus muscle of an 18 year
old cat (C296)

Figures a, b are to the same scale. Figures c and e are to the same scale as Figure d.

- a - b) The upper and lower surfaces of a single muscle fibre are shown separately to illustrate the complex ramifications of the ending which pass round the muscle fibre. The terminal axon forms three myelinated branches.
- c) A nodal sprout (n.sp.) arises from the terminal node (n.) and passes beyond the sole-plate of the parent ending and wanders over the surface of the muscle fibre. A camera lucida drawing of this ending is shown in Figure 9.
- d) The upper ending receives a contribution which is apparently myelinating. The axon terminals of the parent ending have a stubby appearance. The lower (T2) ending has fewer coarse axon terminals.
- e) A terminal axon bears a vesicular axonic swelling (v.). The end-plate does not differ in appearance from other end-plates of the same muscle.



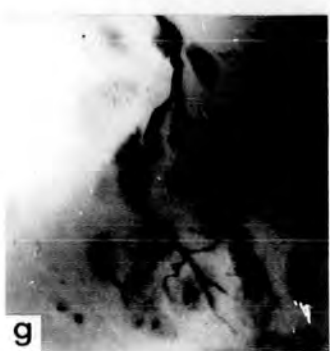
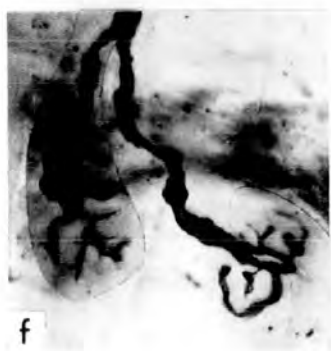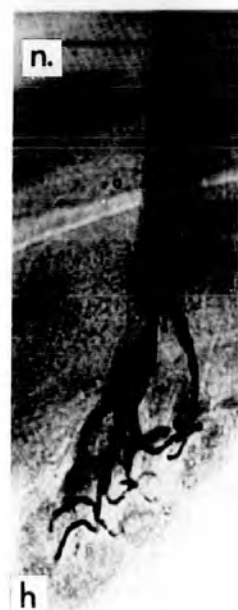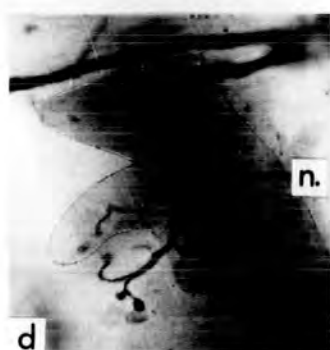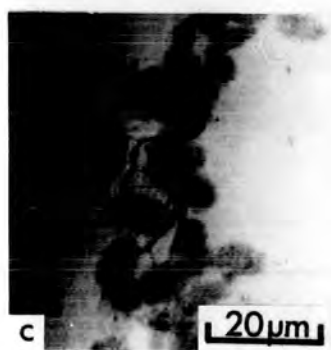
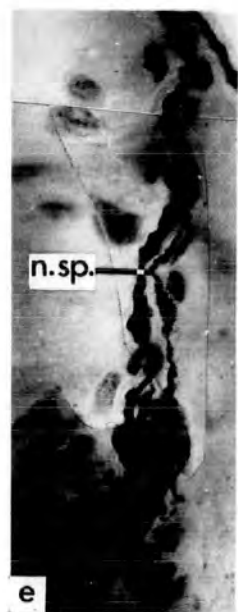
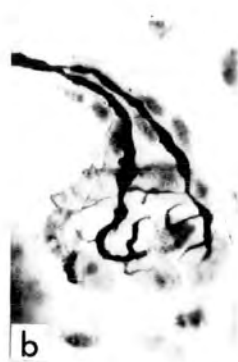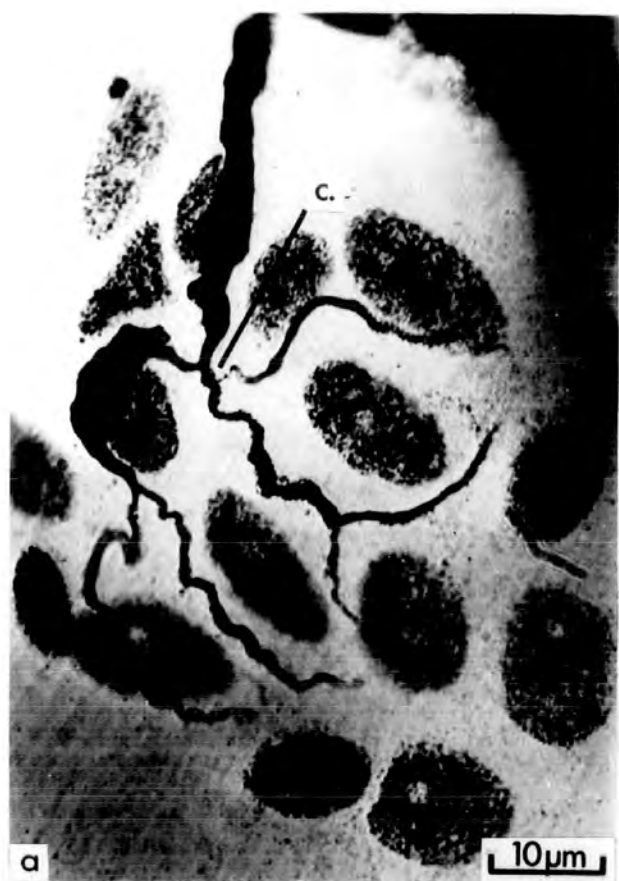AMERICAN OVERSEAS
LIBRARY
21 SEP 1972

PLATE XII. Motor end-plates from a hypertrophied soleus
muscle (C306)

Figure (a) was photographed with an oil immersion lens; the remainder are to the same scale.

- a) The terminal axon forms a short, branched contribution (c.), which greatly increases the total area of the end-plate. The myelin sheath distal to the node from which the contribution arises is clearly visible. The numerous sole-plate nuclei are well stained.
- b) T2 end-plate with numerous fine axon terminals.
- c) Simple T1 ending. The axon terminals are longer and more delicate than those commonly found in the normal soleus.
- d) A sprout and a contribution arise from the terminal node (n.).
- e) A T2 end-plate receives a long nodal sprout arising from a relatively proximal node.
- f) Two end-plates with the slightly swollen axon terminals characteristic of the early phase of degeneration. (These endings are not collateral, as may appear from the proximity of their terminal axons.)

Contd.



- g) A T2 end-plate with numerous very fine axon terminals.
- h) T4 end-plate. Three of the myelinated branches of the terminal axon arise from the terminal node, while the fourth arises from a more proximal node (n.).

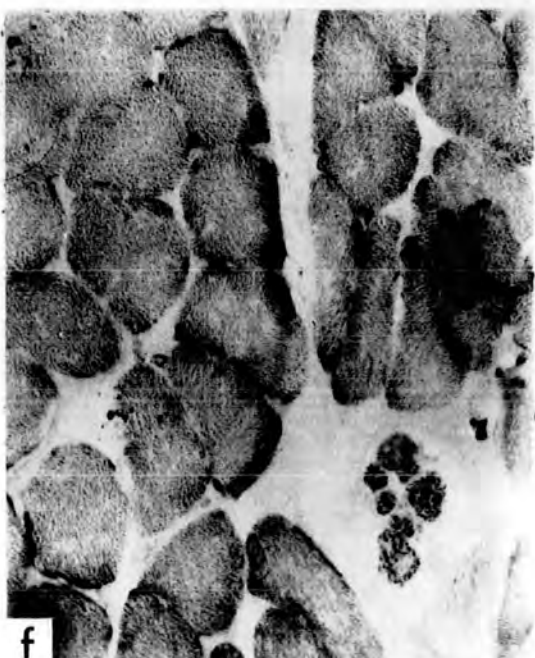
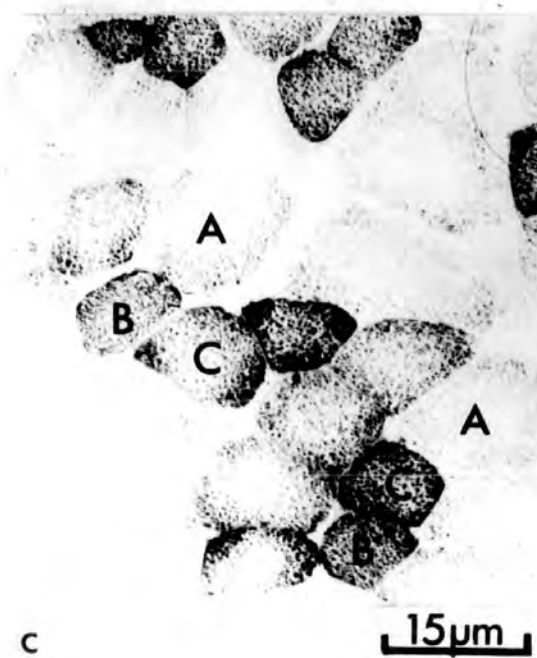
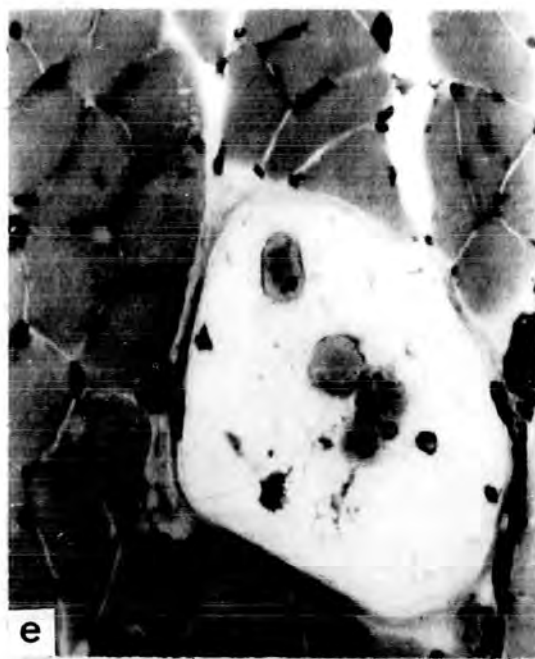
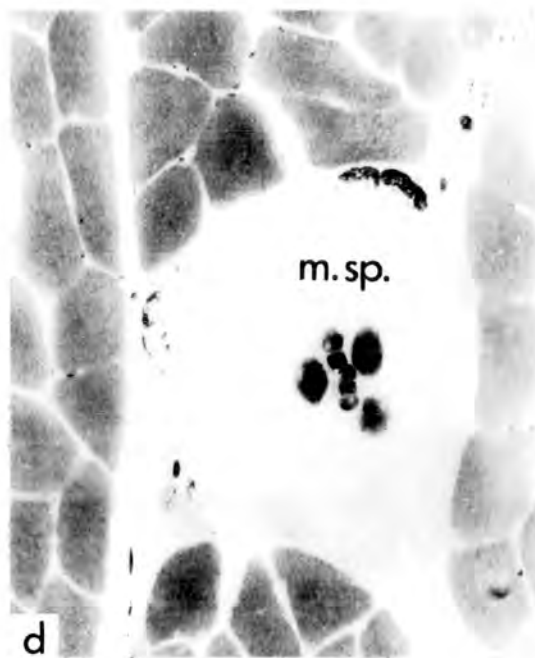
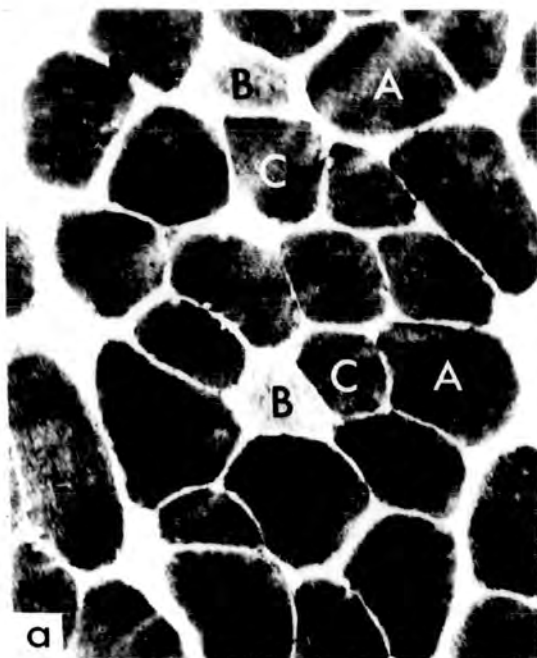
PLATE XIII. Histochemistry of PDQ and soleus muscle fibres

The serial sections shown in Figs. a - c are from PDQ, and those in Figs. d - f from soleus. All to the same scale.

Figures a and d, b and e, c and f, are stained to show the activity of Pase, ATPase and SDH, respectively.

There are three fibre types in PDQ :
A fibres with a low SDH activity and high Pase and ATPase activities; B fibres with the reciprocal pattern of enzyme activity; and C fibres with a high activity for all three enzymes.

The soleus fibres all have the same enzyme profile; low for both phosphorylytic enzymes and high with SDH. The distribution of the diformazan granules (SDH) differs from that of the B fibres of PDQ. Some intrafusal fibres of the muscle spindle (m.sp.), connective tissue and capillaries show a positive reaction with the phosphorylytic enzymes.

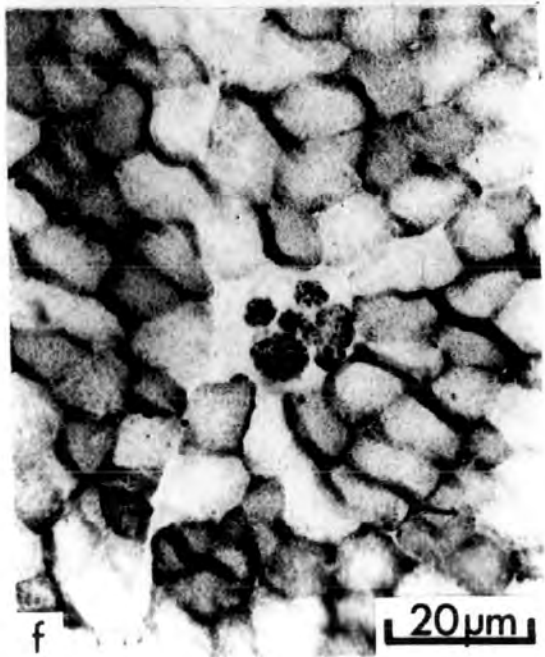
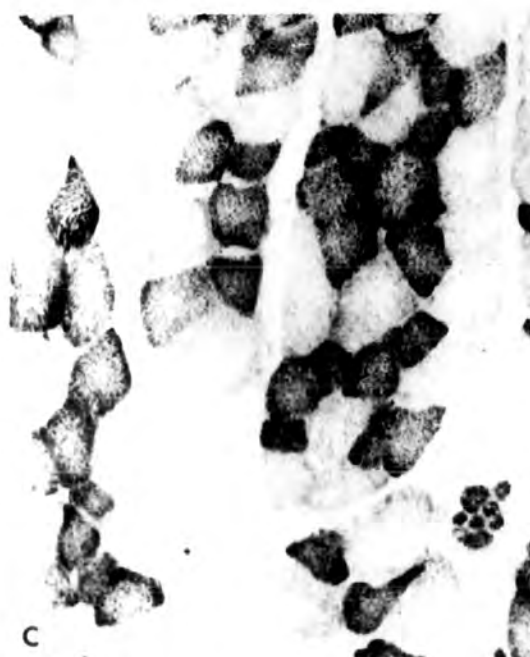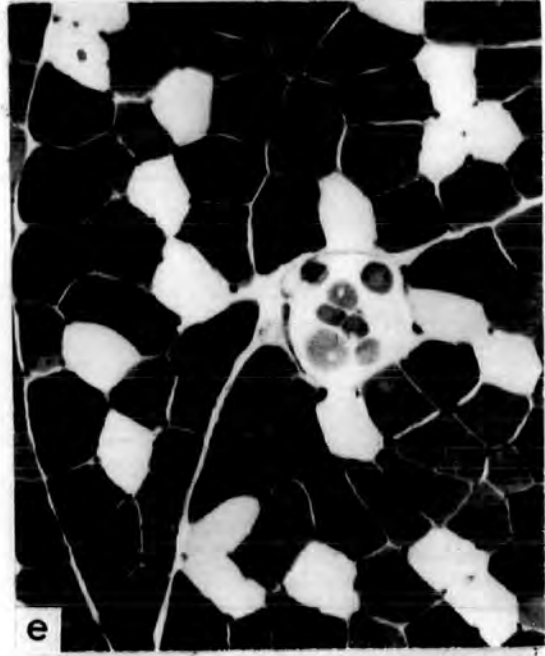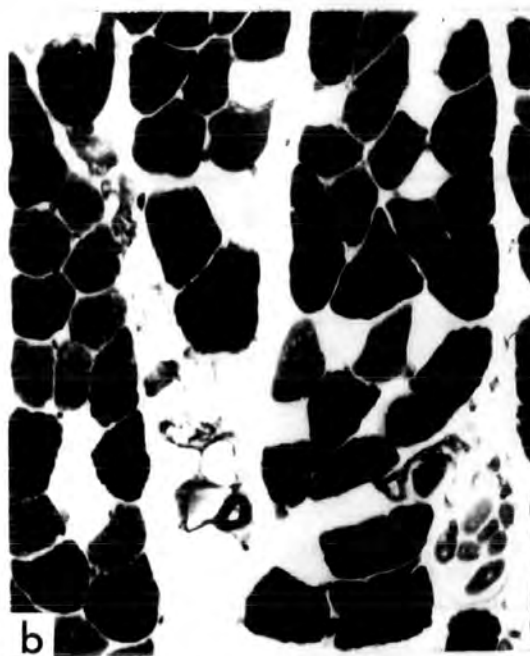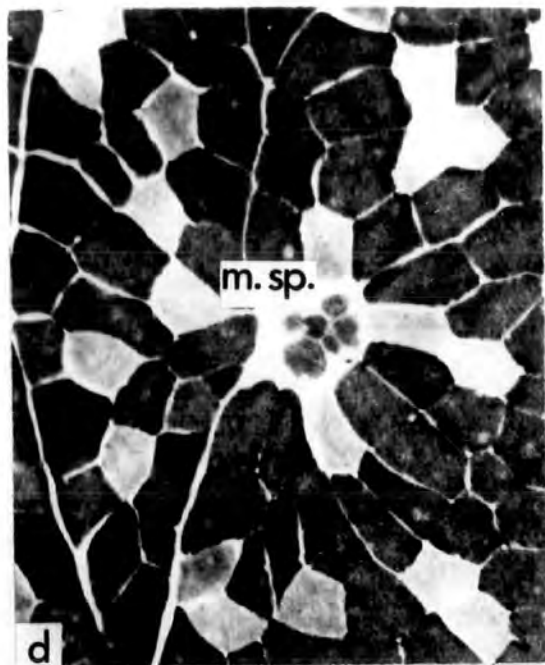


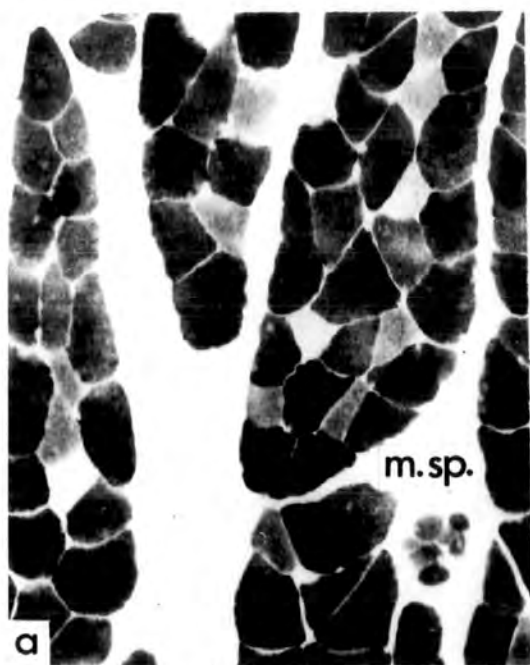UNIVERSITY OF CALIFORNIA
ORIGINALS
21 SEP 1972
RECORDS
LIBRARY

PLATE XIV. Histochemistry of PB and PL muscle fibres

The serial sections shown in Figs. a - c are from PB, and those in Figs. d - f from PL. All to the same scale.

The activities of Pase, ATPase and SDH are shown in a and d, b and e, c and f, respectively. The same three fibre types seen in PDQ (Plate XII) are present. A muscle spindle (m.sp.) is included for comparison.

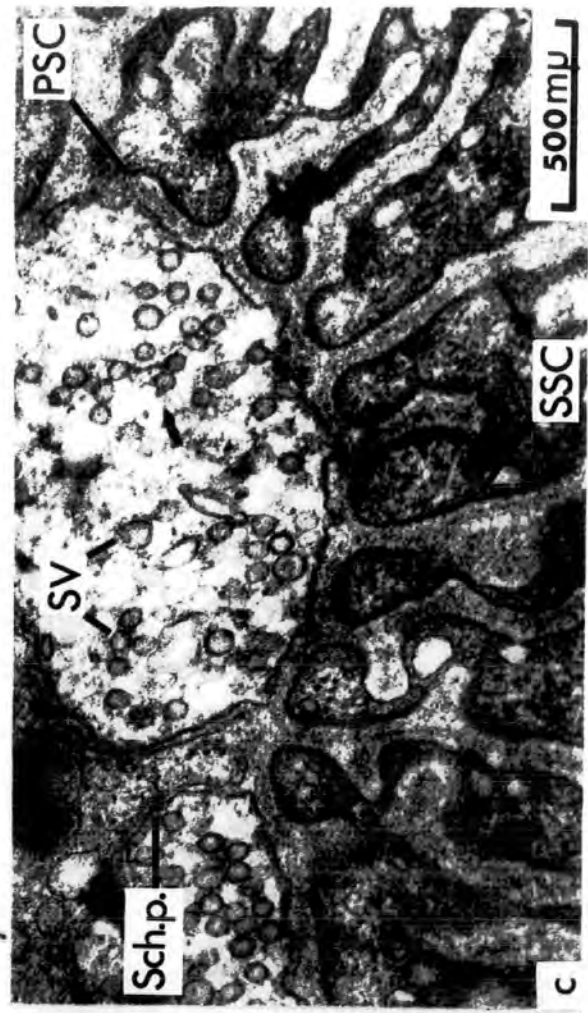
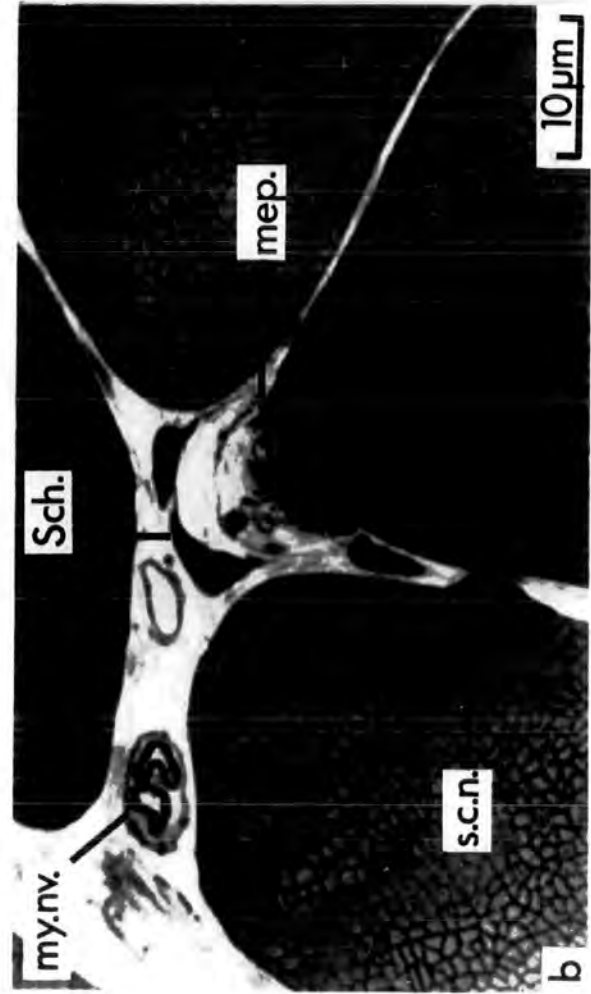
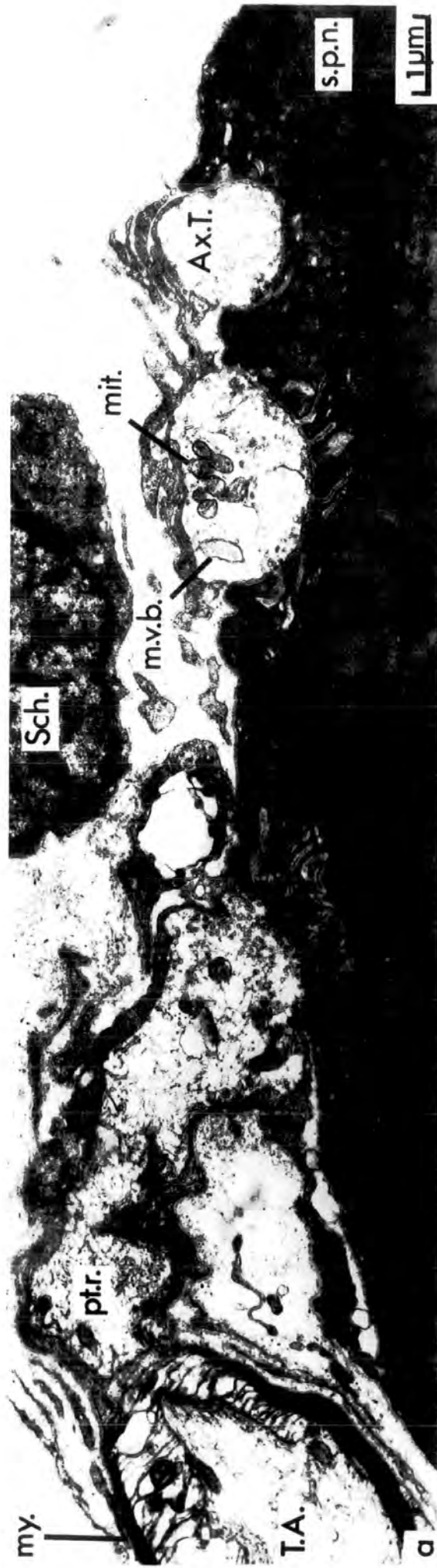


CONFIDENTIAL
21 SEP 1972
LONDON
L10254

PLATE XV. Ultrastructure of end-plates from the PDQ muscle
of a young adult cat (C298)

- a) Low power electron micrograph of a motor end-plate. On the left of the figure is the most distal portion of the terminal axon (T.A.). The myelin sheath (my.) ends and there is a short preterminal region (pt.r.) continuous with an axon terminal. The nucleus of a Schwann cell (Sch.) is present above the axon terminals (Ax.T.). Mitochondria (mit.) are present in the axon terminals. The middle axon terminal contains a multivesicular body (m.v.b.). At one edge of the ending is a sole-plate nucleus. The secondary synaptic clefts are few and short.
- b) Light micrograph (oil immersion) of a thin (approximately 1 μ m) section stained with toluidine blue. Parts of the profiles of four muscle fibres are visible as well as a motor end-plate (m.e.p.) and a myelinated nerve (my.nv.). Two Schwann cell nuclei (Sch.) and investing Schwann cell processes can be distinguished above the end-plate. An adjacent muscle fibre has a satellite cell nucleus (s.c.n.) with a prominent dark centriole.

Contd.



c) High-power electron micrograph of part of a motor end-plate. Two axon terminals are separated by a Schwann cell process (Sch.p.). The axon terminals contain numerous synaptic vesicles (SV). The primary (PSC) and secondary synaptic clefts (SSC) are clearly visible and are more numerous and deeper than those in Fig. a. (1 μ = 1nm).

29 SEP 1972
LIB