

## Durham E-Theses

---

### *A study of receptors in jaw muscles of the rat and other vertebrates*

Saed, Hassan Hantosh

#### How to cite:

---

Saed, Hassan Hantosh (1989) *A study of receptors in jaw muscles of the rat and other vertebrates*, Durham theses, Durham University. Available at Durham E-Theses Online:  
<http://etheses.dur.ac.uk/6565/>

#### Use policy

---

The full-text may be used and/or reproduced, and given to third parties in any format or medium, without prior permission or charge, for personal research or study, educational, or not-for-profit purposes provided that:

- a full bibliographic reference is made to the original source
- a [link](#) is made to the metadata record in Durham E-Theses
- the full-text is not changed in any way

The full-text must not be sold in any format or medium without the formal permission of the copyright holders.

Please consult the [full Durham E-Theses policy](#) for further details.

**A STUDY OF RECEPTORS IN JAW MUSCLES  
OF  
THE RAT AND OTHER VERTEBRATES**

A thesis presented in candidature for the  
degree of  
Doctor of Philosophy

by

Hassan Hantosh Saed, B.V.M. & S. (Baghdad),  
Department of Biological Sciences, University of Durham.

The copyright of this thesis rests with the author.  
No quotation from it should be published without  
his prior written consent and information derived  
from it should be acknowledged.

Durham, September 1989.



- 6 JUN 1991

Dedicated to the memory of my late mother

### ACKNOWLEDGEMENTS

I am indebted to many people who have given substantial assistance in the preparation of this work.

I wish particularly to express my gratitude to my first supervisor, Professor D. Barker, for his constant advice, encouragement and guidance throughout the experimental phase of this study and until his retirement. I also wish to thank Dr. R.W. Banks, my second supervisor, for the same reasons and also for his kind encouragement throughout the writing-up stage. I am grateful to Dr. M.J. Stacey for his invaluable advice and discussions, particularly with respect to the silver-stained material. My thanks are also due to Dr. A. Milburn for useful discussions, and to Dr. A. Rowleron for carrying out the immunohistochemistry.

My gratitude goes to Mrs. A.C. Richardson for introducing me to the use of the electron microscope and other histological techniques. I should also like to acknowledge the technical assistance of Mr. J. Warner, Mrs. M. Earl, Mr. P. Hunter, and Mrs. M. Edge. My thanks are also due to Mr. D. Hutchinson for his skilled photographic assistance, to Mr. P. Hughes for his help with the English of the manuscript, and to Miss P. Carse for her meticulous typing of it.

I am indebted to my cousins Kadhim M. and Abd M. AL-Rikabi for their encouragement and for directing me along the right path in life. Also to my relatives Mr. Abbas Y. AL-Rikabi and Mr. Jawad K. Idris for financial support, and to all my other relatives and friends for moral support.

I should like to thank my wife, Samana, and my sons for their patience throughout my period of study.

Finally, I am greatly indebted to the Ministry of Higher Education and Scientific Research of Iraq, who were responsible for the financing of this study.

Some of the material contained in this thesis has been published in the following paper and abstracts:

Banks, R.W., Barker, D., Saed, H. & Stacey, M.J. (1988). Innervation of muscle spindles in rat deep masseter. *J. Physiol. (Lond.)* 406, 161P.

Barker, D. & Saed, H. (1987). Adrenergic innervation of rat jaw muscles. *J. Physiol. (Lond.)* 391, 114P.

Rowlerson, A., Mascarello, F., Barker, D. & Saed, H. (1988). Muscle-spindle distribution in relation to the fibre-type composition of masseter in mammals. *J. Anat.* 161, 37-60.

TABLE OF CONTENTS

Acknowledgements		i
List of Publications		ii
Table of Contents		iii
Abstract		viii
Chapter I	General introduction	1
Chapter II	Materials and methods	7
	I. Animals used	7
	a. Rat	7
	b. Fish	7
	c. Newt	8
	d. Frog	8
	II. Techniques for muscle removal	8
	a. Rat	8
	b. Fish	10
	c. Amphibian	10
	III. Tissue preparation	10
	a. Cryo-fixation (rat)	10
	b. Perfusion and plastic embedding	11
	1. Rat perfusion	11
	2. Plastic embedding	12
	c. Formal-saline fixation and wax embedding	13
	IV. General staining methods	13
	a. Weigert's iron haematoxylin and van Gieson's stains	13
	b. Sudan black B stain	14
	1. Sudan black B in 70% alcohol	14
	2. Sudan black B in propylene glycol	14
	c. Toluidine blue	15

V.	Special histological techniques and methods	15
	a. The demonstration of the adrenergic innervation	15
	1. Staining method	15
	2. Searching and counting techniques for nerve fibres innervating spindles and extrafusal muscle fibres	16
	2.1. Searching and counting method for muscle spindles	16
	2.2 Searching and counting method for extrafusal muscle fibres	17
	b. The demonstration of nerve endings	17
	1. The Holmes' silver-on-the-slide method	17
	2. The modified de Castro method and teasing of muscle blocks, especially the anterior spindle-cluster	18
VI.	Techniques and methods for muscle fibre histochemistry	19
	a. Cryostat sectioning	19
	b. Staining methods	20
	1. Acid-stable actomyosin adenosine tri-phosphatase	20
	2. Alkaline-stable actomyosin adenosine tri-phosphatase	21
	3. Succinate dehydrogenase	22
	4. Antibody-specific methods for type I and type IIA fibres	22
VII.	Techniques and methods for electron microscopy	23
	a. Sectioning on ultramicrotome	23
	b. Reconstruction of serially sectioned muscles	24
	1. Reconstruction of the anterior spindle-cluster from plastic sections	24
	2. Number and position of muscle spindles in deep masseter muscle	24
	3. Measurement of intrafusal muscle fibre parameters	25

	VIII. Technique for estimating muscle fibres in deep masseter and anterior digastric muscles	25
	a. Photography and montage	25
	b. Counting method	26
Chapter III	The morphology of rat jaw muscles	27
	A. Introduction	27
	B. Results	31
	1. Pattern of branching of masseteric nerve	31
	2. Number and distribution of muscle spindles	31
	3. Muscle fibre counts in deep masseter and digastric muscles of 6-week-old male Wistar strain	32
	C. Discussion	37
Chapter IV	The adrenergic innervation of rat masseter and anterior digastric muscles	41
	A. Introduction	41
	B. Results	45
	1. Adrenergic innervation associated with spindles	45
	2. Adrenergic innervation associated with extrafusal muscle fibres of deep masseter and anterior digastric muscles	45
	2.1. Deep masseter muscle	46
	2.2. Left anterior digastric muscle	49
	C. Discussion	53
Chapter V	Fibre-type composition of rat masseter muscle	58
	A. Introduction	58
	1. Classification and nomenclature of muscle fibres	58
	2. Histochemistry of masseter muscle	61
	3. Histochemistry of intrafusal muscle fibres	65
	B. Results	70
	1. Extrafusal fibres of masseter muscle	70
	1.1. Superficial masseter	70
	1.2. Deep masseter	70
	2. Intrafusal fibres	72



C. Discussion	75
1. Extrafusal muscle fibres	75
2. Intrafusal muscle fibres	78
Chapter VI	
Structure and somatic innervation of muscle spindles in rat deep masseter muscle	81
A. Introduction	81
1. Intrafusal muscle fibres	82
2. Capsule, periaxial space and axial sheath	87
3. The sensory innervation	88
3.1. The primary endings and axons	88
3.2. The secondary endings and axons	90
4. The motor innervation	91
4.1. Types of fusimotor ending	92
i) The $\beta$ innervation, $p_1$ plates	92
ii) The $\gamma$ innervation, $p_2$ plates	92
iii) The $\gamma$ innervation, trail ending	92
B. Results	95
1. Structure and arrangement of muscle spindles in deep masseter muscle	95
2. Analysis of silver preparations	103
2.1. Number of spindles	103
2.2. The form of terminals	103
2.3. Diameters of afferent fibres and length of sensory endings	104
2.4. Branching and distribution of sensory endings	104
i) Deep masseter muscle	104
ii) Peroneus longus muscle	106
iii) Lumbrical and soleus muscles	109
2.5. Skeleto-fusimotor innervation, $\beta$ axons	109
C. Discussion	113
1. Types of intrafusal muscle fibre	113
2. The sensory innervation	118

Chapter VII	Muscle spindles in jaw muscles of other vertebrates	124
	A. Introduction	124
	B. Results	126
	1. Frog	126
	2. Newt	126
	3. Fish	126
	C. Discussion	127
Chapter VIII	General conclusion	129
References		132
List of Tables:		
	Table 1	9
	Table 2	35
	Table 3	36
	Table 4	47
	Table 5	48
	Table 6	50
	Table 7	51
	Table 8	62
	Table 9	63
	Table 10	69
	Table 11	74
	Table 12	83
	Table 13	96
	Table 14	99
	Table 15	100
	Table 16	102
	Table 17	105
	Table 18	107
	Table 19	108
	Table 20	110
	Table 21	111
	Table 22	112

### Abstract

The masseteric nerve supplying rat deep masseter muscle was traced from serial paraffin sections. The number of myelinated axons counted in a plastic transverse section close to its entrance into the muscle was 2120. Extrafusal muscle fibre counts of rat deep masseter (71,400 fibres) and anterior digastric (5,400 fibres) muscles have been performed and were found to be 2 to 3 times higher than Hiemae's count (1971). The number of muscle spindles in deep masseter ranged from 86 to 134 and were mostly distributed in an anterior cluster.

Using glyoxylic acid-induced fluorescence, the extrafusal muscle fibres of deep masseter and anterior digastric muscles were found to be adrenergically innervated, in the respective proportions of 40% and 55%. It was found that some spindle capsules (about one third) received such innervation at their equatorial region.

According to histo- and immunohistochemical reactions, the masseter muscle is uniformly composed of type IIA fibres, except for a small number of slow oxidative fibres which were restricted to spindle-cluster areas. Three types of intrafusal muscle fibre similar to those in rat hindlimb muscle were recognized.

The morphology of muscle spindles in deep masseter muscle was studied with light microscopy using serial plastic sections. The number of intrafusal muscle fibres was found to range from 2 to 7, usually one bag<sub>1</sub>, one bag<sub>2</sub> and 2-5 chain fibres. The lengths and diameters of the intrafusal muscle fibres and the capsules were obtained. The length of spindles ranged from 950 to 4000  $\mu\text{m}$  and that of capsules from 400 to 2600  $\mu\text{m}$ .

The innervation of anterior cluster muscle spindles in deep

masseter muscle and spindles in some hindlimb muscles of the rat was studied in teased, silver impregnated material. Analysis of the sensory innervation revealed the following unusual or unique features: a high number of afferents (1-6) innervating the sensory region of each spindle; some Ia axons branched to supply primary endings to two bag<sub>1</sub> fibres in two separate spindles; some other Ia axons branched to supply primary and secondary endings in the same spindle; and some group II axons branched to supply two secondary endings in the same spindle.

Some motor axons were found to be branched to supply small end plates to bag<sub>1</sub> fibres of some spindles in the anterior cluster, and therefore it is concluded here that some cluster spindles in deep masseter muscle receive dynamic  $\beta$  innervation.

A comparative study of the occurrence of muscle spindles in jaw-closing muscles of other vertebrates revealed that they are present in frog and absent from newt and salmon.

## CHAPTER I

### General Introduction

In the mammalian species each skeletal muscle is supplied with one or more nerves, each nerve containing both motor and sensory fibres. The somatic motor component consists of three types designated  $\alpha$ ,  $\beta$  and  $\gamma$  efferents (Figure A). The extrafusal muscle fibres are supplied by large myelinated axons ( $\alpha$ -efferents) at their middle region from motor neurons situated in the anterior horn of the spinal cord. Soon after the nerve enters the muscle mass, it breaks up into a plexus, which runs in the epi- and perimysial septa before reaching endomysial spaces around the muscle fibres. Each axon loses its myelin sheath as it approaches the vicinity of its terminal on an individual muscle fibre, which has the form of a specialised structure, the motor end plate. The nerve may branch extensively before making actual contact with muscle fibres. A single nerve may innervate one muscle fibre, but more commonly branches to innervate a group of muscle fibres of the same type. In this case, the single nerve and its motor endings and all muscle fibres innervated by it is called a motor unit. Another group of motor neurons with smaller myelinated axons ( $\gamma$ -efferents) run to supply muscle spindles exclusively at their polar region. Finally a third group of intermediate size ( $\beta$ -efferents) bifurcate and supply both extrafusal and intrafusal muscle fibres (Figure A). Their intrafusal motor endings are recognizable as small endplates called  $p_1$  plates (Barker, 1966, Emonet-Dénand, Laporte and Stacey, 1980).

According to Boyd and Davey (1968) and Stacey (1969) most of the axons supplying a muscle are sensory. The myelinated sensory fibres are divided into 3 groups according to their diameter: Group I

afferents range in diameter between 12 and 20  $\mu\text{m}$  and conduct at speeds of up to 100 m/sec. This group contains axons which terminate in muscle spindles as primary afferents (Ia fibres) as well as in tendon organs (Ib fibres). Group II afferents range in diameter between 4-12  $\mu\text{m}$  and have conduction velocities from 20-90 m/sec. This group includes the afferents from the secondary ending of the intrafusal muscle fibres of muscle spindles, and afferent fibres from other mechanoreceptors such as Pacinian corpuscles, paciniform corpuscles and free endings. The diameters of group III afferents range from 1 to 7  $\mu\text{m}$  and their conduction velocities from 12-30 m/sec. They terminate almost exclusively as free endings in muscle and include high-threshold mechanoreceptors, chemoreceptors and nociceptors. Most of the sensory axons are non-myelinated; according to Stacey (1969), all of the non-myelinated and some of the myelinated sensory axons terminate as free endings on blood vessels and in fat and connective tissue, whereas most of the remaining myelinated sensory axons are supplied to muscle spindles and tendon organs. A schematic diagram of the innervation of mammalian skeletal muscle is shown in Figure A.

In addition to the somatic sensory and motor axons, autonomic fibres of the sympathetic and parasympathetic systems are present. These are also unmyelinated nerve fibres ranging from 0.2  $\mu\text{m}$  to about 1.5  $\mu\text{m}$  in diameter and with conduction velocities from 0.3-1.6 m/sec.

In the past it was believed that no extrafusal muscle fibres received sympathetic innervation and that those axons that remained intact in the muscles after degeneration of somatic innervation following spinal-root section were supplied entirely to blood vessels (Hinsey, 1927). On the other hand it was known that muscle spindles are supplied with axons, having the ultrastructural appearance and fluorescent properties of sympathetic axons, although it remained a

possibility that these were vasomotor (Santini and Ibata, 1971; Banker and Girvin, 1971). The autonomic axons consist of varicose threads, the varicosities containing concentration of neurotransmitter vesicles.

Recent studies using fluorescent microscopy, silver staining and electron microscopy made on cat hindlimb muscles deprived of their somatic innervation reveal that some intrafusal and extrafusal muscle fibres are associated with autonomic innervation (Barker and Saito, 1981). The axons were seen to enter spindles either with the spindle nerve or from nearby perivascular nerves, and to be distributed to the capsule wall in the equatorial region and to the intrafusal muscle fibres in the polar regions (Figure B). Branches of an autonomic axon from the perivascular fibres were occasionally seen to be present, ending among extrafusal muscle fibres. The distance between varicosity and nearest intrafusal muscle fibre ranged from 0.08 to 1.20  $\mu\text{m}$  and nearest to extrafusal muscle fibre ranged from 0.05 to 1.10  $\mu\text{m}$ . Transmitter is released *en passage* from a large number of preterminal and terminal varicosities. Each varicosity is only partly enclosed by a Schwann cell leaving one surface exposed and in neuroeffective association with a muscle fibre. A schematic diagram of the sympathetic innervation is shown in Figure B.

The initial impetus for this study derives directly from the physiological observations made by Passatore and Filippi (1981 and 1982) who stimulated the cervical sympathetic nerve of anaesthetized and paralyzed rabbits and observed a short-latency decrease in the discharge of jaw-muscle spindles followed by a later increase in the discharge of the spindles. They concluded that there is a direct sympathetic action upon muscle spindles in jaw-elevating muscles. Then when Passatore, Grassi and Filippi (1985) stimulated the cervical

**A**

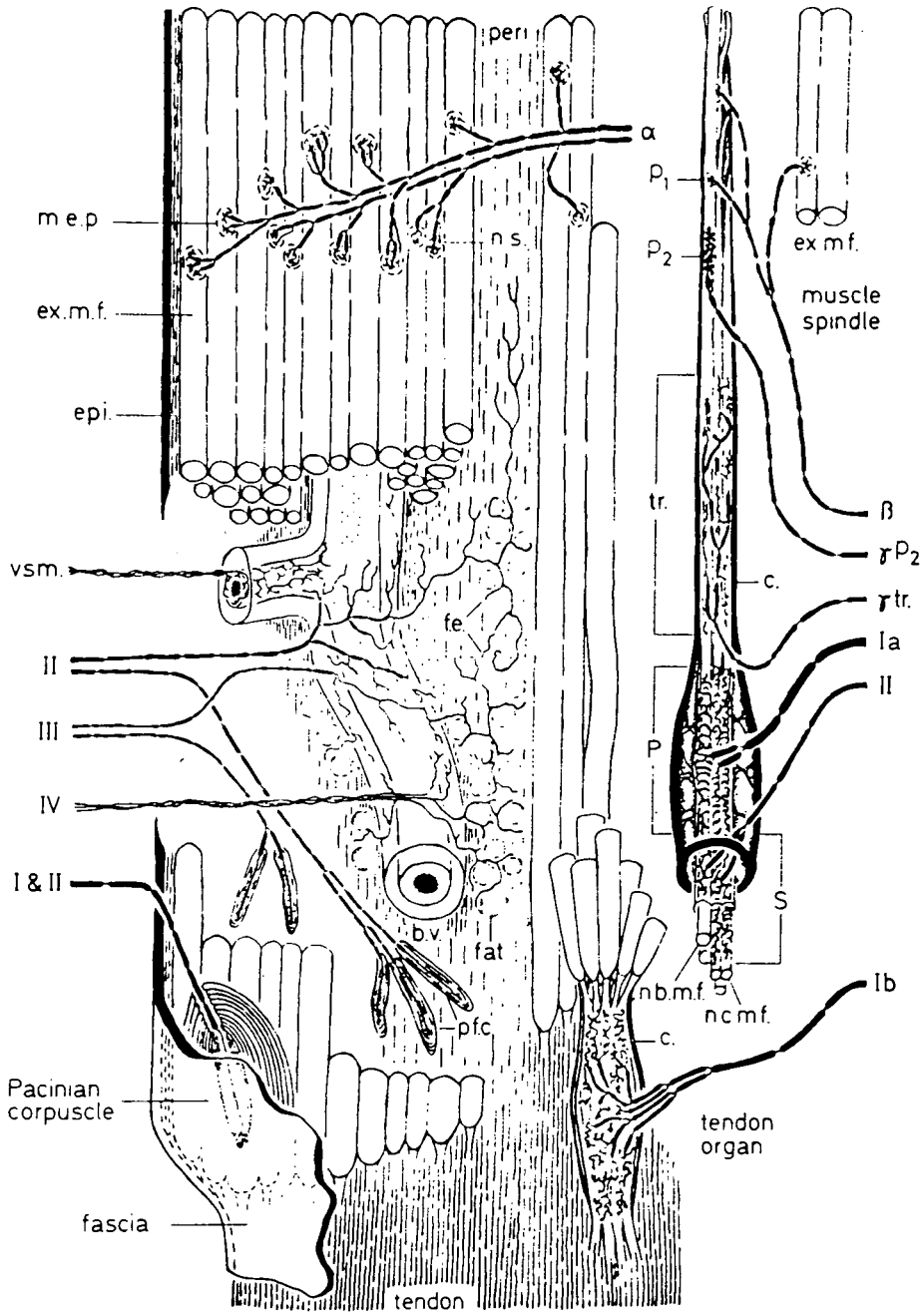


Fig. 1. Schema of the innervation of mammalian skeletal muscle based on a study of cat hindlimb muscles. Those nerve fibres shown on the right of the diagram are exclusively concerned with muscle innervation; those on the left also take part in the innervation of other tissues. Roman numerals refer to the groups of myelinated (I, II, III) and non-myelinated (IV) sensory fibres; Greek letters refer to motor fibres. The spindle pole is cut short to about half its length, the extracapsular portion being omitted. *b.v.* blood vessel; *c.* capsule; *epi.* epimysium; *ex.m.f.* extrafusal muscle fibres; *n.b.m.f.* nuclear-bag muscle fibre; *n.c.m.f.* nuclear-chain muscle fibre; *n.s.* nodal sprout; *m.e.p.* motor end-plate; *P* primary ending; *p<sub>1</sub>*, *p<sub>2</sub>* two types of intrafusal end-plates; *peri.* perimysium; *pf.c.* paciniform corpuscle; *S* secondary ending; *tr.* trail ending; *vsm.* vasomotor fibres.

(Reproduced from Handbook of Sensory Physiology, Vol. III/2. Berlin: Springer-Verlag, 1974, with permission from Professor D. Barker.)



**B**

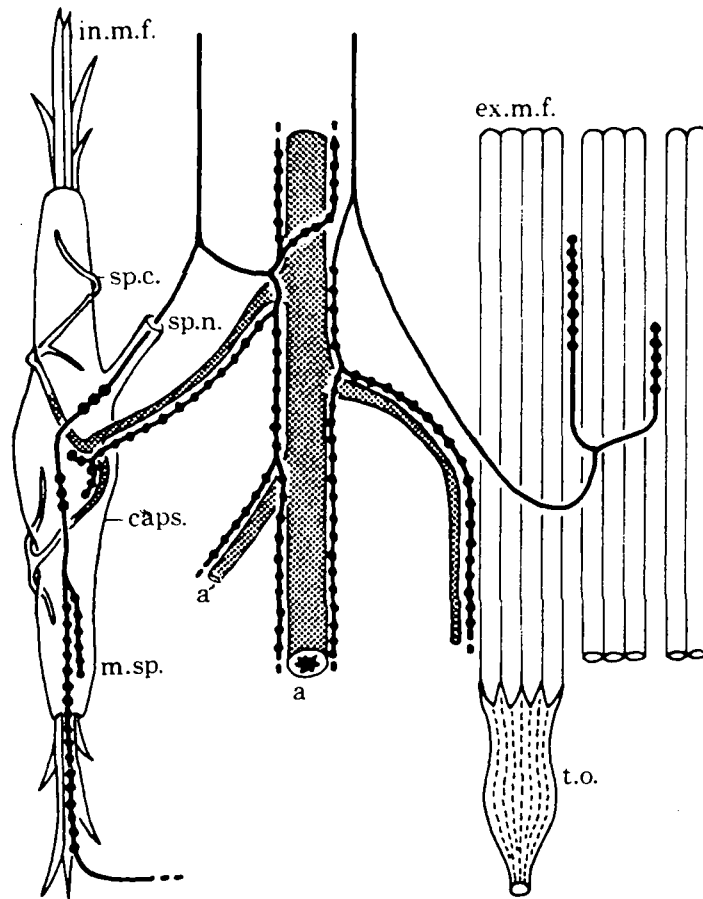


FIGURE 4. Schema of the noradrenergic autonomic innervation of cat skeletal muscle, based on the observations made in this study. The distribution of the varicosities of two noradrenergic axons is shown. Note varicosities among both intra- and extrafusal muscle fibres as well as those lying between arteriole and muscle fibre. Abbreviations: a, artery; a', arteriole; caps., capsule; ex.m.f., extrafusal muscle fibres; in.m.f., intrafusal muscle fibres; m.sp., muscle spindle; sp.c., spindle capillary; sp.n., spindle nerve; t.o., tendon organ.

(Reproduced from Barker and Saito, 1981, with permission from Professor D. Barker.)

sympathetic ganglia of curarized rats, cats and rabbits they saw that this had a marked effect on the tension produced in the jaw-closing muscles. Controversy immediately developed concerning the interpretation placed on their results by the authors and doubts were expressed as to the origin of the generated tension. Was it derived from adrenergic innervation associated with intrafusal muscle fibres as they suggested or was it developed as a result of the stimulation of adrenergic fibres that innervated extrafusal muscle fibres as recently suggested by Lund and Matthews (1987)?

It became obvious that the only way to resolve this problem was to make a detailed histological study of the adrenergic innervation of jaw-closing muscles in one of the species investigated physiologically by Passatore, Grassi and Filippi.

The rat was chosen primarily for its size and the comparative ease with which large amounts of histological data can be generated from relatively small muscles. This is particularly important in any study using electron microscopy and also in any exercise that involves critical serial-section analysis of whole muscles.

During the course of this study on the adrenergic innervation of rat jaw-closing muscles, it became necessary to quantify the histochemical types of extrafusal muscle fibres in the deep masseter muscle. It was found that although the great majority of the fibres are fast type IIA, there is a small minority of slow type I fibres present and that these are exclusively associated with a prominent cluster of muscle spindles in the anterior part of the muscle.

This discrete anterior spindle cluster was considered important for further investigation for two main reasons. Firstly the association of these clustered spindles with the type I extrafusal fibres suggested that they may depend to a large degree for their

fusimotor control on  $\beta$  skeletofusimotor innervation (see Barker, Emonet-Dénand, Harker, Jami and Laporte, 1977; Jami, Lan-Couton, Malmgren and Petit, 1978 and 1979) and therefore contain a large proportion of  $p_1$  plates in their poles. Secondly this clustering of spindles provided an opportunity to study a large number of spindles from a jaw-closing muscle with relative ease. The separation of the anterior cluster region from the rest of the muscle proved invaluable in obtaining data for a serial section analysis of jaw muscle-spindles and also in teasing whole spindles from fairly small blocks of silver-impregnated material. The real importance of the silver material was that it not only provided data concerning  $\beta$  innervation of the spindles, but also the quality of the impregnation allowed a full analysis of the sensory innervation. This kind of analysis had not previously been attempted in the rat because of the difficulty in obtaining good silver preparations in which the motor and sensory innervation are equally well and completely impregnated.

The sensory analysis showed considerable variation in the form and distribution of sensory endings and their associated axons as compared with the situation known to exist in a variety of cat hindlimb muscles (Banks, Barker and Stacey, 1982).

As a consequence of this, an analysis of some rat hindlimb muscles was undertaken to establish whether the differences in form and distribution are muscle or species dependent. The evidence strongly suggests the latter.

In 1983 a claim was made by Maeda and his colleagues (Maeda, Miyoshi and Toh, 1983) that muscle spindles are present in the jaw-closing muscles of the Japanese salmon (*Oncorhynchus masou*). Since such a claim, if substantiated, would have far-reaching implications for the currently accepted views of muscle spindle evolution, it was

considered important to investigate not only fish jaw muscles but also to look at the jaw muscles of two types of limbed amphibians, one of which, the frog (an anuran), is known to have spindles in its limb muscles, and the other, the newt (a urodele), is known not to have spindles in its limb muscles (for more information see Barker, 1974; Bone, Ridge and Ryan, 1976; Bone, 1978).

## CHAPTER II

### Materials and Methods

#### I. Animals used

a. Rat: Male animals of between six weeks and twelve months of age and belonging to the Wistar CFHB strain were used throughout the study, with the exception described below.

The age range of the animals allowed muscles to be chosen that were most suitable for a particular technical requirement. For example small muscles of the younger animals were used in the ultrastructural studies as well as for observations of whole muscle transverse sections. On the other hand the larger muscles of the older animals were most convenient for the application of the block silver stain techniques and the identification and teasing of the muscle spindles.

In that part of the study requiring an accurate count of the extrafusal muscle fibres, it became obvious that there was a large discrepancy between the results obtained by Hiiemae (1971) and those of this study. It was therefore necessary to look at the August strain used by Hiiemae in order to test whether there was any major difference in the numbers of muscle fibres in a particular muscle that could be attributed to a difference in the particular strain of animal used. Also in this context Hiiemae used animals ranging in age between 6-12 months so it was considered appropriate to investigate an animal in the middle of this age range.

b. Fish: Adult trout (*Salmo trutta*)(Teleostei) was chosen for the present study since it is a species of *Salmo* readily available here. I re-examined the presence or absence of muscle spindles in jaw-closing

muscles, since Maeda *et al.* (1983) have reported finding monofibrillar spindles in the jaw-closing muscles of Japanese salmon (*Oncorhynchus masou*).

c. Newt: Adult newt (*Notophthalmus v. viridescens*) (Amphibia, urodele), the common newt of Eastern North America, obtained to use in the present study to search for encapsulated receptors in jaw-closing muscles since it has been reported that the newt limb muscles do not have spindles.

d. Frog: (Amphibia, anuran). Although the frog limb and abdominal pectoral muscles are known to have spindles, there is no information as to the presence of spindles in jaw-closing muscles. Frog (*Rana temporaria*) was chosen to investigate.

The types, numbers and ages of all animals used for particular purposes are shown in Table 1.

## II. Techniques for muscle removal

a. Rat: The animals were killed with an overdose of sodium pentobarbitone (Sagatal). Immediately after the death of the animals the following muscles were carefully dissected out from their attachments: superficial masseter, deep masseter [infra-orbital and zygomatico-mandibular were considered parts of deep masseter according to Weijs (1973) (figures 1a-e)], anterior and posterior digastric, extensor digitorum longus, peroneus longus, lumbrical and soleus. These muscles were used for different techniques, as described later. Only the anterior part of deep masseter (figure 1b) containing the large spindle-cluster was removed for plastic embedding.

**Figure 1(a-e)** Schematic left lateral view of rat skull with masseter muscle. (Redrawn from Weijs, 1973.)

- a. Showing superficial masseter, deep masseter (anterior and posterior parts), origin of infra-orbital and posterior part of zygomatico-mandibular.
- b. Anterior and posterior parts of deep masseter as seen after removal of superficial masseter.
- c. Transverse section of deep masseter at level x-y in b showing the two parts of deep masseter and the three parts of zygomatico-mandibular.
- d. Zygomatico-mandibular as exposed by removal of superficial and deep masseter. Infra-orbital muscle is seen passing through the infra-orbital foramen.
- e. Infra-orbital part of zygomatico-mandibular muscle and some areas of muscle attachment on lateral surface of mandible are seen after removal of anterior and posterior parts of zygomatico-mandibular muscle and zygomatic arch from its roots.

**Abbreviations:**

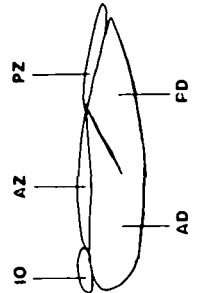
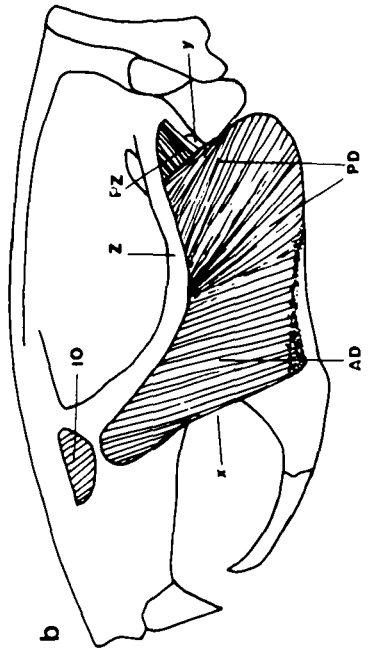
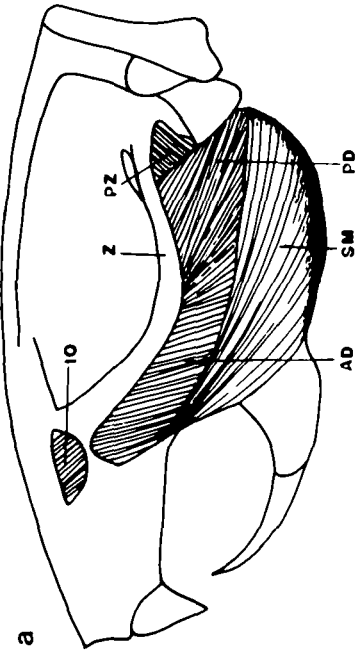
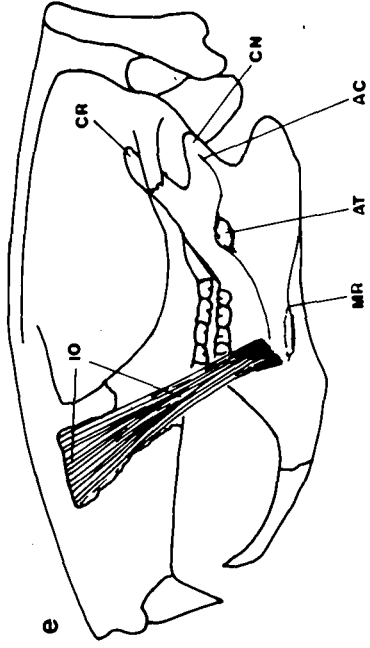
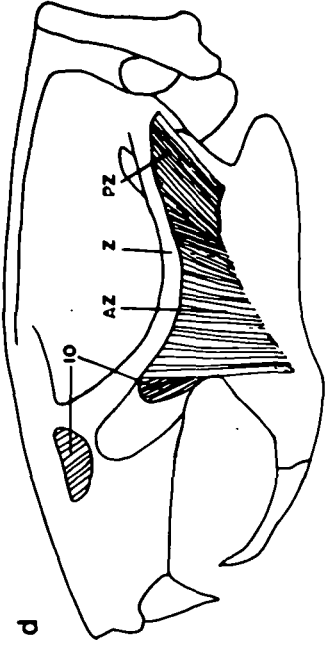
- AC : alveolar condylar cortex  
AD : anterior deep masseter muscle  
AT : alveolar tuber  
AZ : anterior part of zygomatico-mandibular muscle  
CN : condyloid process  
CR : coronoid process  
IO : infra-orbital muscle  
MR : masseteric ridge  
PD : posterior deep masseter muscle  
PZ : posterior part of zygomatico-mandibular muscle  
SM : superficial masseter  
Z : zygomatic arch

Table 1

Type, age and number of animals used for each technique in the present study

Animals			Technique	Purpose	no. of muscles
type	age	no.			
Rat (Wistar strain)	6 weeks	2	wax embedded, stained with Weigert's iron haematoxylin and van Gieson stains, silver-on-the-slide	to map the distribution of muscle spindles, search for tendon organs	2
Rat (Wistar strain)	6 weeks	1	frozen sections, stained with Weigert's iron haematoxylin and van Gieson and Sudan black B stains	for muscle fibres count	4
	4 months	1			2
Rat (August strain)	9 months	2	frozen sections, stained with Weigert's iron haematoxylin and van Gieson and Sudan black B stains	for muscle fibres count	3
Rat (Wistar strain)	6 weeks	4	frozen sections, histochemical stains	to identify muscle fibre types	3
Rat (Wistar strain)	8 months	1			1
Rat (Wistar strain)	6 weeks	2	frozen sections stained with glyoxylic acid	for quantitative analysis of adrenergic innervation	4
Rat (Wistar strain)	6 weeks	2	Araldite embedded, for light and electron microscopy	to study spindle structure	2
Rat (Wistar strain)	8-12 months	4	silver impregnation for teasing	to study spindle innervation	18
Frog ( <i>Rana temporaria</i> )	adult	2	Araldite embedded for light microscopy.	to find if spindles occur in jaw muscle; adductor mandibulae	2
Newt ( <i>Notophthalmus v. viridescens</i> )	adult	2	Araldite embedded for light microscopy.	to find if spindles occur in jaw muscle; adductor mandibulae	4
Fish ( <i>Salmo trutta</i> )	adult	2	wax embedded for light microscopy	to find if spindles occur in jaw muscle; adductor mandibulae	4





c

b. Fish: Two adult trout (*Salmo trutta*) 20 and 22 cms in total length were killed by decapitation. The eyes and skin covering the adductor mandibulae muscles were quickly removed from each side. The complete heads were immersed in formal-saline for 24 hours. The anterior and posterior parts of the adductor mandibulae muscles (figure 4) were removed together and embedded in wax.

c. Amphibian: Two adult frogs (*Rana temporaria*) and two red spotted newts (*Notophthalmus v. viridescens*) were anaesthetized in tap water containing MS<sub>222</sub> (Sandoz) (3-aminobenzoic acid ethyl ether) for 5 mins. The newt heads were severed and placed in Karnovsky fixative for 10 mins. (Karnovsky, 1965).

The anterior part of the frog head was severed using sharp scissors in order to expose the cranial cavity so that the CNS could be destroyed. The remainder of the heads were then severed and immersed in Karnovsky fixative for 10 mins.

Subsequent treatment of the frog and newt heads was similar. The skin covering the adductor mandibulae muscles was removed (figures 2 & 3). The muscles were then kept moist with the fixative while they were dissected and removed from their attachments taking care to preserve the origins and insertions. A stereoscopic microscope was used to dissect the newt muscles. After they had been removed from the heads, all the muscles were left in fixative for a further 50 mins. at 4<sup>0</sup> C, before being dehydrated and embedded in Araldite (see IIIb2).

### III. Tissue preparation

a. Cryo-fixation (rat): Superficial masseter, deep masseter, anterior

Figure 2. Schematic left lateral view of a frog head showing adductor mandibulae and depressor mandibulae muscles after skin has been removed. (Redrawn from Young, 1981.)

Figure 3. Schematic left lateral view of a newt head showing adductor mandibulae muscle after skin has been removed.

Figure 4. Schematic left later view of a trout head showing adductor mandibulae (anterior and posterior parts).

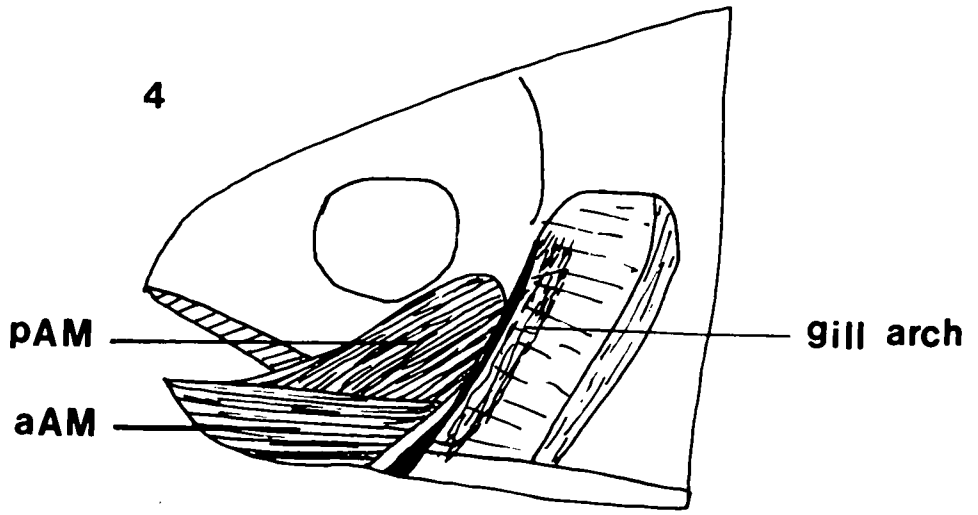
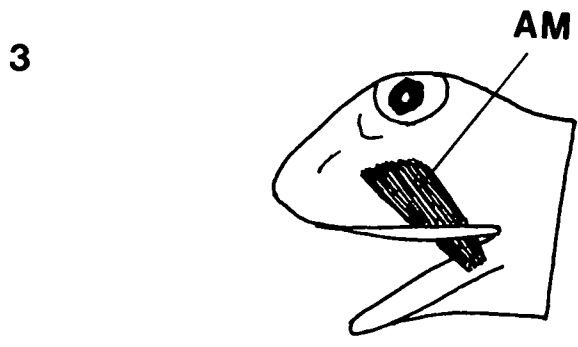
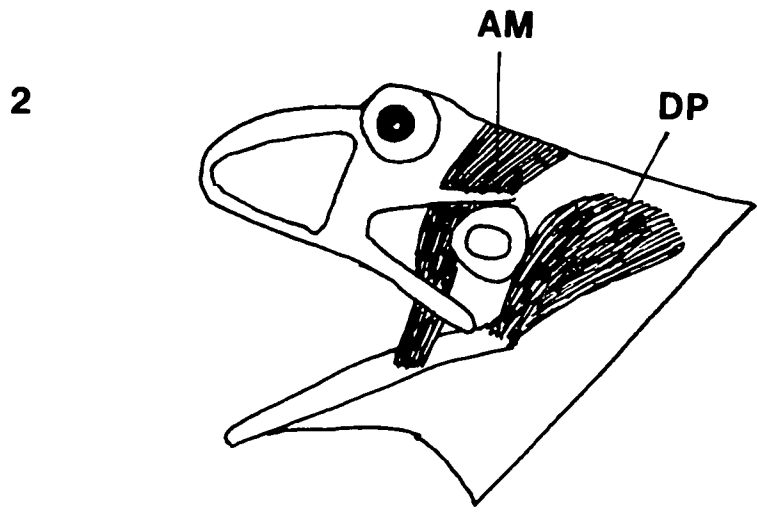
Abbreviations:

aAM : anterior part of adductor mandibulae muscle

AM : adductor mandibulae muscle

DP : depressor mandibulae muscle

pAM : posterior part of adductor mandibulae muscle



and posterior digastric muscles were quickly dissected out. Each muscle was orientated on a piece of card and frozen in isopentane cooled with liquid nitrogen to about  $-160^{\circ}$  C (Maxwell, Ward and Nairn, 1966). Some samples were frozen as composite blocks with the extensor digitorum longus (EDL) muscle as a reference, since its mixed fibre-type composition (I, IIA and IIB) was already known (Schiaffino, Hanzlikova and Pierobon, 1970; Pullen, 1977b). The muscles were then transferred to a cryostat and left for 2-3 hours until they had warmed up to  $-20^{\circ}$  C, the temperature of the instrument. If the muscles were not immediately required for sectioning, they were stored in sealed polythene bags and left in the cryostat for a few days.

b. Perfusion and plastic embedding:

1. Rat perfusion: Since I was not a Home Office licensee under the 1876 Cruelty to Animals Act, the perfusions were carried out by Dr. R.W. Banks. The animals were deeply anaesthetized with sodium pentobarbitone (Sagatal) 5 mg/100 g intraperitoneal injection. They were then perfused through the heart with a modified Karnovsky fixative as used routinely in the Biological Sciences Department, University of Durham as follows:

Solution A

Paraformaldehyde	2 g
distilled water	40 ml
1N NaOH	2-6 drops

The paraformaldehyde and water were heated in a beaker on a hot plate. Drops of NaOH were slowly added while the mixture was shaken, until a clear solution was produced.

Solution B

25% Glutaraldehyde	10 ml
--------------------	-------

0.2 M Sodium cacodylate buffer pH 7.3            50 ml

The two solutions were freshly prepared, kept separated at room temperature and mixed just before use.

To expose the heart, the diaphragm and costal cartilages were cut and the sternum was elevated. The pericardium was cut and a small slit made in the left ventricle. The cannula was then inserted and clamped firmly with artery forceps. An opening was made in the right atrium to allow the escape of blood and fixative. A peristaltic pump was used to pump the fixative for about 5 mins. until the rigidity of the tissues signified that perfusion was complete.

## 2. Plastic embedding:

Karnovsky-fixed tissue from rats, frogs and newts were dehydrated and embedded in Araldite as follows:

Post-fixation: for 2 hours at 4<sup>o</sup> C in 1% buffered osmium tetroxide made by mixing 50 ml 2% osmium tetroxide and 50 ml 0.2 M sodium cacodylate buffer pH 7.3.

Dehydration: at room temperature in a graded series of alcohols:

70% alcohol	for	15	mins	(3	changes)
95%	"	"	"	"	"
absolute	"	"	"	"	"

Infiltration: with Araldite using the following procedure:

- i) 50:50 mixture absolute alcohol:propylene oxide - 30 mins  
(3 changes)
- ii) propylene oxide - 30 mins (3 changes)
- iii) 50:50 mixture propylene oxide:Araldite - 60 mins at 45<sup>o</sup> C
- iv) Araldite - 60 mins at 45<sup>o</sup> C

Embedding: the specimens were first embedded overnight in fresh Araldite at 45° C and then at 60° C for a further two days.

c. Formal-saline fixation and wax embedding:

Some deep masseter muscles from rats and the adductor mandibulae muscles from fish were dissected out and immersed for 24 hours in formal-saline fixative (70 ml of 10% sodium chloride, 830 ml distilled water, 100 ml 40% formalin), dehydrated in ethyl alcohol for 8 hours, cleared in chloroform for 4 hours, and impregnated with molten plasticized paraffin wax for 4 hours.

To remove any air trapped in the specimens, the blocks were transferred to a glass jar containing molten paraffin wax, which was placed in a vacuum embedding oven at reduced pressure for 10 mins. Finally the muscles were embedded in plasticized paraffin wax.

IV. General staining methods

a. Weigert's iron haematoxylin and van Gieson's stains:

Weigert's iron haematoxylin stain for nuclei and van Gieson's stain for collagen (Drury and Wallington, 1980) were used for wax and frozen sections in order to identify muscle fibres and to trace the muscle spindles.

Using Weigert's iron haematoxylin and van Gieson's stains, connective tissue stains pink, muscle fibres yellow and nuclei blue-black. Frozen sections were fixed in 5% glutaraldehyde for 5 mins, rinsed in distilled water and stained with Weigert's iron haematoxylin stain for 5 mins, washed in running tap water, rinsed in distilled water then stained with van Gieson's stain for 5 mins, dehydrated, cleared and finally mounted in D.P.X.

b. Sudan black B stain:

Sudan black B stain is soluble in most lipids and particularly in phospholipids. It is more soluble in propylene glycol than in alcohol. The intensity of staining of mitochondria and other small particles was far greater with the dye in propylene glycol than in the alcoholic solvent (Pearse, 1972).

Frozen transverse sections (approx. 20  $\mu\text{m}$  thickness) were stained with saturated solution of Sudan black in 70% alcohol as used by Hiiemae (1971) or in propylene glycol in order to identify muscle fibres for counting purposes using Hiiemae's procedures as closely as possible. The procedures for staining were as follows:

1. Sudan Black B in 70% alcohol:

- i) Sections were fixed in 10% formal-saline for 5 mins
- ii) Rinsed in distilled water
- iii) Incubated in a saturated solution of sudan black B in 70% alcohol for 15 mins
- iv) Rinsed quickly in 70% alcohol
- v) Washed in tap water for 1 min
- vi) Mounted in glycerol

2. Sudan black B in propylene glycol:

- i) Sections were fixed in 10% formal-saline for 5 mins
- ii) Rinsed in distilled water
- iii) Drained and immersed in saturated Sudan black B in propylene glycol for 8 mins
- iv) Drained well then agitated in 85% propylene glycol wash for 3 mins
- v) Drained, agitated in 50% propylene glycol wash for 3 mins



- vi) Drained, agitated in a beaker of tap water for 1 min
- vii) Drained and mounted in glycerol

c. Toluidine blue:

1  $\mu$ m thick sections of Araldite-embedded material were collected on glass slides. Drops of 1% toluidine blue in borax solution were placed directly on the sections and the slides were left for about 30 secs on a hot plate. They were then rinsed gently with distilled water to remove excess stain, dried on the hot plate and mounted in D.P.X.

V. Special histological techniques and methods

a. The demonstration of the adrenergic innervation:

1. Staining method: To investigate the adrenergic innervation associated with extra- and intrafusal muscle fibres in rat jaw muscles, serial 20  $\mu$ m transverse sections were treated with 1% glyoxylic acid in 0.236 M  $\text{KH}_2\text{PO}_4$  buffer containing 0.2 M sucrose to induce fluorescence, using König's (1979) technique. The solution was prepared as follows:

Glyoxylic acid monohydrate	1.0 g
$\text{KH}_2\text{PO}_4$ (potassium dihydrogen orthophosphate buffer) (mol. wt. 136.09)	3.2 g
Sucrose (mol. wt. 342.30)	6.8 g
Distilled water	80-90 ml

The solution was adjusted to pH 7.4 with 2 M NaOH then made up to 100 ml with distilled water and kept refrigerated until used.

The slides were immersed in the solution at room temperature for 30 secs. Excess solution was blotted with tissue paper, and the sections were then dried with cold air from a hair dryer for 3 mins,

placed in an oven at 80° C for 5 mins, mounted with fluoromount or paraffin oil and finally placed on a hot plate at 80° C for 3 mins. Sections could be kept for about 4 weeks in a dark cold place without fading but subsequent photography caused fading.

Occasionally 0.05% (w/v) pontamine sky blue 5 BX (PSB) was added to glyoxylic acid solution as a counter-stain for background (Cowen, Haven and Burnstock, 1985).

The preparations were viewed and photographed on a Zeiss Ultraphot II microscope equipped with an HBO 200 high-pressure mercury lamp, a BG 12 excitation filter and barrier filters. Photographs were taken with a 35 mm camera on Ilford XP1 ASA 400 film by doubling the automatic exposure settings (maximum 26 mins).

## 2. Searching and counting techniques for nerve fibres innervating spindles and extrafusal muscle fibres:

To count the number of spindles and extrafusal muscle fibres receiving adrenergic innervation groups of ten consecutive sections were treated with glyoxylic acid. The groups were separated by single sections stained with Weigert's iron haematoxylin and van Gieson stains to facilitate tracing individual muscle fibres.

### 2.1. Searching and counting method for muscle spindles:

Every spindle in deep masseter muscle was carefully examined from end to end in serial transverse sections for catecholamine fluorescence by using long wave ultraviolet light for the excitation of fluorescence to find any varicosity associated with intrafusal fibres or within the spindle.

When a spindle was located, its position was plotted on a schematic diagram. A mark was added to the plotted position if the

spindle had received adrenergic innervation.

## 2.2 Searching and counting method for extrafusal muscle fibres:

In attempting to quantify the frequency of adrenergic innervation in neuroeffective association with some extrafusal muscle fibres, a complete deep masseter muscle and an anterior digastric muscle were serially sectioned at 20  $\mu\text{m}$  and sampled at 220  $\mu\text{m}$  intervals. This resulted in 45 samples of deep masseter muscle (figure 5) and 41 samples of anterior digastric muscle (figure 6), which were treated as above. Every eleventh section was stained with Weigert's iron haematoxylin and van Gieson stains, and a projection microscope was used to trace a  $\times 10$  enlargement on graph paper. The adjacent section was treated with glyoxylic acid and carefully examined. The number of extrafusal muscle fibres associated with autonomic axons and varicosities were counted for deep masseter and left digastric muscles and the exact number of extrafusal muscle fibres was then marked on the traced outline on graph paper in corresponding positions. Finally a total count was made for each section (figures 5 & 6).

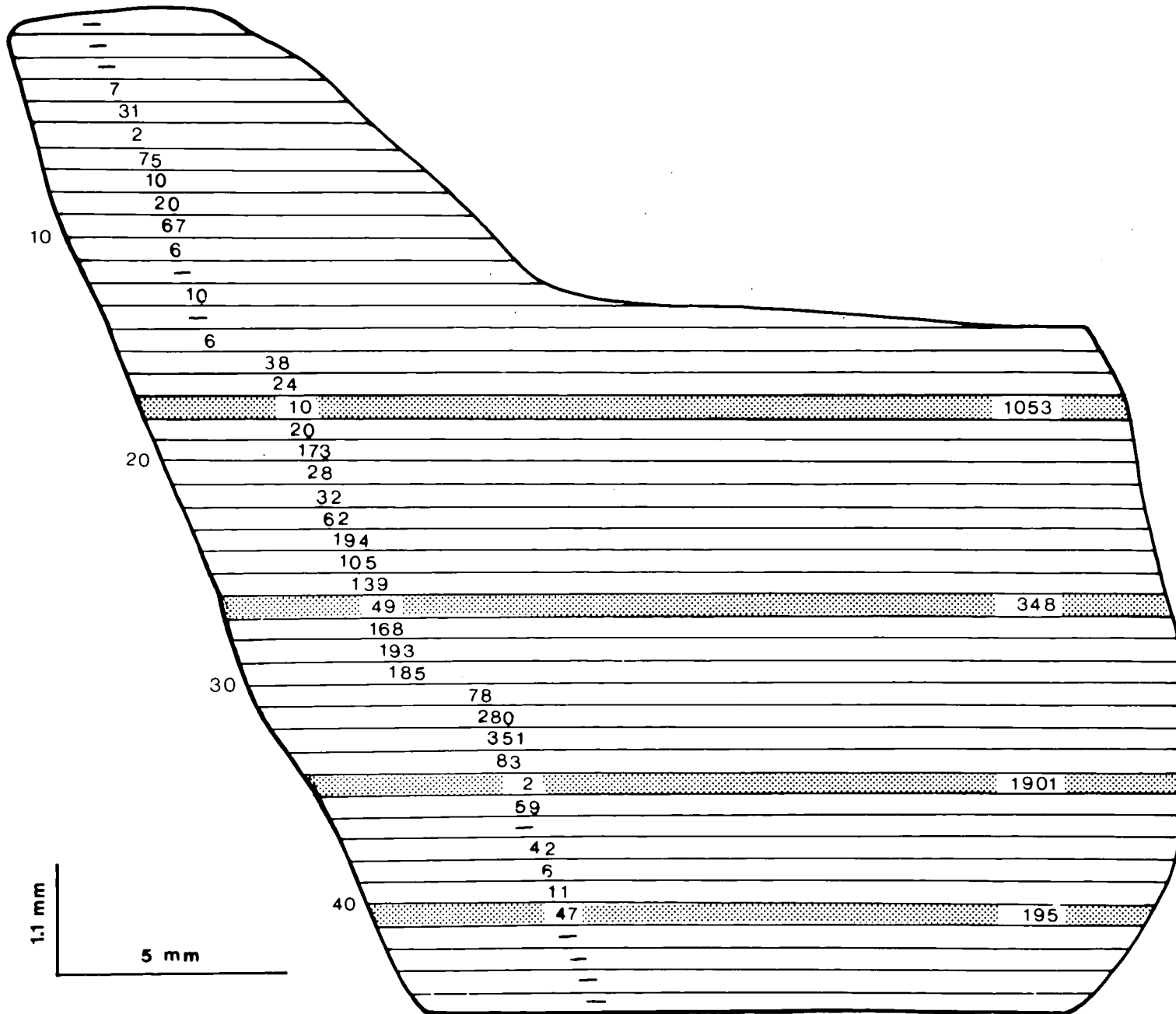
In order to estimate the number of extrafusal muscle fibres associated with adrenergic innervation in the 200  $\mu\text{m}$  intervals between these samples, the counts were made on 4 samples of 10 serial cross-sections obtained from different levels spaced 1-2 mm apart in each deep masseter and anterior digastric muscle (dotted areas in figures 5 & 6).

### b. The demonstration of nerve endings:

#### 1. The Holmes' silver-on-the-slide method:

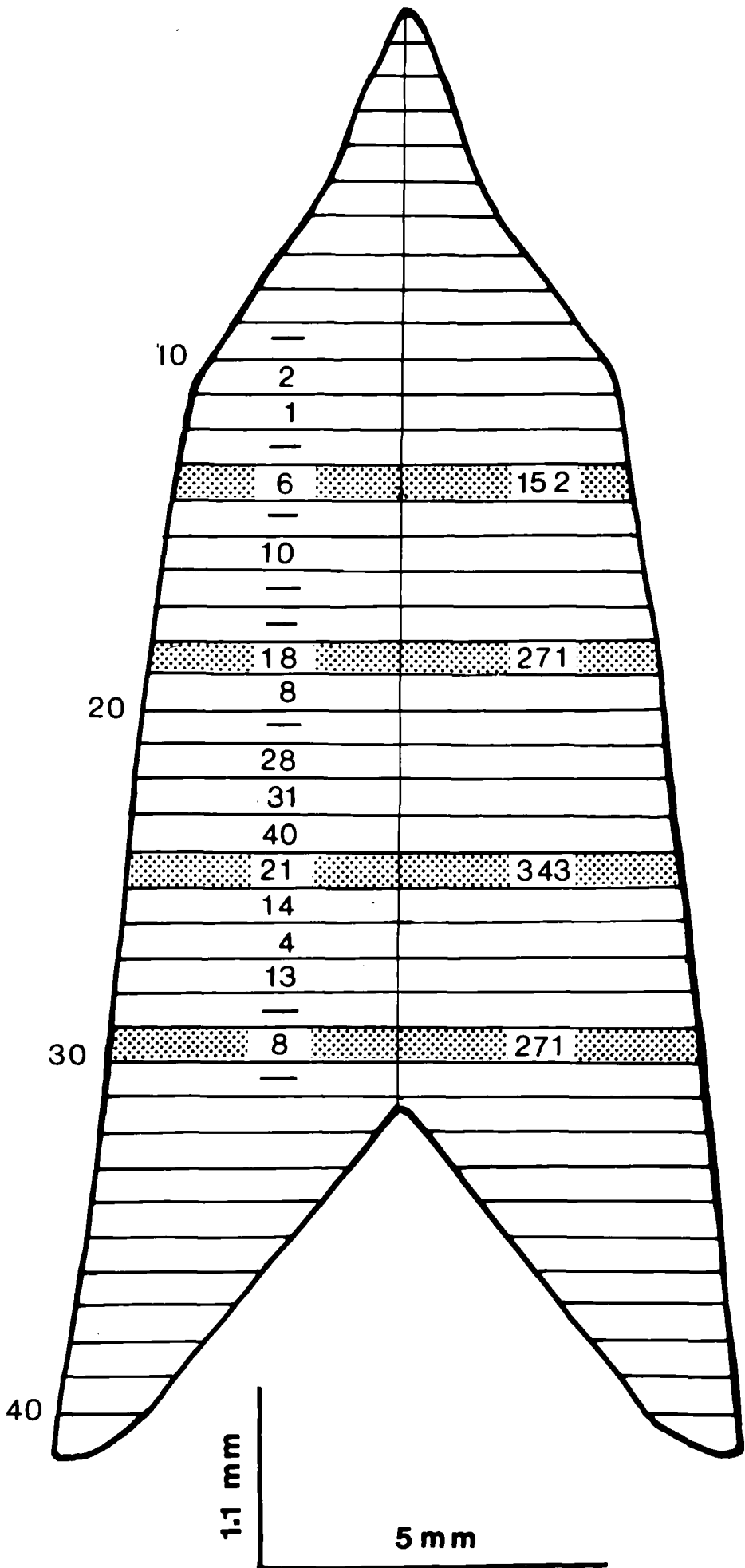
To search for the tendon organs in rat masseter and to reconstruct the masseteric nerve, one complete deep masseter muscle embedded in wax

**Figure 5.** Schematic diagram of a reconstruction of rat deep masseter muscle serially sectioned using a cryostat, to show the abundance and distribution of adrenergic innervation associated with extrafusal muscle fibres. The distance between adjacent lines represents eleven sections of 20  $\mu\text{m}$  thickness each, ten treated with glyoxylic acid and the eleventh stained with Weigert's iron haematoxylin and van Gieson stains. The position of every tenth repeat of this pattern is given on the extreme left of the diagram. Within each repeat an exact count of extrafusal muscle fibres associated with adrenergic innervation was made for one section and is given inside the outline of the muscle on the left. The shaded areas represent the samples of serial cross-sections that were completely counted to estimate the number of extrafusal muscle fibres associated with adrenergic innervation in the remaining 200  $\mu\text{m}$  intervals, as described in the text. The exact counts for these completely analysed samples are given on the right of the shaded areas.



**Figure 6.** Schematic diagram of a reconstruction of rat anterior digastric muscle serially sectioned using a cryostat, to show the abundance and distribution of adrenergic innervation associated with extrafusal muscle fibres. For explanation see legend to figure 5.

6



was serially cross-sectioned at 10  $\mu\text{m}$ . The sections were then stained with silver followed by Holmes' silver-on-the-slide method (Drury and Wallington, 1980) and they were examined for the presence of tendon organs.

2. The modified de Castro method and teasing of muscle blocks, especially the anterior spindle-cluster:

To study spindle innervation and search for skeletofusimotor units innervated by slow dynamic  $\beta$  axons in deep masseter muscle and the sensory innervation of spindles in some muscles of hindlimb (peroneus longus, lumbrical and soleus) muscles of rat; the silver impregnation technique of the modified de Castro method of Barker and Ip (1963) was used. The muscles were dissected from rats aged 8-12 months.

It was found that in order to obtain good staining of sensory innervation and to exhibit the fine details of innervation of the spindle, the quantity of concentrated nitric acid had to be doubled and the fixation time reduced, compared with the original method. The procedures were as follows:

- i) Fixed for 3 days in a mixture of chloral hydrate, 1 g; 95% alcohol, 45 ml; distilled water, 50 ml; 70% concentrated nitric acid, 2 ml.
- ii) Washed for 24 hours in constant flow:  
30 litres distilled water  
6 g aluminium sulphate  
made up to pH 9 by the addition of concentrated sodium hydroxide  
(added drop by drop to 1 L then multiply to 30 L).
- iii) Transferred to ammoniacal alcohol for 24 hours:  
400 ml 95% alcohol + 10 drops concentrated ammonia solution.
- iv) Muscles coated in 1% agar:



300 ml distilled water + 3 g agar

brought to the boil, allowed to cool to 45° C, then dipped in repeatedly until the agar began to set, and the muscles were well coated.

- v) Placed in 1.5% silver nitrate solution in a dark water bath with shaker at 37° C for 7 days.
- vi) Rubbed off agar coat and placed in reducer for 24 hours [2 g hydroquinone (quinol) in 100 ml of 25% formic acid].
- vii) Washed in distilled water and placed in glycerol.

The complete anterior spindle-cluster and a few fasciculi surrounding it were carefully removed from the main mass of the deep masseter muscle and then squashed between two glass slides. To search for and observe  $\beta$  and sensory innervation, further teasing was done under a stereoscopic microscope using transmitted and reflected light. The teased specimens were mounted in glycerol on microscope slides and the cover-slips were ringed with pitch.

## VI. Techniques and methods for muscle fibre histochemistry

### a. Cryostat sectioning:

Rat muscles kept in the cryostat in polythene bags were removed from the cards using pre-cooled forceps and were cemented to cryostat chucks with glue (cryomatrix). A small quantity of glue was put on the platform of a pre-cooled chuck in the refrigerated chamber. As the glue began to solidify the muscle was orientated in the glue on the chuck, more glue was added around the muscle to provide further support during sectioning.

The chuck with the frozen muscle was transferred to the microtome

and maintained at  $-20^{\circ}$  C. Serial transverse sections were cut at between 12-20  $\mu$ m thickness. Two consecutive sections were placed on each microscope slide and the slides numbered in series. The slides were then stored in trays in the cryostat at  $-20^{\circ}$  C until required for staining.

b. Staining methods:

Extrafusal muscle fibres in this study were typed according to the Brooke and Kaiser nomenclature (Brooke & Kaiser, 1970) which is based upon enzymatic histochemical reaction properties for myosin ATPase. Different histochemical stains were used to identify extrafusal and intrafusal muscle fibre types; myosin ATPase activity after acid or alkali pre-treatment (method A in Snow, Billeter, Mascarello, Carpené, Rowleron and Jenny, 1982). The oxidative activity of muscle fibres was demonstrated by staining for succinate dehydrogenase activity (Pearse, 1972).

1. Acid-stable actomyosin adenosine tri-phosphatase:

Stable wash solution was prepared and stored in a fridge (this can be stored for long periods). The other unstable solutions were freshly prepared immediately before use. All procedures were carried out at room temperature.

Wash solution

15.46 g Na-barbital mol. wt. 206.2

5.74 g Na-acetate mol. wt. 82.03

dissolved in 500 ml distilled water.

Mixed well with

14.7 g  $\text{CaCl}_2$  mol. wt. 147.02

dissolved in 500 ml distilled water.

Then stored in fridge.

Frozen sections were:

- i) Dried for 5 mins
- ii) Pre-incubated for 5 mins in acid buffer:  
0.1 M Na-acetate (0.8203 g/100 ml distilled water)  
or 0.2 M Na-acetate (1.6406 g/100 ml " " )  
adjusted to pH 4.35 with acetic acid
- iii) Washed twice with distilled water
- iv) Washed twice with wash solution adjusted to pH 9.45 with acetic acid
- v) Incubated for 60 minutes in:  
Wash solution 100 ml  
Adenosine triphosphate (disodium salt) 0.15 g  
adjusted to pH 9.45 with acetic acid
- vi) Washed three times with 0.2 M  $\text{CaCl}_2$
- vii) Incubated 2 mins in 2%  $\text{CoCl}_2$
- viii) Washed three times with distilled water
- ix) Incubated 40 seconds in 1%  $(\text{NH}_4)_2\text{S}$
- x) Washed well in tap water for 5 mins
- xi) Dehydrated and mounted in D.P.X.

## 2. Alkaline-stable actomyosin adenosine tri-phosphatase:

The same procedure was adopted as in acid ATPase, but differing only in the following steps:

- ii) Pre-incubated for 18 mins in alkali buffer:  
Wash solution 100 mls  
adjusted to pH 10.4 with NaOH
- iv) Washed twice with wash solution adjusted to pH 9.6 with NaOH
- v) Incubated for 30 mins in:

Wash solution	100 ml
Adenosine triphosphate (disodium salt)	0.15 g

adjusted to pH 9.6 with NaOH.

3. Succinate dehydrogenase:

Nitroblue tetrazolium salt was used to demonstrate succinate dehydrogenase (SDH) activity according to standard method (Pearse, 1972). Sections were

i) Incubated at 37<sup>o</sup> C for 25 mins in:

Nitro B.T. (Nitroblue tetrazolium salt)	50 mg
0.2 M sodium succinate	25 ml
0.2 M Phosphate buffer (pH 7.6)	25 ml
Distilled water	50 ml

4. Antibody-specific methods for type I and type IIA fibres:

Immunohistochemical identification of myosin types (slow and fast) was carried out on cryostat sections of muscle. The origin and specificity of the antisera used here against myosin types I, IIA and IIM are described elsewhere (Bosley and Rowleron, 1980; Carpené, Rowleron, Veggetti and Mascarello, 1982; Rowleron, Pope, Murray, Whalen and Weeds, 1981; Snow *et al.*, 1982; Rowleron, Mascarello, Veggetti and Carpené, 1983) and summarised in the publication of Rowleron, Mascarello, Barker and Saed (1988).

The sections were collected on slides, packed in dry ice in an insulated box and taken to the Institute of Physiology in Glasgow where Dr. Rowleron kindly carried out the staining procedures. Using indirect immunoperoxidase staining, the sections were fixed in acetone for 5 mins, divided into 3 groups, each one treated with myosin type-specific antiserum I, IIA and IIM then the procedures completed as

described by Rowleron *et al.* (1981) and as follows:

- i) Incubated in antiserum diluted 1:1000 in 1% albumin-containing phosphate-buffered saline (PBS)
- ii) Rinsed in PBS + 0.1% Brij
- iii) Incubated in peroxidase-labelled anti-rabbit IgG antibody
- iv) Rinsed again then incubated in 0.03%  $H_2O_2$  in PBS + 1 mg ml<sup>-1</sup> diaminobenzidine
- v) Dehydrated in ethyl alcohol and xylene then mounted in XAM (Gurr).

## VII. Techniques and methods for electron microscopy

After the perfusion of rats was completed, the anterior portion of the deep masster muscle (figure 1b) containing the spindle-cluster was removed from 2 muscles and post-fixed, dehydrated, infiltrated and embedded in Araldite as described in IIIb.

### a. Sectioning on ultramicrotome:

Transverse sections (1  $\mu$ m thickness) from an Araldite sample of the small piece of the muscle that contained the anterior spindle-cluster were cut with a Reichert OMU3, using glass knives. Each section at 50  $\mu$ m intervals was stained with 1% toluidine blue in borax and scanned with a light microscope for muscle spindles. When non-myelinated axons were detected near or within a spindle and among extrafusal muscle fibres, ultra-thin transverse sections (silver to gold interference colour) were picked up on coated 50 mesh copper grids. The sections were stained with uranyl acetate and lead citrate (Reynolds, 1963), and examined with a Philips 400T electron microscope. Every section containing unmyelinated axons was photographed.

b. Reconstruction of serially sectioned muscles:

1. Reconstruction of the anterior spindle-cluster from plastic sections:

For the study of muscle spindles in jaw muscles of rats, the Araldite-embedded anterior portion of deep masseter muscle containing the spindle-cluster was trimmed to a small area enclosing the cluster. With a Reichert OMU3 ultramicrotome, using glass knives, the spindle-cluster was serially sectioned in 1  $\mu\text{m}$ -thick transverse sections from end to end, starting from its insertion in the tendon. Each 10th section was placed on a clean microscope slide, up to 10 sections on each slide. All sections were stained with 1% toluidine blue in borax.

Each section at 50  $\mu\text{m}$  intervals was photographed at  $\times 50$  using a Microflex UFX camera on a Nikon biological microscope (OPIPHOT). Micrographs were enlarged to  $\times 500$ . Each spindle on the enlargement was traced and then transferred to graph paper, from which lengths of capsules and intrafusal fibres could be obtained. A schematic diagram was made to show the spindle cluster (figure 45).

2. Number and position of muscle spindles in deep masseter muscle:

One complete deep masseter muscle was embedded in paraffin, cut serially in 10  $\mu\text{m}$  transverse sections from origin to insertion and then stained with Weigert's iron haematoxylin and van Gieson stains.

To map each spindle within the muscle, a projection microscope was used to project every 20th section on to graph paper fixed to a board on the wall. The figure was enlarged 10 times, and the position of each spindle was plotted on a profile of the section. A diagram was made to show the number and position of the muscle spindles (figure 9).

3. Measurement of intrafusal muscle fibre parameters:

By using a stage and an eye-piece micrometer with an appropriate objective of a Nikon biological microscope (OPIPHOT), the diameter of capsules and intrafusal fibres were measured from thick plastic sections (1  $\mu\text{m}$  approx.) stained with toluidine blue. Axon diameters were measured from teased silver impregnated preparations.

The capsule and intrafusal muscle fibre lengths were obtained from reconstruction of serially sectioned plastic material (see VII b1).

VIII. Technique for estimating muscle fibres in deep masseter and anterior digastric muscles

Anterior and posterior digastric, infra-orbital and deep masseter muscles from 6 week and 4 month old Wistar strain male rats, and 9 month old male August strain were used for fibre counts.

20  $\mu\text{m}$ -thick transverse frozen sections from the region of the physiological cross-section (Fick, 1911; Hiimeae, 1971) of each muscle were cut on a cryostat at  $-20^{\circ}$  C. Some sections were fixed in glutaraldehyde and stained with Weigert's iron haematoxylin and van Gieson stains, whilst others were fixed in formal-saline and stained with Sudan black B stain in alcohol or in propylene.

a. Photography and montage:

The sections stained with Sudan black B in 70% alcohol were photographed using a Microflex UFX camera mounted on a Nikon biological microscope (OPIPHOT) at  $\times 5$  and enlarged to  $\times 60$  (Hiimeae's procedures, 1971), while sections stained with Sudan black B in propylene or with Weigert's iron haematoxylin and van Gieson stains were photographed at

x25 and enlarged to x150. Montages for each section were made.

b. Counting method:

All fibres in the sections of anterior and posterior digastric and infra-orbital muscles were counted from the photographs using a hand counter. For the deep masseter muscle, total fibre population was estimated by counting the number of fibres in four square millimetres. The mean number of fibres was multiplied by the area of the largest cross-section.

To check Hiimae's (1971) results in her count of rat jaw muscle fibres, an anterior digastric muscle from a 4 month old male Wistar rat was taken and Hiimae's method was followed to obtain a total count from a x60 montage. Counts of three separate square inches following her convention were made. The transverse section adjacent to the one used for these counts was stained with Weigert's iron haematoxylin and van Gieson stains and montaged at x150. Fibre counts were made in  $2\frac{1}{2}$  square-inch areas, equivalent to the square-inch counts made on the x60 montage, and similar counts were made.

To assess the error involved in estimating the total number of muscle fibres using samples, the area in square inches of the left anterior digastric in the x60 montage was measured and found to be 45.2 square inches. When this was multiplied by the mean of the three separate square-inch counts (157) made from this montage, an estimated total population was obtained (see Table 2), and this was compared with the total obtained by direct counting of the same muscle.



## CHAPTER III

### The morphology of rat jaw muscles

#### A. Introduction

It is known that the main functions of the mastication muscles in mammals are to stabilize the mandibular joints and to move the mandible. They are divided into two groups: the closing muscles, which are composed of masseter, temporalis and medial pterygoid; and the opening muscles, comprising anterior and posterior digastric, lateral pterygoid and several other supporting muscles including transverse mandibular, mylohyoid, geniohyoid and stylohyoid. In this study I have chosen the masseter muscle since it is the largest and most powerful muscle in the closing group (Hiemae, 1971) and possesses a relatively high number of muscle spindles (Karlsen, 1965; Maier, 1979; Lennartsson, 1980b); and the anterior digastric muscle since it is the main one in the opening group and usually lacks spindles.

#### Gross morphology and nomenclature of the masseter in the Albino Rat (*Rattus norvegicus*)

The morphology of the masseter muscle of the rat has been described by many authors (Greene, 1955; Hebel and Stromberg, 1976; Hiemae and Houston, 1971; Turnbull, 1970; and Weijs, 1973) all of whom agree that this muscle consists of two distinct parts. These have been called the superficial and deep masseter muscles. However, the authors differ widely in their nomenclature and morphological descriptions of the deep masseter muscle.

Turnbull (1970) and Weijs (1973) have given good morphological accounts of the rat masseter. In this study I have followed the description and nomenclature outlined by Weijs (1973). The superficial masseter (figure 1a) originates from a small knob on the maxilla by means of a flattened tendon, and inserts into the ventral border of the mandible from its mid-point to the posterior border of the angular process. There is a considerable pars reflexa around the lower border of the mandible in its middle part. The superficial part of the masseter is easily separated from the large deep part.

The deep masseter consists of three parts (figures 1b-e); the anterior deep masseter, the posterior deep masseter and the zygomatico-mandibular. It is difficult to separate these from each other. The zygomatico-mandibular part subdivides into an infra-orbital part, which is small and quite distinct, and the anterior and posterior parts, which are small and thin. The muscle takes its origin from the concave smooth surface of the inferior root of the zygomatic process of the maxilla and its dorsal border, the rostromedial wall of the infra-orbital foramen, and zygomatic process of the squamosal, and inserts into the lateral mandibular surface along the lower edge of the mandible.

The left and right digastric muscles each consist of anterior and posterior bellies connected by a tendon. The muscle originates from the paramastoid process of the occipital bone and inserts into the ventral edge of the mandibular rami behind the symphysis. The anterior left and right digastric muscles lie side by side in the horizontal plane between both rami of the mandible.

Quantification of the adrenergic innervation of the deep masseter and anterior digastric muscles (Chapter IV) required knowledge of the numbers of extrafusil muscle fibres present in these muscles. Hiemae

(1971) has published fibre counts of various rat jaw muscles including deep masseter and digastric, and originally I intended to use these data to express the proportion of extrafusal muscle fibres receiving adrenergic innervation. However, the numbers of adrenergically innervated fibres were found to be higher than the total counts made by Hiemae. Consequently it was necessary to do some counts on the muscles I was using from 6-week-old Wistar strain male rats. The counts were between two and three times higher than those of Hiemae.

Since Hiemae's observations were made on August strain rats, there was a possibility that the difference in the results was due to the use of different strains. In order to check this possibility I made counts using animals similar to those used by Hiemae, i.e. 3-9 month-old male August strain, and found that there was no difference.

This suggested that the conflicting results might have been due to the preparative and counting methods used by myself and by Hiemae, or to the different ages of animals used. There were two major differences in technique: (i) fixation and staining, (ii) photographic enlargement. Despite following Hiemae's technique as closely as possible, I did not obtain a count as low as that of Hiemae in either strain of rat. Rowe and Goldspink (1969) found that mammalian muscle fibres do not increase in number after birth. I have confirmed this for the anterior digastric muscle by counting the muscle fibres from a six-week and a four-month-old male Wistar strain rat.

The occurrence, distribution and number of muscle spindles in rat deep masseter have been described by Karlsen (1965); Maier (1979); and Lennartsson (1980b). Most spindles occur in the medial part of the muscle and are unevenly distributed in transverse planes but evenly distributed along the origin-insertion length of the muscle. Furthermore they occur in groups or clusters (Karlsen, 1965; Maier,

1979; and Rokx, van Willigen and Jansen, 1984). Some spindle capsules are fused together at their equatorial regions forming complexes especially in the areas containing SO extrafuscal fibres (Maier, 1979; Rokx *et al.*, 1984). In the rat Karlsten (1965) found 130 spindles in the masseter muscle (superficial and deep), all but 6 of them in the deep portion, and were concentrated in four areas. Tandem spindles were rare in jaw muscles. Maier (1979) found 73-85 spindles in deep masseter, located chiefly in regions containing a large number of FOG fibres. Lennartsson (1980b) reports an average of 110 spindles found in 6 masseter muscles.

Muscle spindles were occasionally found in the anterior digastric muscle of some species: in rats, Shehata (1971), Lennartsson (1980b); in human, Lennartsson (1979b); in monkey, Lennartsson (1979a); and in rabbit, Muhl and Kotov (1988).

In all the histological studies carried out on the jaw muscles of mammals, Golgi tendon organs (T.O.) have been mentioned in only one paper, which described T.O. in cat masseter and temporalis muscles (Lund, Richmond, Touloumis, Patry and Lamarre, 1978). In this study I have specifically sought T.O.s in the rat deep masseter.

Mastication muscles receive their motor and sensory nerve supply from the trigeminal nerve, the deep masseter being innervated by its masseteric branch.

## B. Results

### 1. Pattern of branching of masseteric nerve

From 10  $\mu\text{m}$ -thick paraffin sections of one complete deep masseter muscle, stained with silver, the masseteric nerve supply to the anterior cluster spindles was traced (figure 7). The nerve penetrates the deep masseter muscle on its medial side, and separates the anterior and posterior parts of the zygomatico-mandibular muscle (Weijs, 1973). After having penetrated this muscle the nerve branches out for the first time, before running obliquely through the posterior deep masseter layers forming secondary branches. It then continues horizontally, reaching the anterior spindle cluster and branching out on the way.

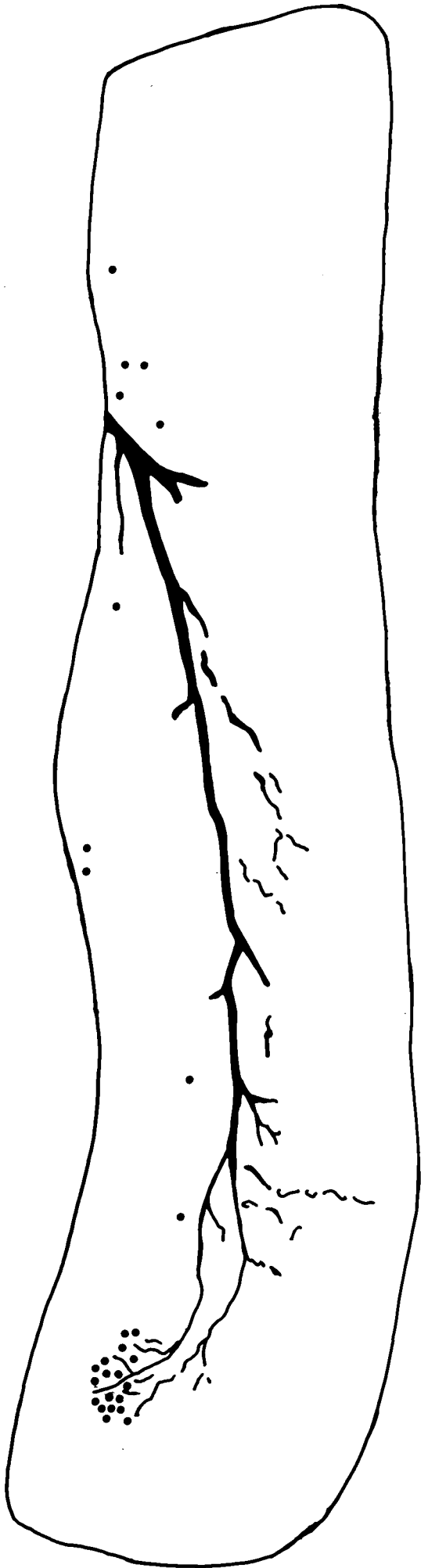
A count of myelinated axons was made from a micrograph (figure 8) of transverse plastic section (approx. 1  $\mu\text{m}$  thick) of masseteric nerve, cut from the region close to its entrance into the muscle and stained with toluidine blue. The nerve contained 2120 myelinated axons, maximum diameter 18.25  $\mu\text{m}$ .

### 2. Number and distribution of muscle spindles

One hundred and thirty four spindles were found in one deep masseter muscle. In transverse planes most spindles were located in the medial half and close to the medial face of the muscle, often in clusters (figure 9). The first cluster was located anteriorly, the second posteriorly and the others in the zygomatico-mandibular part. Some spindle capsules in the anterior cluster were fused together at their equatorial regions and enclosed two bundles of intrafusal fibres.

The spindles were evenly distributed in the origin-insertion

Figure 7. Schematic diagram of rat masseteric nerve traced from reconstruction of complete deep masseter muscle stained with silver (Holmes' silver-on-the-slide) to show its distribution in relation to the location of muscle spindles (filled circles) traced from a section close to the mid-belly of the muscle.



**Figure 8.** Photograph of a transverse plastic section (1  $\mu\text{m}$ -thick) of rat masseteric nerve stained with toluidine blue. The section was taken from a region close to the entry of the nerve into the muscle mass.



**Figure 9.** Diagram showing the number and distribution of muscle spindles in a deep masseter muscle of the rat, sectioned transversely from origin to insertion. Each filled circle indicates a spindle capsule at the equatorial region. Distances between the traced sections are equal (1 mm).

**Abbreviations:**

a : anterior

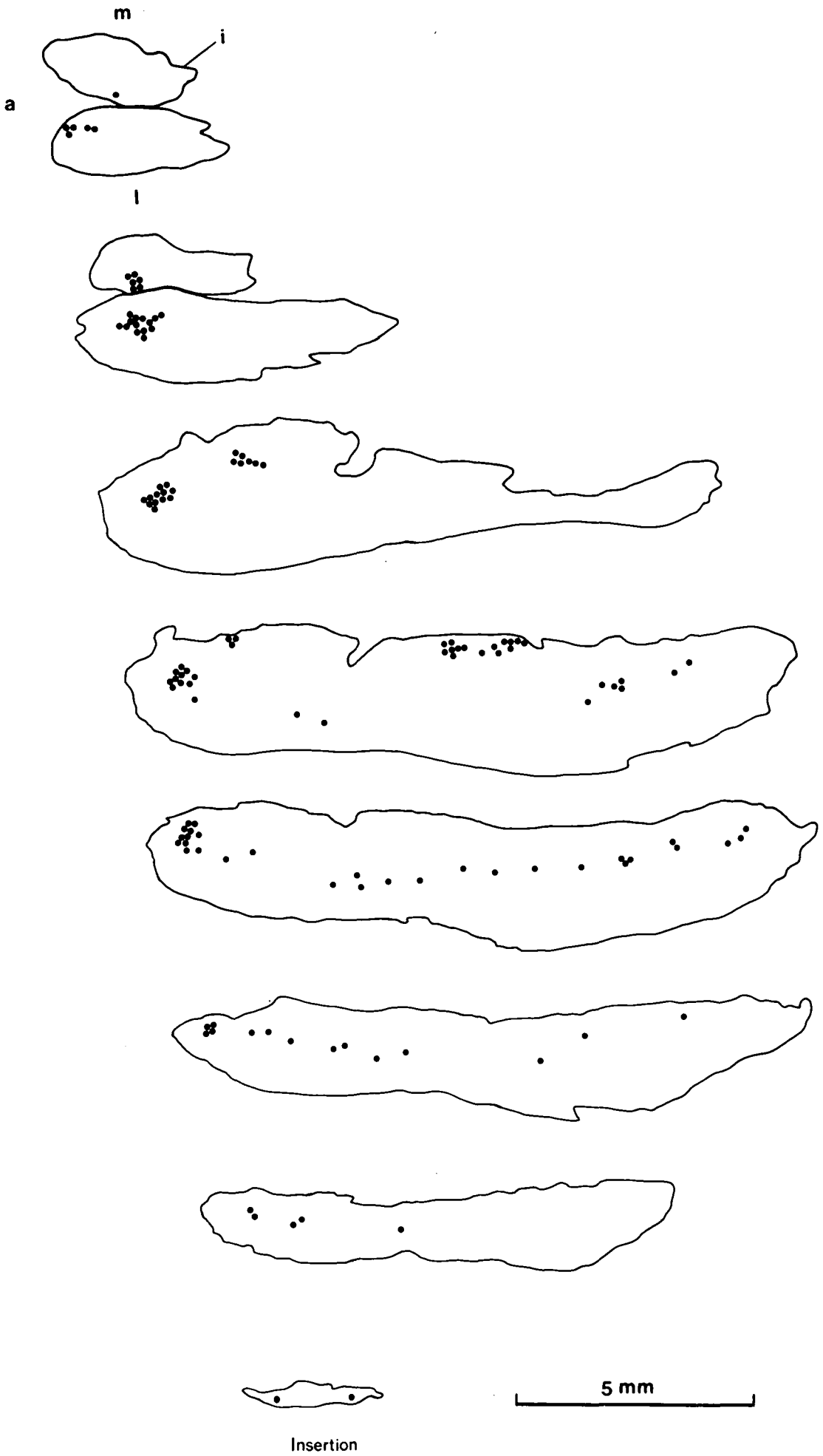
i : infra-orbital part

l : lateral side

m : medial side

9

Origin



direction (see Chapter VI).

No tendon organs were found in three deep masseter muscles, two of them embedded in paraffin wax and serially sectioned, one stained with the Weigert's and van Gieson method, the other with Holmes silver method. The third muscle was impregnated in silver according to the Barker and Ip method and completely teased.

### 3. Muscle fibre counts in deep masseter and digastric muscles of 6-week old male Wistar strain

The results of the fibre count were obtained from frozen sections of a deep masseter and digastric muscles from a male Wistar strain rat aged 6 weeks. These were stained with Weigert's iron haematoxylin and van Gieson or Sudan black B in propylene, photographed at 25 (magnification), and enlarged at  $\times 6$  to give a final magnification of  $\times 150$ .

#### Deep masseter excluding infra-orbital portion

One square mm samples were examined from a single muscle. They contained 1345, 1029, 1136 and 1131 fibres; the mean was 1160 fibres. The mean area of eight of the largest cross-sections of the muscle was  $56.08 \text{ mm}^2$ .

The total fibre population therefore was approximately  $56 \times 1160 = 64960$  fibres.

#### Deep masseter, infra-orbital portion

The entire fibre counts from two muscles were 6452 and 6427, mean 6440.

Hence, the total fibre population from all parts of the deep masseter muscle were as follows:

$$64960 + 6440 = 71400 .$$

Anterior digastric muscle

Entire count	Left 5382	} total = 10791
	Right 5409	

The estimated count obtained from the number of fibres in one square mm of cross section multiplied by the maximum cross-sectional area was  $1233 \times 9 = 11097$ .

This is +306 (2.8%) higher than the entire count.

Posterior digastric

Entire count left 3478

Estimated count =  $1067 \times 3.1 = 3307.7$

which is 170 (4.9%) less than entire count. Therefore, I conclude that the estimated counts are accurate to within 5% of the entire counts in 6-week-old muscles. The above results are summarized in Table 2.

9-month-old male August strain

The results of the fibre count from selected muscles of a 9-month-old male August strain rat are shown in Table 3; these were obtained using the same methods as above.

4-month-old male Wistar strain

The total counts were obtained from a frozen-section of anterior digastric muscle. This was fixed in formal-saline and stained with Sudan black B in 70% alcohol and enlarged  $\times 60$  (figure 10) (Hiimae's procedure, 1971). The counts were 6244 for the left side, and 6992 for the right side.

The counts of three separate sq. inches in the left anterior digastric of the above section, following Hiimae's convention (1971),

were 100, 166 and 204 fibres; the mean was 157.

The transverse section adjacent to the one used for these counts was fixed in glutaraldehyde, stained with the Weigert and van Gieson method and enlarged  $\times 150$ . Fibre counts were made in two and a half sq. inch areas equivalent to the sq. inch counts made on the  $\times 60$  montage (above), and obtained similar results as follows:

104, 163 and 212 fibres. The mean was 160.

The area measurement of the left anterior digastric in the  $\times 60$  montage was 45.2 sq. inch, therefore an estimated total number of fibres was  $157 \times 45.2 = 7096$  fibres. This figure is considerably higher than the actual total count of 6244 made from this montage but a fair approximation to it when interfascicular spaces, connective tissue and blood vessels are taken into the estimated account.

Table 2

Fibre counts from masseter and digastric muscles of a 6-week-old Wistar strain rat.

Muscle	No. of fibres per sq. mm	Total area (sq. mm)	Total no. of fibres	No. of samples
deep masseter excluding infra-orbital portion	1345 1029 1136 1131	56	64960*	4
deep masseter, infra-orbital portion	-	-	6452 6427	2
left and right anterior digastric	1233	9	L 5382 R 5409	1
left posterior digastric	1067	3.1	3478	1

\* estimated number:  $56 \times 1160 = 64960$

Table 3

Fibre counts from selected jaw muscles of 9-month-old male August strain rat.

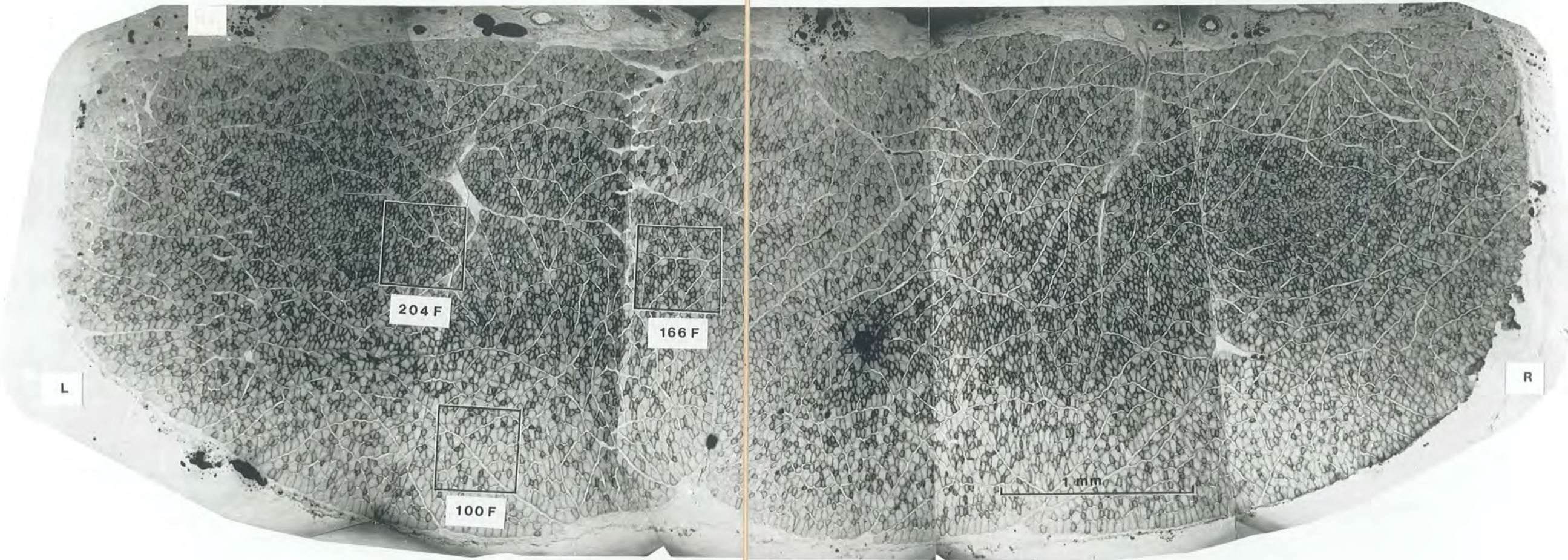
Muscle	Actual no. of fibres
infra-orbital	4663
right anterior digastric	5806
left anterior digastric	5227

**Figure 10.** Transverse cryostat section of anterior digastric (left and right) muscle of a four month old male Wistar rat, stained with Sudan black B in 70% alcohol and used to obtain the total count of muscle fibres. The three squares mark the samples, each of one square inch at the original magnification ( $\times 60$ ) that were used to assess the error involved in estimating the total number of muscle fibres in the deep masseter muscle (see text). The number of fibres in each sampled area is given below it. Arrows indicate the border between left and right digastric muscles.

**Abbreviations:**

- L : left digastric muscle
- R : right digastric muscle
- F : extrafusal muscle fibre





### C. Discussion

The decision to use Weigert's iron haematoxylin and van Gieson stains in this study was taken because they were more capable of giving a good contrast between the different structures in the muscle sections, from which it is easy to identify the muscle spindles (Lennartsson, 1980a).

Masseteric nerve, which innervates deep masseter muscle in the rat, penetrates the muscle mass on its medial aspect, between and separating the two parts of zygomatico-mandibular muscle, branching as it passes anteriorly (Karlsen, 1965; Weijs, 1973). I have found that these branches innervate the posterior masseter and zygomatico-mandibular portions of the muscle. A large branch continues to run horizontally ultimately to reach the anterior spindle-cluster, having subdivided on the way (see figure 7). This is in agreement with the descriptions of the above authors.

Karlsen (1969) calculated the mean number of myelinated fibres comprising the masseteric nerve (3 nerves) in the cat to be 1015, with a maximum diameter of 19  $\mu\text{m}$  for the largest fibres. No such information is available for the rat masseteric nerve, which would be of value and interest. In this part of the study I have found in toluidine blue stained plastic section 2120 myelinated axons, the maximum diameter of the largest axon was 18.25  $\mu\text{m}$  (see figure 8).

Figure 9 is a schematic representation of a complete reconstruction of rat deep masseter muscle, showing the number and distribution of all 134 muscle spindles found in that muscle. They were located close to the midline and dispersed from origin to insertion. Further counts were made of the total spindles in deep masseter in another part of this study (Chapter IV): 119 spindles were

found in one muscle and 86 in another. However on each occasion most were found grouped together (clustered), the anterior cluster consisting of about 40 spindles. Within the cluster some adjacent spindles were seen sharing a capsule and also appeared in complex forms (Richmond and Abrahams, 1975b; Eriksson and Thornell, 1985). Further details will be described below in Chapter VI.

Karlsen (1965) found 130 spindles in rat masseter muscle (deep and superficial), only 6 in the superficial muscle; Maier (1979) found 73-85 spindles in deep masseter muscle; Lennartsson (1980b) reports an average of 110 spindles found in 6 masseter muscles. All of these authors have reported that muscle spindles in deep masseter muscle were often in groups.

The findings made in this part of the present study confirm what the above authors have described concerning the number and distribution of muscle spindles in rat masseter muscle.

Lund *et al.* (1978) have described the presence of tendon organs in the cat masseter and temporalis muscles. The tendon organs were found in dyad arrangement with muscle spindles. In masseter muscle 6 tendon organs were found located near its origin, and 20 in temporalis muscle at its insertion into the coronoid process of the mandible.

There were no tendon organs in any of the three complete deep masseter muscles of the rat I have examined (two serially sectioned, one stained with Weigert's iron haematoxylin and van Gieson stains, the second with silver stain; the third impregnated with silver nitrate and completely teased).

To quantify the adrenergic innervation of rat deep masseter and anterior digastric muscle, the number of muscle fibres present in each must be known. Hiiemae (1971) gives the absolute muscle-fibre count of rat jaw muscles. Surprisingly this study (Chapter IV) found the number

of muscle fibres associated with adrenergic innervation in deep masseter and anterior digastric to be higher than the total number present in the muscle as reported by Hiimae. It therefore became essential to perform a fibre count myself for the muscles I was using.

The largest cryostat transverse sections from the middle of deep masseter and the anterior digastric muscles of 6-week-old rat stained with Weigert's iron haematoxylin and van Gieson stains were taken supposing all fibres comprising the muscle to be present. The total counts of the anterior digastric (left & right) muscle of the 6-week-old male Wistar rat I obtained were 5382 fibres for the left and 5409 fibres for the right. These compared with Hiimae's published (1971) total counts of three anterior digastric muscles of 3-9 month male August rats; left 1536 and 1211, right 1812. The estimated number of muscle fibres comprising the deep masseter muscle was 71400 (see the results). My counts are more than 3 times higher than Hiimae's counts for the above muscles. Concerning the variation in muscle fibre populations between strains of rat, I have obtained counts for anterior digastric (left & right) and the infra-orbital muscles of 9-month-old male August strain rat (see Table 3). The results were similar to those found in a 6-week-old Wistar strain rat.

The total number of muscle fibres comprising the anterior digastric muscle (left & right) of 4-month-old male Wistar strain rat [obtained by counting from a  $\times 60$  montage (figure 10) following Hiimae's method] were for left 6244, and for right 6992 fibres. These figures are close to those obtained from 6-week-old male Wistar rat in this study. On the other hand this result confirms Rowe and Goldspink's (1969) suggestion that mammalian muscle fibres do not increase in number after birth.

After much thought and discussion, it was concluded that the

explanation of the difference in results between my study and that of Hiimae must lie somewhere in the different methodologies followed in the two studies. There were two major differences:

1. Fixation and staining: Hiimae fixed in formal-saline and stained with Sudan black B; I fixed in glutaraldehyde and stained with Weigert's iron haematoxylin and van Gieson stains.
2. Photographic montage: Hiimae photographed at  $\times 5$  and enlarged to  $\times 60$ ; I photographed at  $\times 25$  and enlarged to  $\times 150$ .

In fibre counts of three separate square inches made on the  $\times 60$  montage (see figure 10), and in fibre counts made in  $2\frac{1}{2}$  square-inch area on the adjacent section, stained with Weigert's iron haematoxylin and van Gieson stains and montaged at  $\times 150$  (identical to the square-inch counts made on  $\times 60$  montage), the counts were similar to that made on the  $\times 60$  montage. Finally, the estimated total muscle fibre count obtained for this muscle was 7096 fibres, which is a fair approximation to the actual count of 6244 (see Results).

I had hoped that the undercounting might have been the Sudan black staining combined with the comparatively low-magnification montage. However, I found no difficulty in counting Sudan black stained fibres in the  $\times 60$  montage. Indeed, the contrast between pale and dark fibres is helpful and compensates for the smaller magnification. There is, therefore, no obvious alternative but to conclude that Hiimae made a systematic error in her counting.

CHAPTER IV

The adrenergic innervation of rat masseter and anterior digastric muscles

A. Introduction

The existence of non-myelinated nerve fibres in skeletal muscles and in the capsule wall and periaxial space of mammalian spindles has been long known (Barker, 1974). For example, after the degeneration of the somatic innervation of spindles, the vasomotor fibres were left intact (Hinsey, 1927), whereas such fibres were the only ones which degenerated in sympathectomized material (Hines and Tower, 1928).

Barker (1948) described fine axons in some spindles of rabbit that ran within the capsule wall and branched extensively in the polar regions to form a fine anastomosing network. He considered them to be group IV afferents. Later, Barker and Cope (1962b) noted similar axons in deafferented spindles of the cat and believed that they were most probably of sympathetic origin. Then, when trail endings had been identified, Barker (1967) considered those non-myelinated axons in spindles as preterminal trail axons. He found no evidence from observation by light microscopy to confirm that intrafusal muscle fibres received autonomic innervation.

However, physiological evidence showed that spindles could be affected by sympathetic stimulation, although it is unclear whether the effect was produced directly or indirectly by vasoconstriction (Eldred, Schnitzlein and Buchwald, 1960; Hunt, 1960). Previously Bowman and Zaimis (1958) had recorded an increased tension in cat tibialis anterior (fast) muscle after sympathetic stimulation and had attributed

it to vasoconstriction.

It later became clear that some mammalian muscle spindles are supplied by autonomic innervation. Banker and Girvin (1971) were able to observe nodules of fluorescent material running parallel and close to intrafusal muscle fibres in the equatorial region of dog gastrocnemius spindles using the histochemical technique of Falck, Hillarp, Thieme and Torp (1962). By electron microscopy they also observed small non-myelinated axons within the capsule wall, around small arterioles, and in the periaxial space. They believed that those small non-myelinated axons that contained both small and large granular vesicles were sympathetic nerve fibres, based on the characteristic presence of small granular vesicles similar to those known to contain norepinephrine in sympathetic axons (Bloom and Barrnett, 1966). At the same time Santini and Iбата (1971) obtained similar results in spindles of normal cat tenuissimus and deep lumbrical muscles after injecting 5-hydroxydopamine (5-HDA) to label the varicosities of terminals of sympathetic axons (Tranzer and Thoenen, 1967). Ballard (1978) also found histological evidence for a sympathetic innervation of spindles in cat tenuissimus muscle. Confusion arose when the suggestion was made that vasomotor axons may be involved, but was dispelled when Barker and Saito (1981) were able to demonstrate anatomically the presence of autonomic innervation in muscle spindles in cat hindlimb muscles which had been deprived of their somatic innervation by degeneration after spinal root section. Fluorescence microscopy, electron microscopy and teased silver preparations were used. Unmyelinated axons within the capsule wall and others associated with intra- and extrafusal muscle fibres could be seen. According to the types of vesicle, three types of axon were noted; noradrenergic, cholinergic and non-adrenergic, non-cholinergic. Not all spindles

received autonomic innervation.

Recent information published by Arbuthnott, Gladden and Sutherland (1982) suggests that cat bag<sub>2</sub> fibres receive cholinergic innervation and chain fibres receive adrenergic innervation. Furthermore, Swash and Fox (1985) suggested that some muscle spindles of baboon and human are supplied with autonomic innervation. Their observations were carried out on baboon de-efferented hindlimb muscles prepared for silver staining and on human abductor pollicis brevis muscle prepared for fluorescence microscopy, silver staining and other histological stains.

Passatore and Filippi (1981 and 1982) published physiological evidence which suggested that there was a direct sympathetic action on muscle spindles in jaw elevator muscles of anaesthetized and paralysed rabbits when the cervical sympathetic nerve was stimulated. Moreover, Passatore, Filippi and Grassi (1985) and Passatore, Grassi and Filippi (1985) observed a marked increase in tension in jaw elevator muscles of anaesthetized and paralysed rabbits, cats and rats when the cervical sympathetic nerve was stimulated unilaterally. A maximum tension of about 5 g was obtained in rabbits and about 1 g in cats and rats. No change in response was observed during the use of paralyzing agents or after section of somatomotor innervation to all masticatory muscles but the response was almost completely abolished by the  $\alpha$ -adrenergic blocking agent phentolamine. No such tension was produced in jaw-depressor muscles which contain few or no spindles in many species (Dubner, Sessle and Storey, 1978). Moreover, by studying the effect of the removal of individual muscles or parts of muscles Passatore *et al.* (1985) found that the contribution of each elevator muscle to the tension development was proportional to its estimated spindle content. The authors concluded that the tension might be ascribed to the



contraction of intrafusal muscle fibres and possibly to the similar contraction of a few extrafusal muscle fibres.

These conclusions were not generally accepted, since, although the measured tension was quite small it was considerably greater than the maximum tension that could be expected to be generated by intrafusal contraction (Boyd, 1976a). If the effect was real, therefore, some other mechanism must have accounted for it, perhaps a non-twitch tension generated by extrafusal muscle fibres.

The initial physiological observation made by Passatore *et al.* (1981, 1982) prompted me to investigate and quantify the adrenergic innervation associated with spindles and extrafusal muscle fibres in rat jaw muscles. Two muscles were chosen for the study; the deep masseter which is the most powerful of the jaw-closing muscles and contains about 100 spindles; and the anterior digastric, the main jaw-opening muscle which is usually devoid of spindles (Karlsen, 1965; Lennartsson, 1980b; Maier, 1979). Glyoxylic acid-induced fluorescence (König, 1979) has been employed to stain serial 20  $\mu\text{m}$  thick cryostat cross-sections of both muscles for localization of adrenergic axons. An abstract of the results has been published (Barker and Saed, 1987).

In a recent study Lund and Matthews (1987) showed that the anterior digastric muscle of anaesthetized and paralysed rabbits could develop tension when the cervical sympathetic trunk was stimulated, despite the lack of spindles.

## B. Results

### 1. Adrenergic innervation associated with spindles

In two deep masseter muscles 36 among 119 spindles (30%) in one muscle and 28 among 86 (32%) in the other were found to be adrenergically innervated. The anterior spindle clusters in the two muscles consisted of 34 spindles and 32 spindles, 13 and 12 of which respectively received adrenergic innervation. Spindles that received adrenergic innervation were scattered throughout the muscle (figure 11d), though the percentage appeared to be higher in the anterior cluster than elsewhere. No intrafusal fibre appeared to have received adrenergic innervation, in contrast to the cat (Barker and Saito, 1981). However, fine axons in the form of varicose threads that usually originated from adjacent perivascular axons occurred in the equatorial region of these spindle capsules; typical examples are shown in figures 12-15.

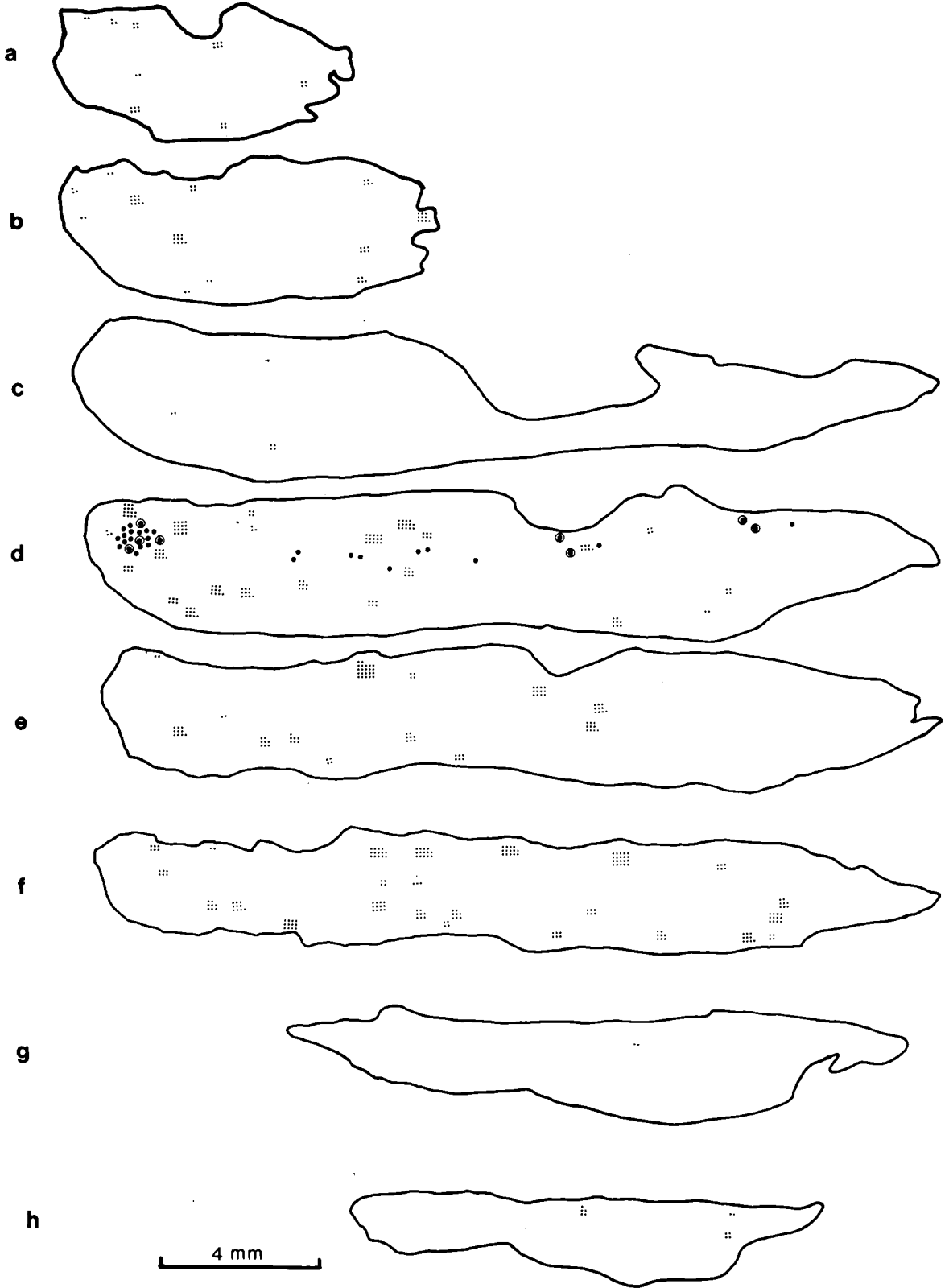
To confirm that the adrenergic axons supplied the capsule wall, the equatorial region of some spindles of the anterior cluster were examined by electron microscopy. Thin unmyelinated nerve fibres were observed within the capsule wall (figures 16 and 17) similar to those described by Banker and Girvin (1971) and Santini and Ibata (1971).

They were enclosed singly or in small groups by Schwann-cell cytoplasm, but none happened to be sectioned through a varicosity and therefore their vesicular contents could not be characterised.

### 2. Adrenergic innervation associated with extrafusal muscle fibres of deep masseter and anterior digastric muscles

Examination of serial cross-sections of one complete deep masseter

**Figure 11.** Schematic diagram of representative transverse sections of left deep masseter muscle of rat taken at equal distances apart (220  $\mu\text{m}$ ), and treated with glyoxylic acid. Sites of adrenergic innervation associated with extrafusal muscle fibres are shown as small dots, each dot indicating one extrafusal muscle fibre. The number and position of muscle spindles is given in diagram d only. Each muscle spindle is shown as a large dot, which is enclosed by a circle if the muscle spindle received an adrenergic innervation.



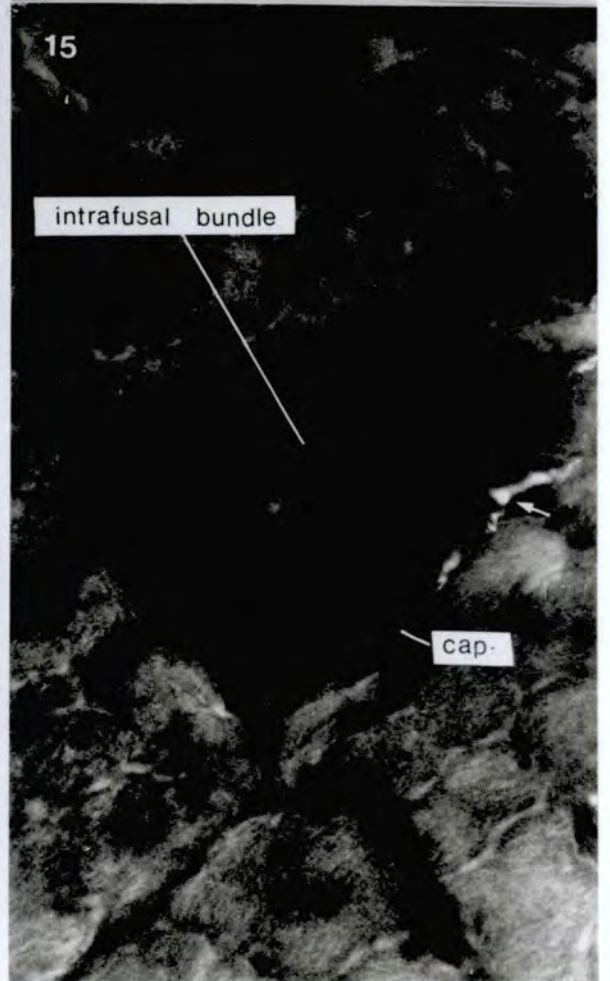
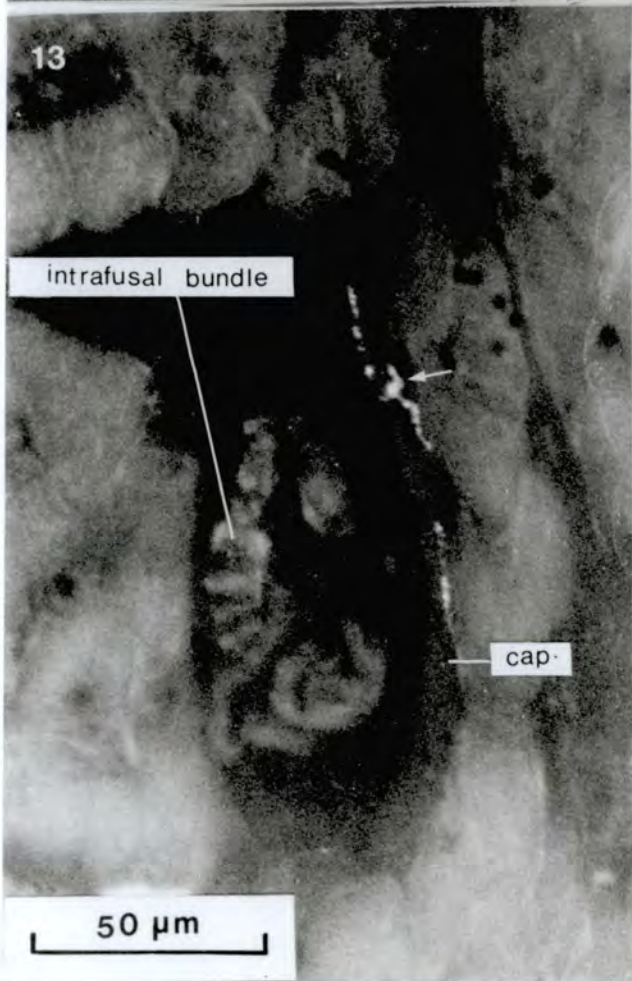
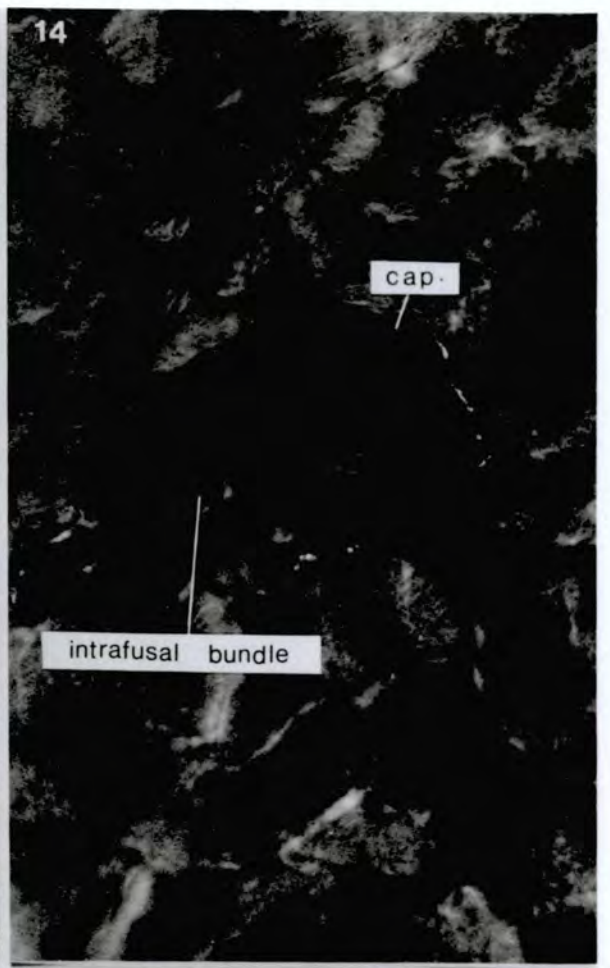
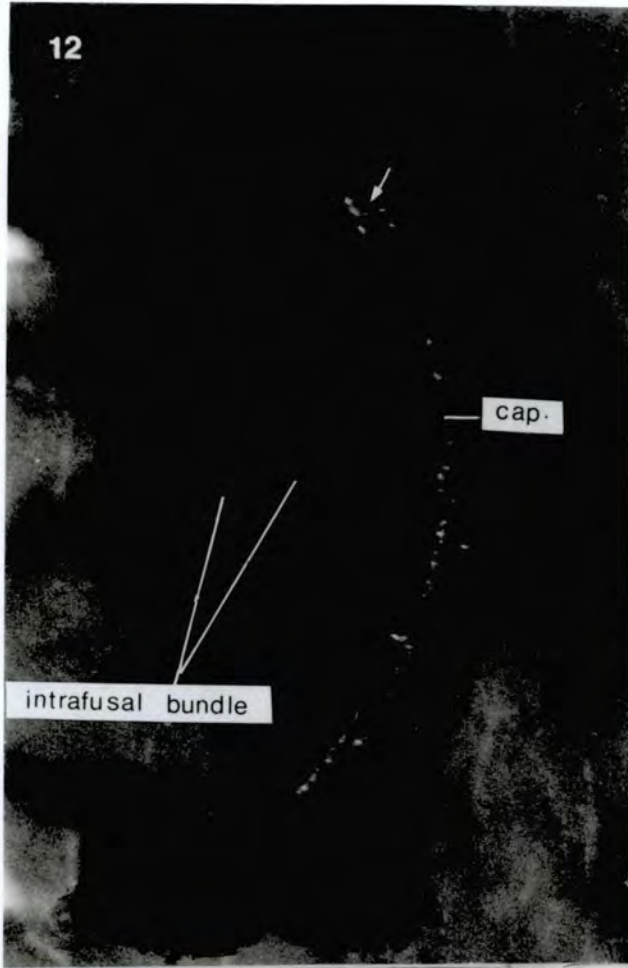


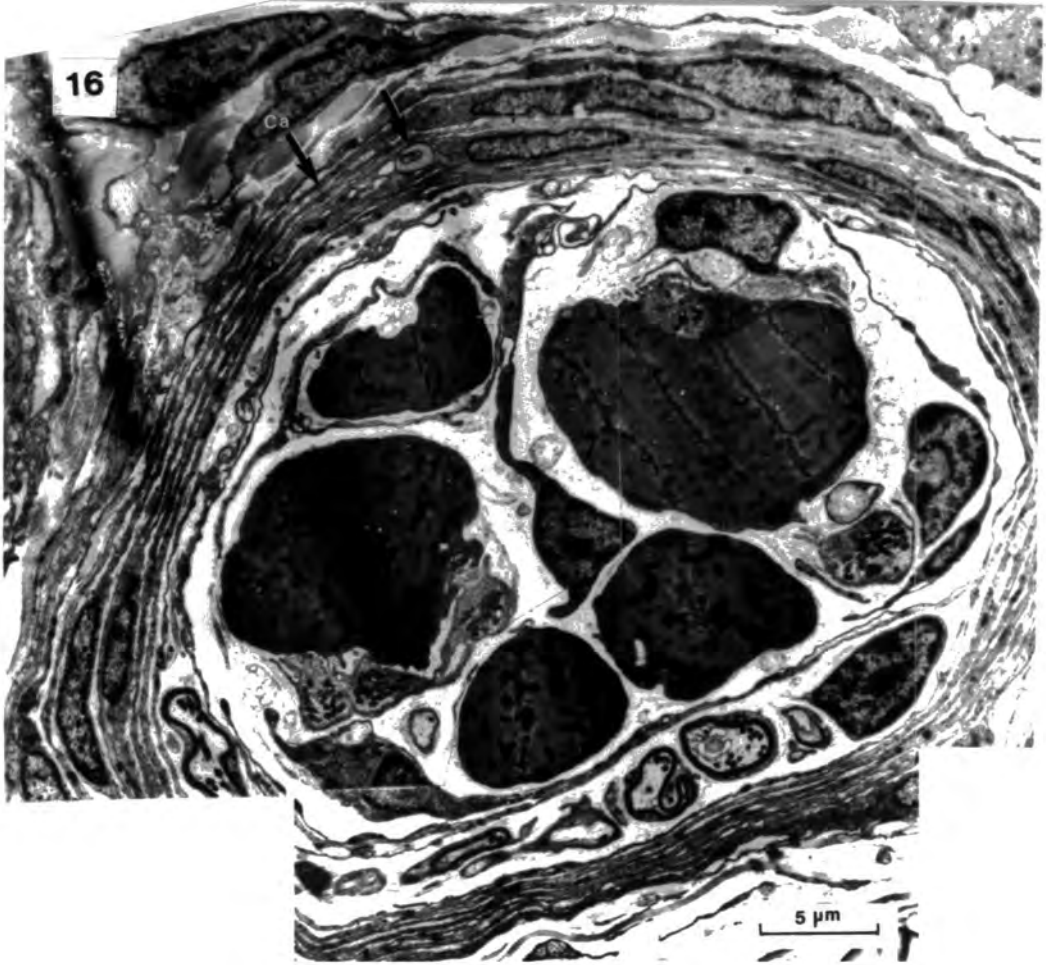
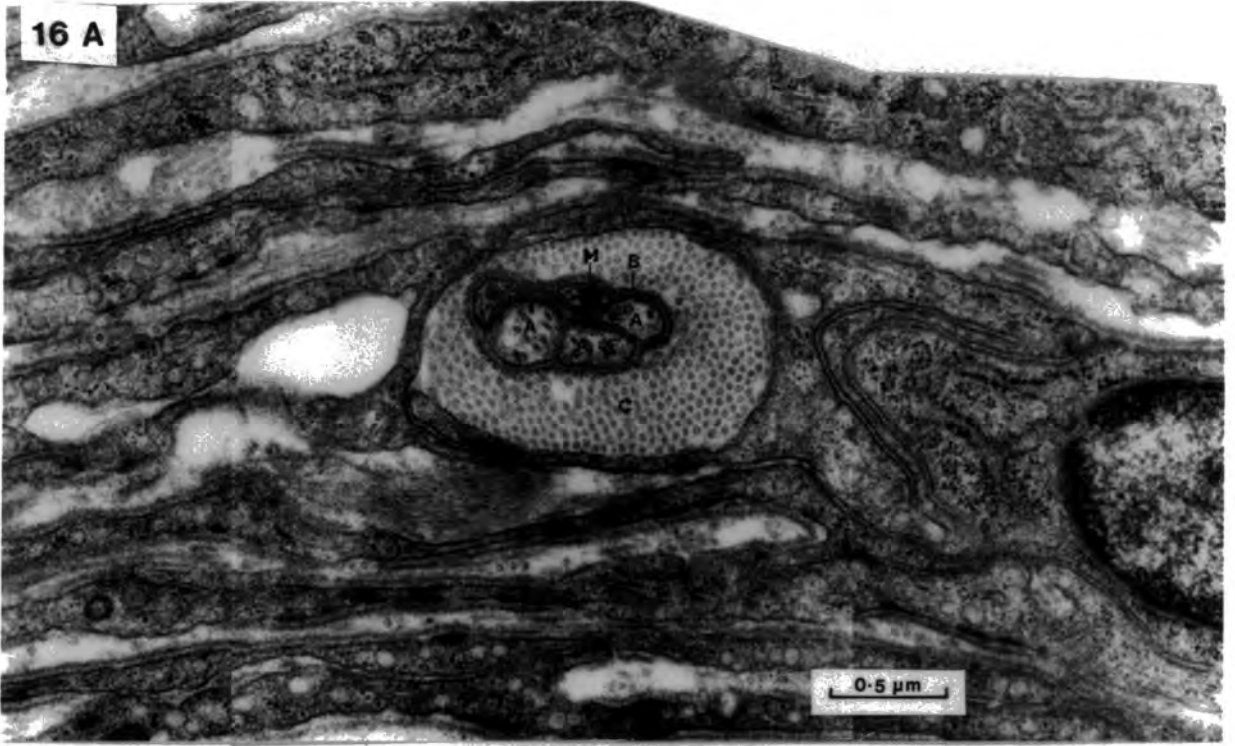
PLATE 1

**Figure 16.** Electron micrograph of a thin transverse section of a muscle spindle of rat masseter muscle, sectioned through the capsular sleeve (B) region. The three smaller intrafusal fibres are chains, the other two are bag fibres. A bundle of three unmyelinated axons (arrow) is seen located within the capsule lamellae.

Figure 16A. At higher magnification the three unmyelinated axons (A) are shown embedded within the cytoplasm of a single Schwann cell surrounded by collagen fibrils (C). Microtubules are visible in the axons.

**Abbreviations:**

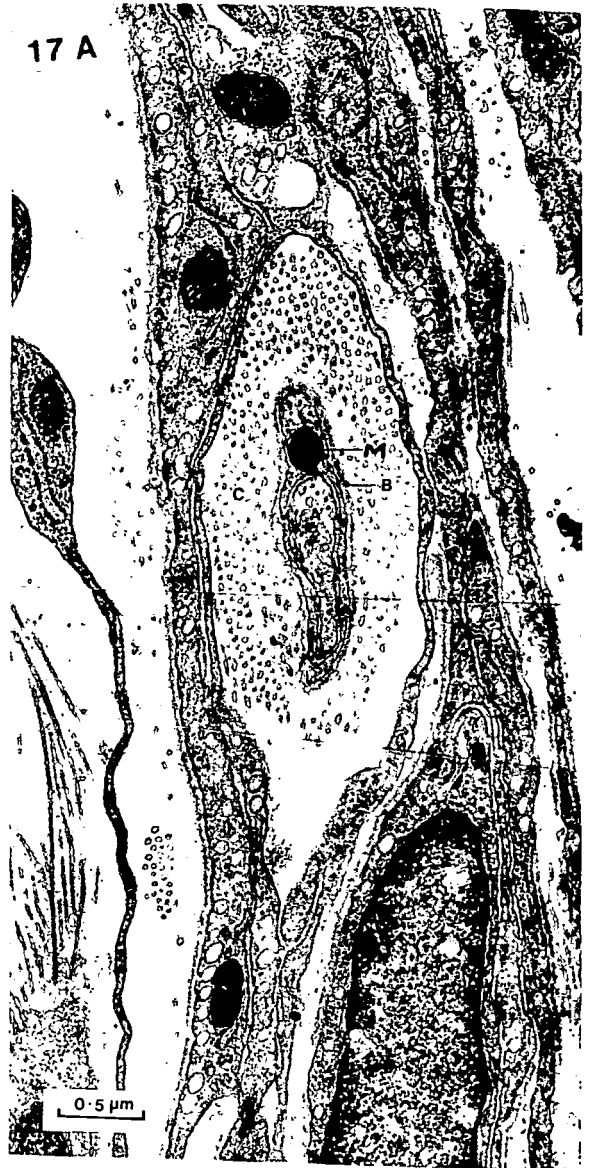
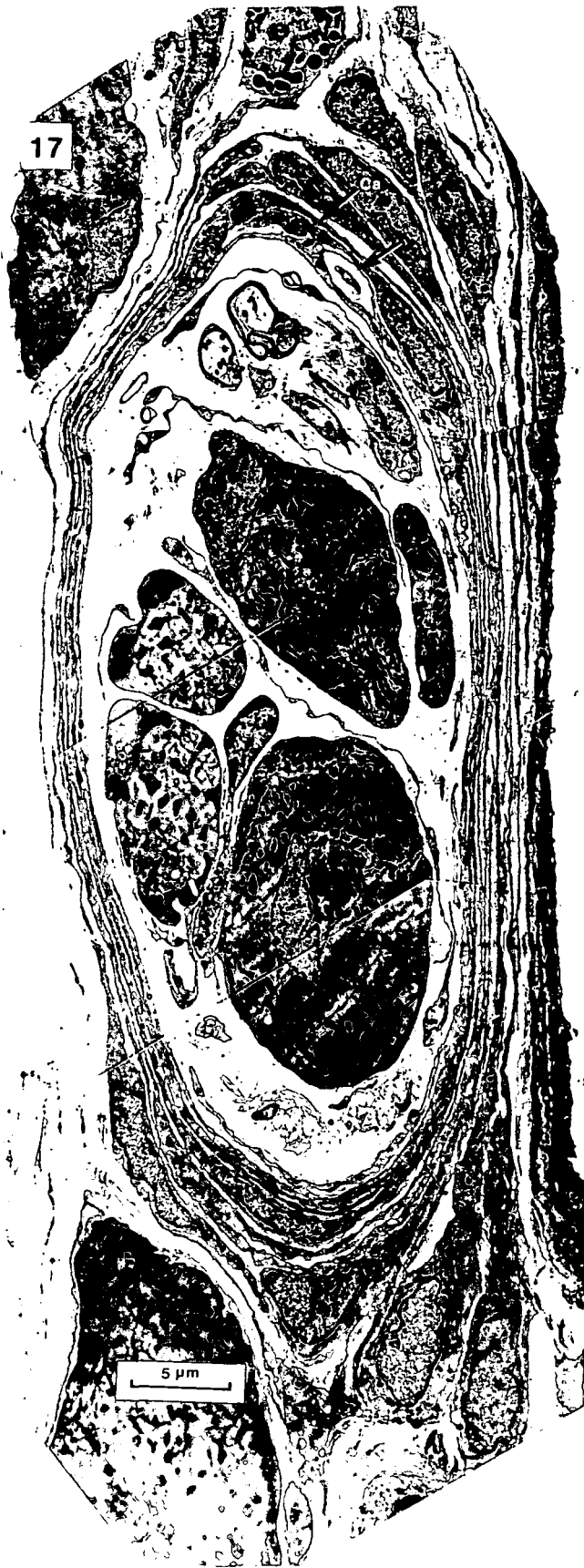
- A : axon
- B : basal lamina of Schwann cell
- C : collagen fibrils
- Ca : capsule wall
- M : mitochondria



**Figure 17.** Electron micrograph of a thin transverse section of a muscle spindle of rat masseter muscle, sectioned in the capsular sleeve (B) region. The three smaller intrafusal fibres are chains, the other two are bag fibres. An unmyelinated axon (arrow) is seen located between capsule lamellae.

Figure 17A. At higher magnification the unmyelinated axon (A) embedded within the cytoplasm of a single Schwann cell surrounded by collagen fibrils (C). In the axon cross-sectioned microtubules are present. Abbreviations as in figure 16.





muscle and one anterior digastric muscle treated with glyoxylic acid revealed that both muscles possessed some extrafusal muscle fibres that were adrenergically innervated, as indicated by the presence of green-fluorescent fibres. Two forms of innervation were observed clearly associated with extrafusal muscle fibres; the first was a branch around one extrafusal muscle fibre, situated very close to the perivascular innervation of an arteriole (figure 18). The second was a branch of an adrenergic nerve running between extrafusal muscle fibres, but not associated with blood vessels (figures in plates 2-4).

It has been assumed that there is no more than one instance of adrenergic innervation occurring per muscle fibre; this was the case when 28 individual deep-masseter fibres were traced over lengths of 4 mm (figures 24, 25 and figures, plate 4).

### 2.1. Deep masseter muscle

The results of the count made of the number of extrafusal muscle fibres associated with adrenergic innervation in every eleventh section are shown in Table 4 and in figure 5. The highest number of such innervation seemed to be in the middle part of the muscle (figure 11).

Estimates of the number of extrafusal muscle fibres associated with autonomic innervation in the 200  $\mu\text{m}$  intervals between these sections were based on actual numbers of associations present in samples of 10 serial 20  $\mu\text{m}$ -thick cross-sections that were obtained from 4 different levels in the muscle (shaded in figure 5), spaced 1-2 mm apart. The count is shown in Table 5.

The principle of the estimation was that the mean value of the number of associations for a given sample would be assigned to each of the ten sections preceding any section whose known value fell within the range of the sample. Inevitably, however, the principle could not

**Table 4**

Numbers of extrafusal muscle fibres associated with autonomic innervation counted (A) in 45 transverse sections at 220  $\mu\text{m}$  intervals of deep masseter, and estimated as described in the text, (B) in the 10 sections preceding each numbered section.

Section No.	A	B	Section No.	A	B
1	-	-	24	194	1900
2	-	-	25	105	1050
3	-	-	26	139	1900
4	7	270	27	49	270
5	31	270	28	168	1900
6	2	270	29	193	1900
7	75	1050	30	185	1900
8	10	270	31	78	1050
9	20	270	32	280	1900
10	67	270	33	351	1900
11	6	270	34	83	1050
12	-	-	35	2	270
13	10	270	36	59	270
14	-	-	37	-	-
15	6	270	38	42	270
16	38	270	39	6	270
17	24	270	40	11	270
18	10	270	41	47	270
19	20	270	42	-	-
20	173	1900	43	-	-
21	28	270	44	-	-
22	32	270	45	-	-
23	62	270	Total	2613	25610

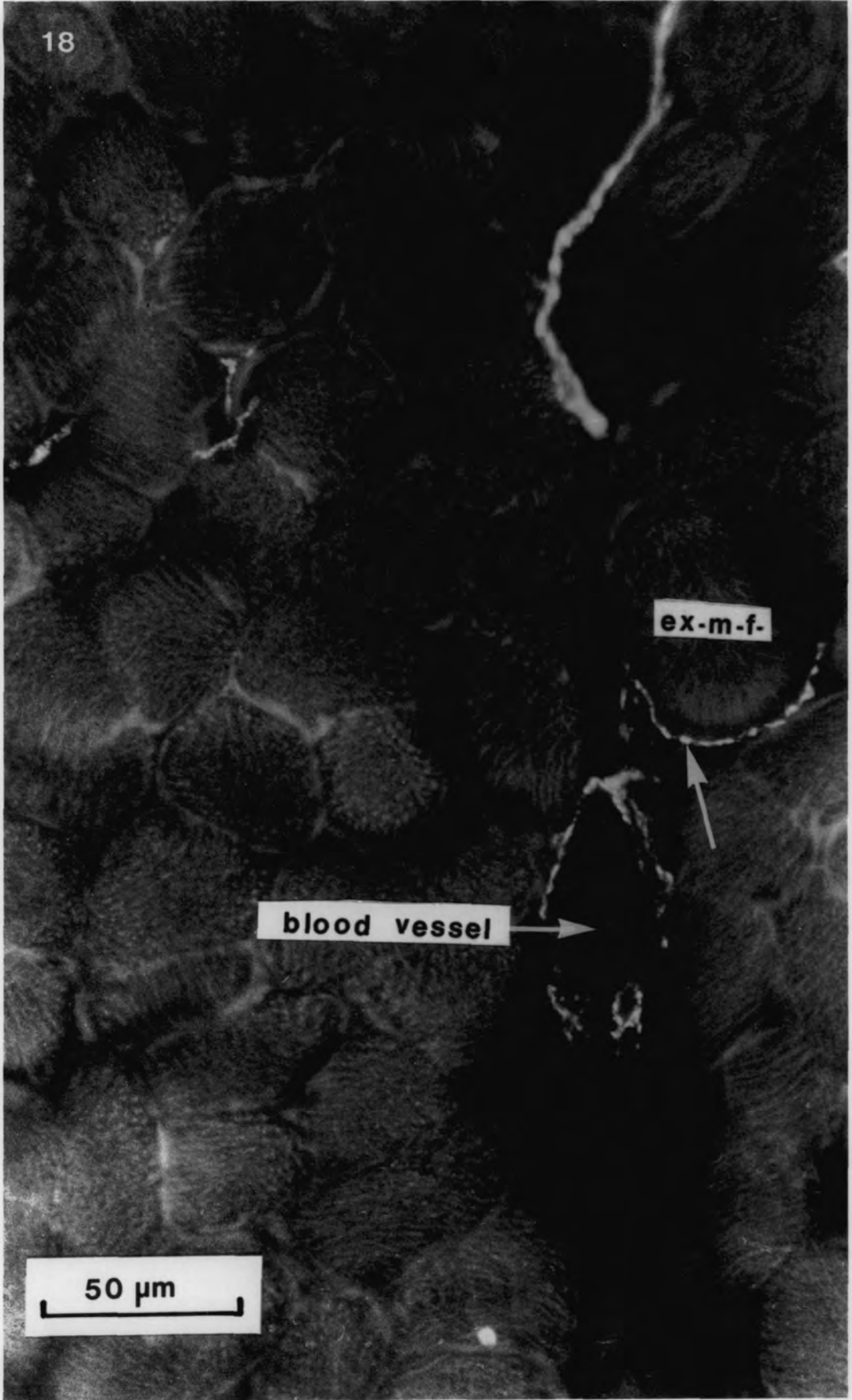
**Table 5**

Counts of extrafusal muscle fibres of deep masseter muscle associated with autonomic innervation (F) obtained from four samples each of ten serial transverse sections (20  $\mu$ m thick).

	Section No.	F		Section No.	F
<u>Sample 1</u>	1	86	<u>Sample 3</u>	1	156
<u>range:</u> 74-168	2	132	<u>range:</u> 122-276	2	276
	3	80		3	248
	4	78		4	219
	5	128		5	122
	6	74		6	151
	7	92		7	150
	8	93		8	135
	9	122		9	264
	10	<u>168</u>		10	<u>180</u>
	total =	1053		total =	1901
	mean =	105.3		mean =	190.1
<hr/>			<hr/>		
<u>Sample 2</u>	1	19	<u>Sample 4</u>	1	15
<u>range:</u> 14-66	2	29	<u>range:</u> 10-37	2	18
	3	14		3	21
	4	51		4	29
	5	66		5	31
	6	33		6	13
	7	35		7	10
	8	22		8	11
	9	45		9	37
	10	<u>34</u>		10	<u>10</u>
	total =	348		total =	195
	mean =	34.8		mean =	19.5

**Figure 18.** Transverse section (20  $\mu\text{m}$  thick) of rat deep masseter muscle treated with glyoxylic acid. Arrow indicates a branch of a perivascular adrenergic axon that appears to terminate among extrafusal muscle fibres.

18



ex-m-f.

blood vessel

50 μm

## Plate 2

Figures 19-21. Photographs of adrenergic innervation associated with extrafusal muscle fibres in rat deep masseter as revealed by glyoxylic acid-induced fluorescence in 20  $\mu\text{m}$  thick transverse sections showing typical examples of the axon branches (arrows) running transversely among the extrafusal muscle fibres in the form of varicose threads. Note there are no blood vessels nearby.

Figures 20 and 21 were serial sections. In the top right of figure 20 a small branch of the axon present in figure 21, and consisting of three varicosities (arrow), appeared in close association with the extrafusal muscle fibre marked by an asterisk.

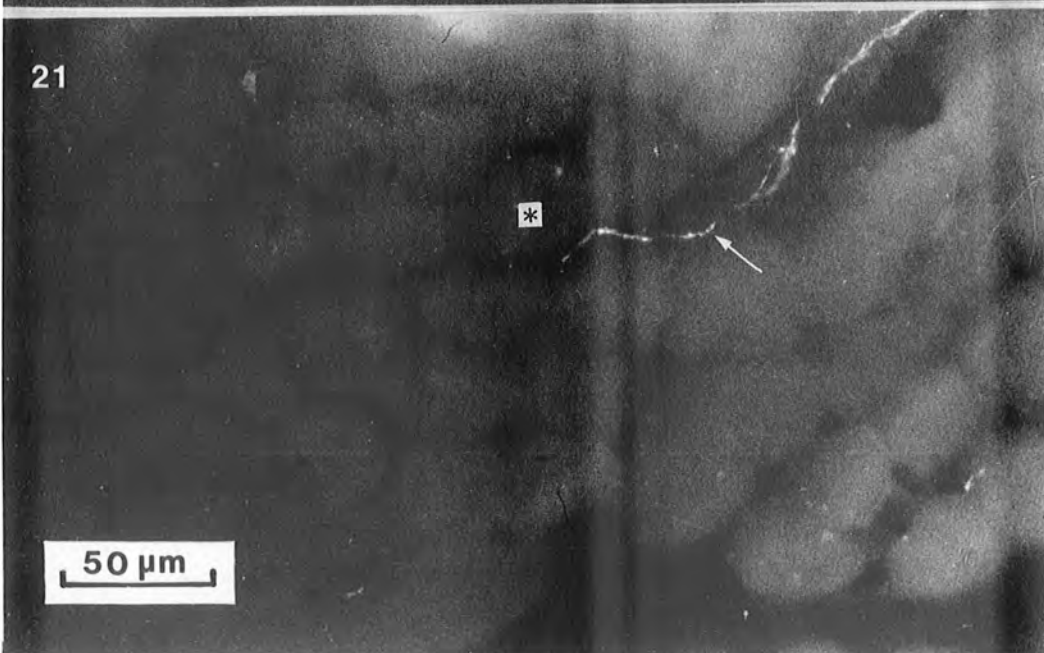
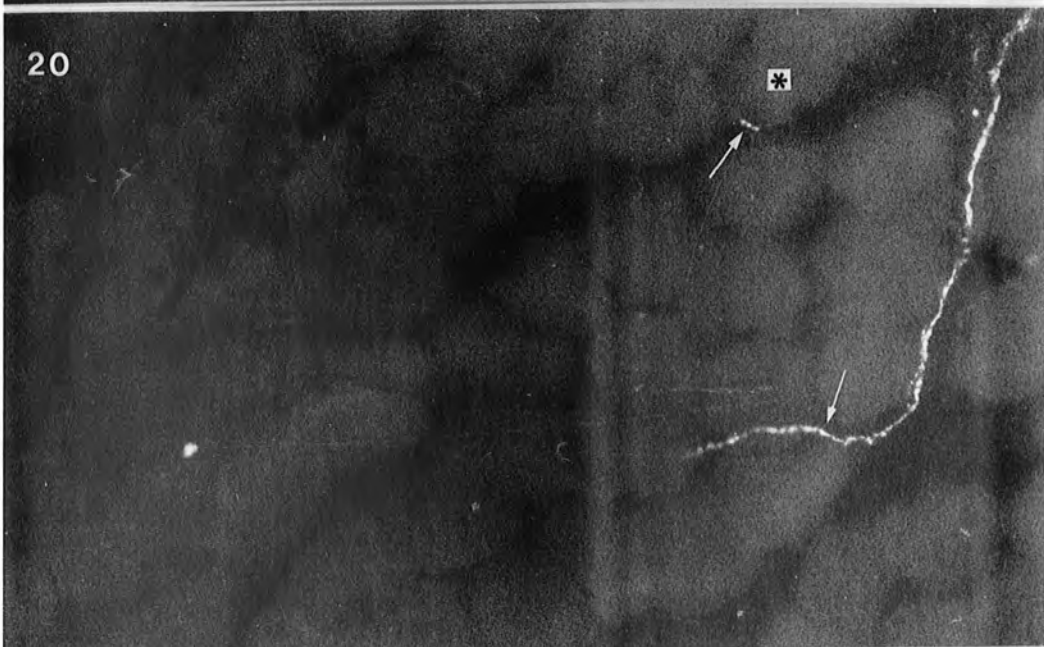
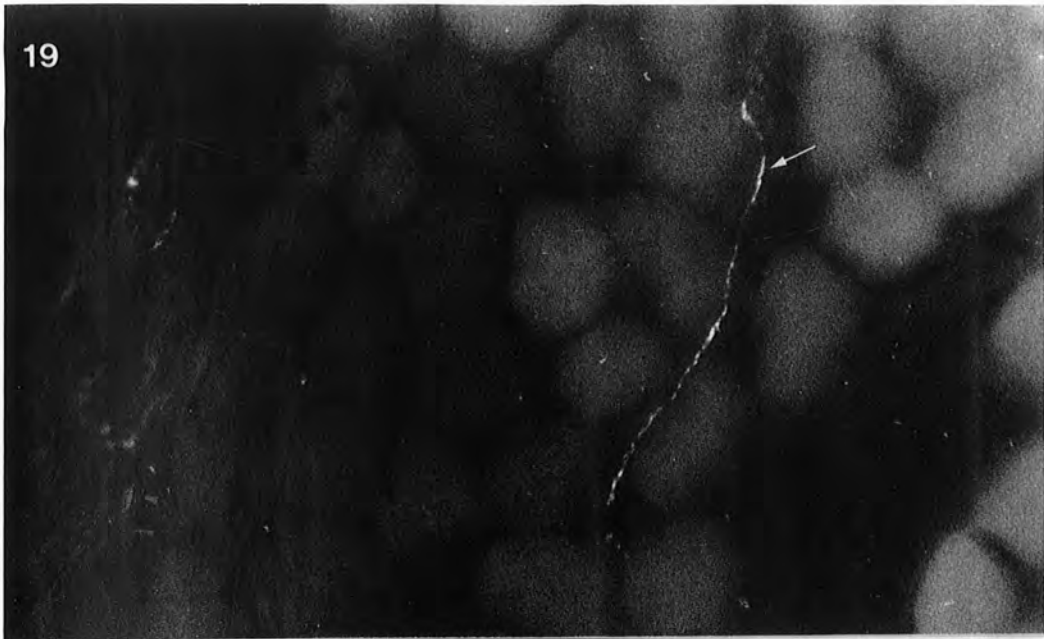

PLATE 2



Plate 3

Figures 22-25. Photographs of 20  $\mu\text{m}$  cryostat transverse sections of deep masseter muscle treated with glyoxylic acid showing varicosities of small axons (arrows) in association with extrafusal muscle fibres, and running obliquely or transversely with respect to the long axes of the extrafusal muscle fibres.

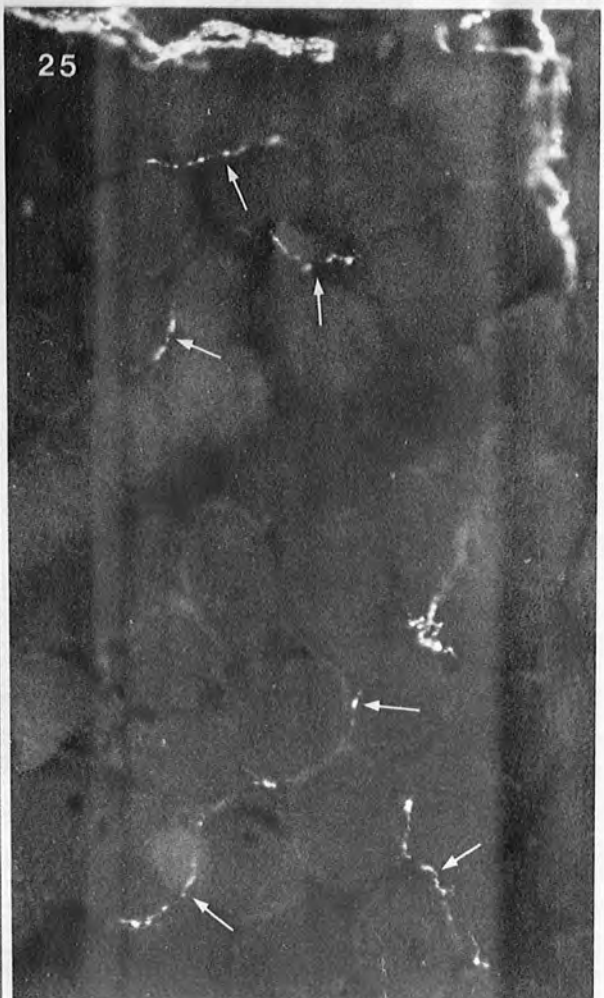
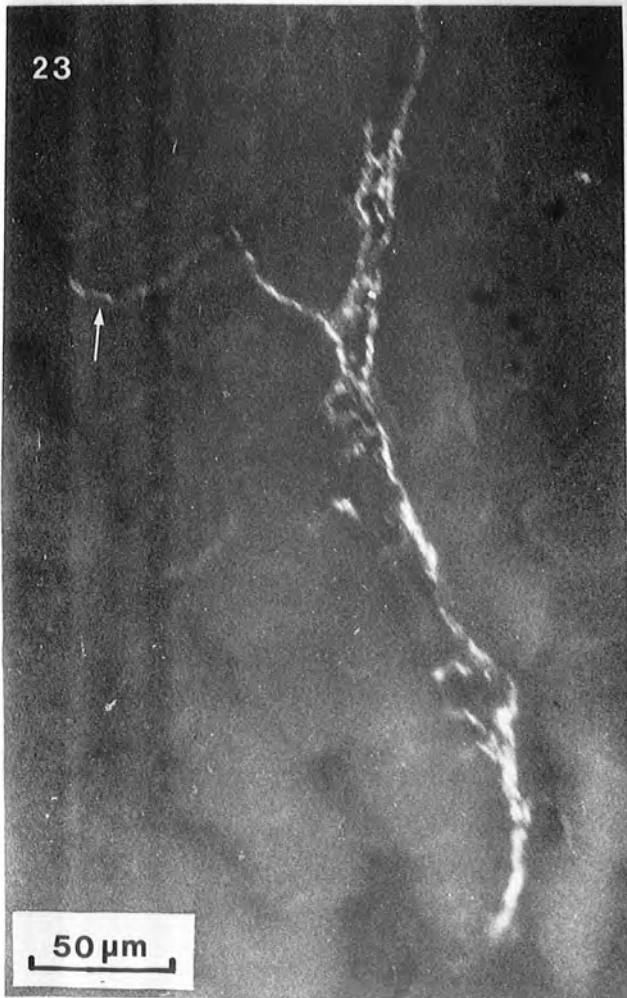
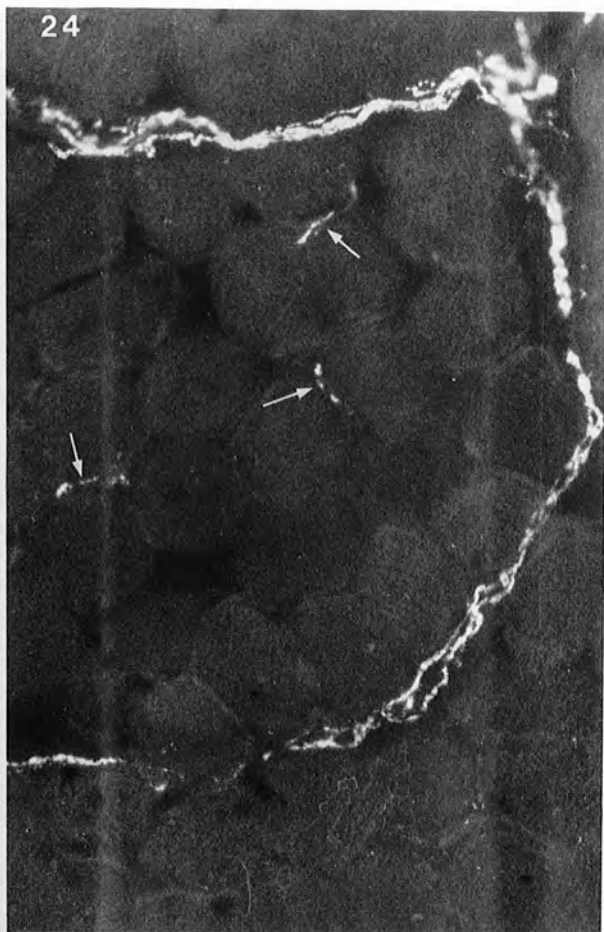
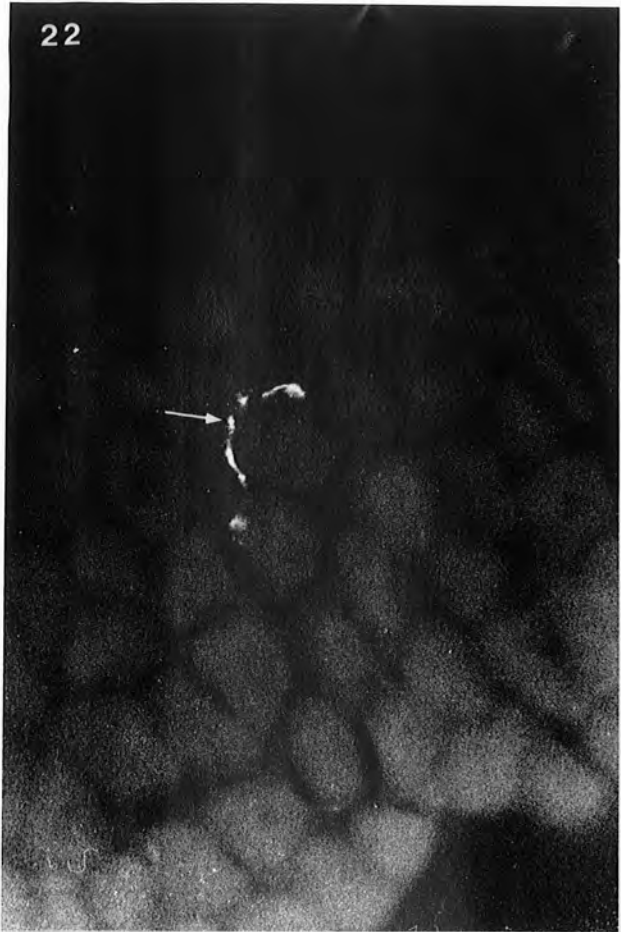

PLATE 3

#### Plate 4

Figures 26-31. Photographs of serial 20  $\mu\text{m}$  thick cryostat cross-sections of deep masseter muscle treated with glyoxylic acid. The varicosities of two adrenergic axons (arrows) run obliquely among and in close association with extrafusal muscle fibres (A,B,C) and (D,E,F). The large separation of the two groups of muscle fibres in figure 29 is artefactual.

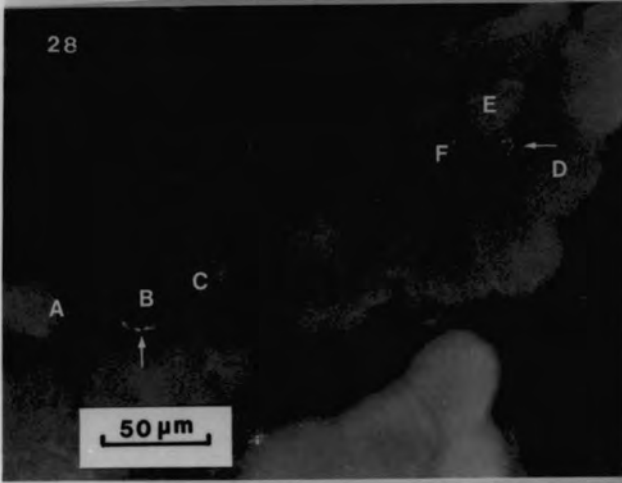
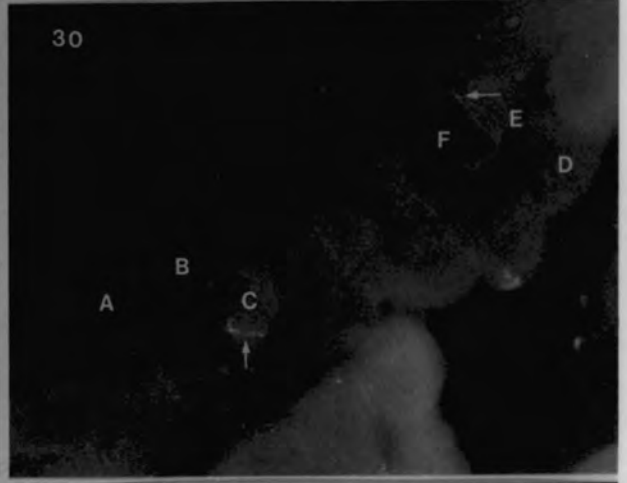
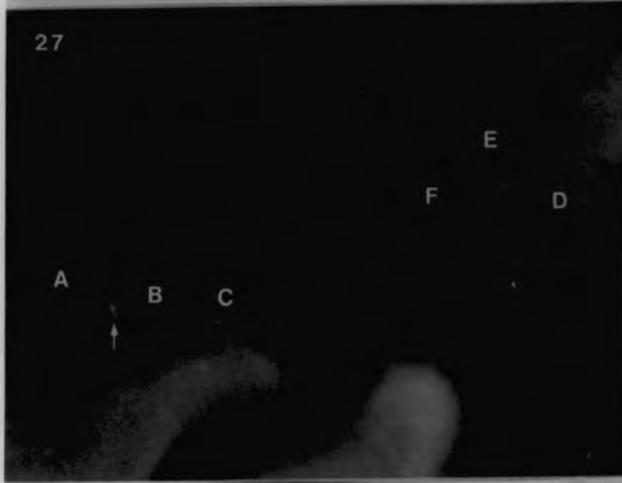
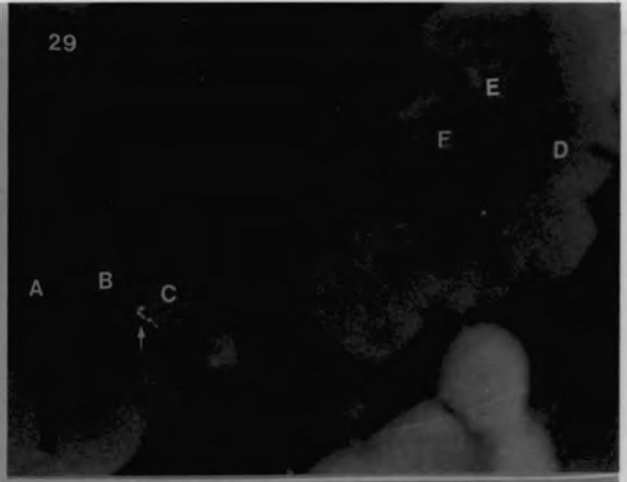
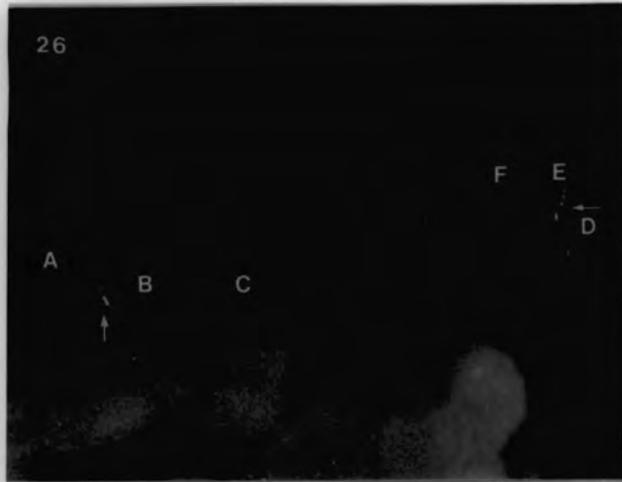

PLATE 4

be completely observed, so that it was necessary to make arbitrary decisions. Thus samples 2 and 4 were combined because their ranges overlapped considerably and neither exceeded a value of 70, which was taken as their upper limit. The sample 1 mean of 105 associations was assigned to sections adjacent to those whose known values ranged from 71 to 130. Finally the sample 3 mean of 190 associations was assigned to sections adjacent to those whose known values ranged from 131 upwards. The relevant estimated values are included in Table 4. The allocation of interval counts on this basis would add an estimated 25610 associations to the 2613 that were actually counted, and produce a total estimate of 28,223 extrafusal muscle fibres being associated with adrenergic innervation. Out of a total population of 71400 fibres (see p. 32) this is a proportion of 40%.

## 2.2. Left anterior digastric muscle

The number of extrafusal muscle fibres associated with adrenergic innervation was determined for the left anterior digastric muscle by the same method. The results are shown in Table 6 and in figure 6.

Samples of ten serial 20  $\mu\text{m}$  thick cross-sections were taken at 4 different levels (shaded in figure 6), and the counts obtained are shown in Table 7.

Adrenergic innervation frequency figures for all intervening sections were then allocated on the basis of the mean values of the sample counts as follows:

**Table 6**

Numbers of extrafusal muscle fibres associated with autonomic innervation counted (A) in 41 transverse sections at 220  $\mu\text{m}$  intervals of anterior digastric and estimated as described in the text, (B) in the 10 sections preceding each numbered section.

Section No.	A	B	Section No.	A	B
1	-	-	22	28	271
2	-	-	23	31	343
3	-	-	24	40	343
4	-	-	25	21	271
5	-	-	26	14	152
6	-	-	27	4	152
7	-	-	28	13	152
8	-	-	29	-	-
9	-	-	30	8	152
10	-	-	31	-	-
11	2	152	32	-	-
12	1	152	33	-	-
13	-	-	34	-	-
14	6	152	35	-	-
15	-	-	36	-	-
16	10	152	37	-	-
17	-	-	38	-	-
18	-	-	39	-	-
19	18	152	40	-	-
20	8	152	41	-	-
21	-	-	Total	204	2748

**Table 7**

Counts of extrafusul muscle fibres of anterior digastric muscle associated with autonomic innervation (F) obtained from four samples each of ten serial transverse sections (20  $\mu$ m thick).

	Section No.	F		Section No.	F
<b><u>Sample 1</u></b>	1	10	<b><u>Sample 3</u></b>	1	45
	2	16		2	44
	3	14		3	41
	4	8		4	39
	5	5		5	30
	6	16		6	33
	7	27		7	41
	8	14		8	10
	9	16		9	28
	10	<u>26</u>		10	<u>32</u>
	total =	152		total =	343
mean =	15.5	mean =	34.3		
<b><u>Sample 2</u></b>	1	12	<b><u>Sample 4</u></b>	1	30
	2	15		2	48
	3	12		3	21
	4	4		4	12
	5	31		5	22
	6	26		6	25
	7	51		7	42
	8	51		8	29
	9	34		9	24
	10	<u>35</u>		10	<u>18</u>
	total =	271		total =	271
mean =	27.1	mean =	27.1		

<u>associations/section</u>	<u>assigned number of associations for preceding 10 sections</u>
1-20	152
21-30	271
31-50	343

The estimated total number of extrafusal muscle fibres associated with adrenergic innervation becomes  $204 + 2748 = 2952$ . Since the entire fibre count for the left anterior digastric was 5382 (see p. 33), the proportion associated with adrenergic innervation can be estimated at 55%.



### C. Discussion

Until the beginning of the 1970s, no clear anatomical evidence was available to confirm the physiological observations as to whether or not there exists an autonomic nerve supply to the spindle. Banker and Girvin (1971), using electron microscopy and histochemical techniques, were able to demonstrate the presence of non-myelinated axons within the muscle spindles of dog gastrocnemius muscle. At the same time Santini and Ibata (1971) published clear evidence of fine unmyelinated axons within the spindles of normal cat tenuissimus and lumbrical muscles when they employed Tranzer and Thoenen's (1967) technique by injecting animals with 5-hydroxydopamine to exhibit the dense vesicles with the aid of electron microscopy. Moreover, Ballard (1978) described a typical sympathetic nerve found in the capsule wall and another two in the fluid space a distance of 2.1 mm from the equator of a cat tenuissimus muscle spindle.

Doubt was finally dispelled when Barker and Saito (1981) gave a full description of the intrafusal autonomic innervation in the cat. However, they found that not all spindles in cat hindlimb muscles were supplied with autonomic innervation, and that the frequency of spindles receiving such innervation was highest in the lumbricals and lowest in peroneus brevis. They employed the Falck-Hillarp technique (Falck *et al.*, 1962), and made their observations with the aid of fluorescent microscopy searching for axons which showed catecholamine fluorescence.

The histological work in this study was initiated in order to reveal the adrenergic innervation in rat jaw muscles, and to confirm the physiological observations made by Passatore *et al.* (1981 & 1982). Moreover, during the course of the study Passatore *et al.* (1985) claimed to have observed a maximum tension of about 5g in rabbit and

about 1g in cat and rat jaw elevator muscles when the cervical sympathetic nerve on one side was stimulated in anaesthetized and paralyzed animals. The authors attributed this tension to contraction of intrafusal muscle fibres and a few extrafusal muscle fibres (see the Introduction).

König's (1979) technique for glyoxylic acid-induced fluorescence in the autonomic nerves was used subsequently, figures 12-15 illustrating the form of adrenergic axons supplied to the capsule wall of some spindles in deep masseter muscle. It was always located equatorially and usually originated from the adjacent perivascular axons. This is in general agreement with Banker and Girvin (1971); Barker and Saito (1981); and Swash and Fox (1985). Those authors in their studies, carried out in dog, cat and man respectively, found nodules of fluorescent material in periaxial spaces, and in association with intrafusal muscle fibres. However, in the present study I found green-fluorescent varicosities neither in the periaxial spaces nor close to intrafusal muscle fibres in region B of any of the spindles examined. The reason for this absence is most probably attributable to the small size of unmyelinated axons in rat spindles in contrast with that in cat spindles. Alternatively, the absence might be due to species differences.

With the aid of an electron microscope, I have observed small unmyelinated axons running into the wall of the outer capsule of some spindles in the sleeve (B) region (see figures 16 & 17). These axons did not show small dense-cored vesicles, because the rat was not treated with 5-hydroxydopamine. This result is similar to that described by Santini and Ibata (1971), Banker and Girvin (1971). Hence there is no doubt that the fluorescent materials observed among capsule lamellae of some rat spindles in this study by using the glyoxylic acid

were due to autonomic axons.

The present study with serial 20  $\mu\text{m}$  thick sections treated with glyoxylic acid revealed the autonomic axons running close to some extrafusal muscle fibres in both deep masseter and anterior digastric muscles (figures 18-31). Figure 18 shows an example of adrenergic branching of a perivascular axon associated with extrafusal muscle fibres. Figures 19, 20 and 21 show typical examples of adrenergic axons among the extrafusal muscle fibres, with no blood vessels around. Using serial sections gave the advantage of being able to follow the adrenergic axon to see whether it was running in walls of blood vessel or among extrafusal muscle fibres. These findings were similar to those described for cat hind limb muscles (Barker and Saito, 1981).

Although Passatore *et al.* (1985) attributed that amount of tension produced in jaw elevator muscles by stimulation of the cervical sympathetic nerve (5 g in rabbits, 1 g in cats and rats) to contraction of intrafusal muscle fibres, this conclusion was not substantiated by measurements of the amount of tension in isolated spindles of cat ( $\gamma$ -stimulation), which was 5 mg per spindle (Boyd, 1976a) and from 2.3 to 8 mg per spindle (Fukami, 1985). Also Barker and Saito (1981) found that not all spindles in cat hindlimb muscles were adrenergically innervated. Boyd (1985), in his review, assumed that if there were 200 spindles on one side of the jaw elevator muscles of rabbit and all contracted maximally they would produce a tension of only 1 g, which is only one fifth of the tension recorded by Passatore *et al.* (1985).

In the present study no intrafusal muscle fibre was found to be associated with adrenergic innervation. Only about one third of spindle capsules in the deep masseter muscle were found to be adrenergically innervated at their equatorial region.

Ultrastructural study has revealed that there are tight junctions

between the capsular sheet (outer and inner) cells (Kennedy, Quick and Reese, 1979; Ovalle and Dow, 1985) which act as a barrier to the diffusion of substances into the periaxial space. Systematic perfusion with horseradish peroxidase penetrates the outer layers, but fails to enter the periaxial space (Kennedy and Yoon, 1979; Ovalle and Dow, 1985). Hence catecholamines released from the preterminal and terminal varicosities of the adrenergic axon in between capsule lamellae are unlikely to reach the intrafusal muscle fibres.

The estimated proportion of adrenergic innervation associated with extrafusal muscle fibres was found to be 40% (28223 among 71400 fibres) in the deep masseter muscle and 55% (2952 among 5382 fibres) in the anterior digastric muscle. The work of Passatore *et al.* (1985) prompted Lund and Matthews (1987) to re-examine the response of rabbit jaw muscle to sympathetic stimulation. They recorded tension of 3.12 - 8.21 mN produced in right anterior digastric muscle. Since digastric muscles contain no spindles, they concluded that the recorded tension was not attributable to the contraction of intrafusal muscle fibres. Moreover, Grassi and Passatore (1989) have now studied the effect of sympathetic nerve stimulation at physiological frequencies, and found that it caused contraction in fatigued and non-fatigued digastric muscle of rabbit. The anatomical finding of sympathetic innervation among the extrafusal muscle fibres in this study, and the physiological finding of the effect of sympathetic innervation recorded by Lund and Matthews (1987); Grassi and Passatore (1989), together with Boyd's conclusion (1985) lead me to suggest that most of the tension recorded in the above reports is attributable to extrafusal muscle fibres and is generated by a non-twitch mechanism, perhaps a sympathetic action on the glycolytic pathway. However, further investigations using 5-hydroxydopamine to label the varicosities of monoaminergic

nerves with the aid of electron microscopy are necessary to discover whether or not there is an autonomic innervation associated with intrafusal muscle fibres similar to that observed in cat, and for its characterization according to vesicular content.

CHAPTER V

Fibre-type composition of rat masseter muscle

A. Introduction

1. Classification and nomenclature of muscle fibres

Mammalian skeletal muscle fibres are classified into various types, on morphological, physiological and histochemical grounds; therefore different systems of nomenclature have been used by the investigators. In the past, muscle fibres were classified according to their appearance as red and white; the red muscle is a slowly contracting muscle, the white muscle a rapidly contracting one. Denny-Brown (1929) stated that red muscle fibres can be stained intensely with Sudan III stain, whereas white muscle fibres can be coloured only faintly.

Padykula (1952) demonstrated histochemically by using succinate dehydrogenase (SDH) activity that rat skeletal muscle fibres consist of two types, and that the small fibres apparently contained more enzyme than the large ones. Nachmias and Padykula (1958) discovered that the extraocular muscle of the rat and the diaphragm of cat showed three types of fibre when in other muscles only two types were seen. Ogata (1958a) was the first to demonstrate that at least three types of muscle fibre are present in most of the muscles of vertebrates. His observation focused on the relationship between their enzymatic activity, sudanophilia and size; for example, gastrocnemius muscle of cat is composed of three types of fibre: small or red muscle fibres, that possessed the strongest enzymatic activity and sudanophilia; large or white muscle fibres, that exhibited the weakest SDH activity and the

weakest sudanophilia; and intermediate sized ones with intermediate strength between the above two in their histochemical reactions, called **medium** fibres. He found cat diaphragm muscle is composed of three types of fibre but there is no close correlation between the size and enzyme activity or sudanophilia of the fibres. Later studies by Ogata and Mori (1964), Edgerton and Simpson (1969), and Gauthier and Lowey (1979) confirmed the above results. Dubowitz and Pearse (1960a & c) reported a histochemical study of oxidative enzymes and phosphorylase in human, rat, pigeon, toad and goldfish muscle. They found in mammalian and avian muscle two distinct fibre types and classified them as **type I** and **type II** according to their enzyme histochemical profiles. The small-diameter fibres were associated with strong oxidative enzyme activity and weak glycolytic (phosphorylase) and ATPase activity, while the other type, usually larger, showed a converse pattern of enzymatic activity. Their conclusion was that small muscle fibres with a strong oxidative and weak phosphorylitic profile correspond to the red muscle fibres (type I) and the large size fibres with opposite enzyme reaction profiles correspond to the white muscle fibres (type II).

Stein and Padykula (1962) examined the region of medial head (near the origin) of the rat gastrocnemius muscle known as the white fast. Different histochemical techniques were employed for muscle fibre components of mitochondria, glycogen and actomyosin ATPase activity. According to the mitochondrial enzyme activity they identified three types of fibre, A, B and C. Type A, the large, fast white had few mitochondria, appeared lighter than the other fibre when reacted with SDH, lacked subsarcolemmal (SDH) activity but was rich in glycogen; types B and C were both red fibres with more mitochondria, stained darker than type A; and type C was clearly distinguished by its heavy rim of subsarcolemmal (SDH) activity, its low-moderate glycogen, and

its positive reaction with adenosine triphosphate (ATPase).

Samaha, Guth and Albers (1970); Guth, Samaha and Albers (1970) and Yellin and Guth (1970) designated muscle fibres as  $\alpha$ ,  $\beta$  and  $\alpha\beta$  on the basis of the actomyosin ATPase reaction and according to qualitative differences in the pH lability of the enzyme. Using ATPase reactions and the pH lability on the gastrocnemius and soleus muscles of humans, rabbits and rats, Brooke and Kaiser (1970) suggested a new nomenclature for four fibre types, three major called I, IIB and IIA, and the fourth, minor, IIC. Later studies confirmed type IIC as transitional between I and IIA, for it shares the characteristics of both. Peter, Barnard, Edgerton, Gillespie and Stempel (1972) suggested new nomenclature for the muscle fibres as follows: Fast-twitch-glycolytic (FG), Fast-twitch-Oxidative-glycolytic (FOG) and slow-twitch-oxidative (SO). These names were given on the basis of biochemical, histochemical and physiological characteristics.

Recently, modern histochemical and immunohistochemical methods have been employed to identify the various extrafusal muscle fibres of skeletal muscles. Using these methods Gauthier and Lowey (1979), were able to demonstrate that the rat diaphragm contained four basic types of fibre. These they named **white**, **intermediate**, **fast red** and **slow red**, according to ultrastructural and cytochemical characteristics.

By the immunohistochemical staining of antibodies selected for particular isoforms of myosin, Bosley and Rowlerson (1980) were able to report that a new myosin was found in the cat jaw-closer muscles; subsequently they introduced the term IIM since that fibre type contains this myosin. Later studies confirm that the cat posterior temporalis and the middle ear of both cat and dog, have type IIM fibres (Rowlerson, *et al.*, 1981; Mascarello *et al.*, 1982). Moreover, Rowlerson *et al.* (1983) have found the jaw-closer muscles of most



carnivores and primates contain the rare IIM fibre type. They suggest that the fact that the IIM fibre type occurs in masticatory muscles of most of carnivores and primates is related to their bite characteristics. Table 8 summarizes the main nomenclature systems for mammalian extrafusal muscle fibres. In this study I have followed that of Brooke and Kaiser (1970). Table 9 summarizes the main histochemical and immunohistochemical characteristics of mammalian extrafusal muscle fibres.

## 2. Histochemistry of masseter muscle

As mentioned previously there are two groups of masticatory muscles; closing, opening and several others supporting muscles. The masseter muscles of different mammals have been studied using histochemical and immunohistochemical techniques.

The fibre type composition has been described for the masticatory muscles in humans (Ringqvist, 1971, 1973, 1974; Kirkeby, Moe and Vilmann, 1988; Eriksson and Thornell, 1983), in cats (Taylor, Cody and Bosley, 1973; Rowlerson *et al.*, 1981; Bosley and Rowlerson, 1980; Mascarello and Rowlerson, 1986), in monkeys (Maxwell, Carlson, McNamara and Faulkner, 1979), in guinea pigs (Schiaffino, 1974; Suzuki, 1977), in rabbits (Schiaffino, 1974; Mabucki, Pinter, Mabuchi, Sreter and Gergely, 1984; Mascarello, Scapolo, Veggetti and Rowlerson, 1986), in cattle, sheep, swine, dogs (Suzuki, 1977), and in rats (Hiemae, 1971; Schiaffino, 1974; Suzuki, 1977; Hiraiwa, 1978; Maier, 1979; Rokx *et al.*, 1984).

Three types of fibre have been found in the masseter muscle of humans (Ringqvist, 1973) and of cats (Taylor *et al.*, 1973), the majority of the fibres in human masseter being close to type I, and the

**Table 8**

Classification systems of extrafusal muscle fibre types

According to

Ogata ('58a)	white	medium	red
Dubowitz & Pearse ('60c); Engel ('62)	II	II	I
Stein & Padykula ('62)	A	C	B
Romanul ('64)	I	II	III
Jinnai ('60); Nishiyama ('65); Gauthier & Padykula ('66); Edgerton & Simpson ('69)	white	red	intermediate
Samaha, Guth & Albers ('70) (in rat)	$\alpha\beta$	$\alpha$	$\beta$
Yellin & Guth ('70) (in rat) (in cat)	$\alpha\beta$ $\alpha$	$\alpha$ $\alpha\beta$	$\beta$ $\beta$
Brooke & Kaiser ('70)	IIB	IIA	I
Peter <i>et al.</i> ('72)	FG	FOG	SO
Gauthier & Lowey ('79)	white	inter- mediate	red (fast)
			red (slow)

Table 9

Main histochemical and immunohistochemical profiles of extrafusal muscle fibres.

Reaction with	IIB	IIA	I	IIM
Succinate dehydrogenase	low	high	high	mod.-very high
Phosphorylase	high	high	low	
Glycogen (PAS)	high	variable	variable	
ATPase after alkali	high	high	low	high
ATPase after acid	low	low	high	very high
Antibodies (anti-I)	no	no	strong	no
Antibodies (anti-IIA)	weak	strong	no	no
Antibodies (anti-IIM)	no	no	no	strong

majority in cat masseter being close to type A. But according to Mascarello and Rowleron (1986) and Rowleron *et al.* (1988), the cat masseter consists of a majority of type IIM fibres and a small number of type I fibres concentrated in a deep layer of the muscle in the part which contains most spindles. Bovine masseter is composed of type I only (Schiaffino, 1974, Suzuki, 1977) whereas canine and swine masseters are composed of two types; fast and slow (Suzuki, 1977). In the rat masseter, Hiemae (1971), using Sudan black B stain, found two types of fibre; pale (phasic) and dark (tonic). Schiaffino (1974) found no typical white fibres in rat masseter; it seemed to be uniformly composed of type II, alkali-stable and acid-labile. Suzuki (1977) found that all rat masseter fibres showed a strong reaction for alkali-stable ATPase. Occasionally a few fibres (2-5) occurred in the deepest portion of the muscle and showed a strong reaction for acid-stable ATPase. Hiraiwa (1978) using succinate dehydrogenase and ATPase reactions, found rat masseter composed of red and white fibres. Finally Rokx *et al.* (1984) claimed that deep masseter contained four types of fibre; fast white (FW), fast intermediate (FI), fast red (FR) and slow red (SR), and that the superficial part contained three types; FW, FI and FR.

Those studies have shown that the species differences may be more apparent than real since authors differ about the rat.

Yellin (1969a) and Gonyea and Ericson (1977) demonstrated that the muscle spindles in many limb muscles tended to be concentrated in those parts of the muscle that are rich in slow and other oxidative fibres. Similarly, Maier (1979) and Rokx *et al.* (1984) found that most spindles in deep masseter muscles were located in regions containing the oxidative fibres. Moreover they observed that complex spindles were associated with slow muscle fibres.

### 3. Histochemistry of intrafusal muscle fibres

The histochemical staining reaction techniques used in the classification of vertebrate muscle fibres have also been employed to identify types of intrafusal fibre.

An important difference between intrafusal and extrafusal fibres that was not recognized at first is that intrafusal fibres show regional variation in histochemical profiles (Yellin, 1969a, succinate dehydrogenase and phosphorylase; Banks, Barker, Harker and Stacey, 1975, ATPase, phosphorylase and glycogen). Banks *et al.* (1975) observed variations along the length of all types of intrafusal muscle fibre in cats, rabbits and rats. Yellin (1974) suggested that the regional histochemical differences may relate to variations in the contractile apparatus along the fibres. Kucera (1977 & 1981) and Kucera, Dorovini-Zis and Engel (1978) using ATPase staining in rats and cats described regional variation in the bag fibres only. A more recent study by Khan and Soukup (1988) has shown that heterogeneity occurs among some chain fibres of rat soleus and vastus lateralis muscles when stained with some histochemical stains.

Ogata and Mori (1962 & 1964) were the first to demonstrate three types of intrafusal fibre in rat and other vertebrates by studying their oxidative enzyme activity. The small intrafusal fibre which contained more oxidative enzyme and showed a higher activity they called the red intrafusal muscle fibre; the medium intrafusal fibre, which showed moderate activity, they called the medium intrafusal fibre; and the large intrafusal fibre, with low activity they called the white intrafusal fibre. Yellin (1969a), using succinate dehydrogenase and phosphorylase activities to stain rat muscle spindles, described four types of intrafusal fibre, three of them corresponding to type A, B and C extrafusal fibres described by Stein

and Padykula (1962); the fourth type, usually large (a nuclear-bag fibre), was distinguished by its low succinate dehydrogenase and low phosphorylase activities.

Against this background of mammalian extrafusal and intrafusal muscle-fibre histochemistry, it was found that at least two types of actomyosin adenosine triphosphate (ATPase) are present in mammalian skeletal muscles and are distributed according to the contraction speed of the muscles (Barany, 1967). One type is found in fast-twitch muscle fibres, the other in slow-twitch muscle fibres (Guth and Samaha, 1969; Samaha, Guth and Albers, 1970; Guth, Samaha and Albers, 1970; Yellin and Guth, 1970). Each muscle fibre was thought to contain one type of enzyme only (Drews and Engel, 1966; Guth and Samaha, 1969).

Yellin (1969b), using the histochemical method for actomyosin ATPase of Guth and Samaha (1969), reported that some intrafusal and extrafusal muscle fibres in the extraocular muscle of rat showed dual enzyme activity, possessing the two forms of the enzyme, and showed high levels of both alkali-stable and acid-stable actomyosin ATPase.

Yellin's (1969a & b) conclusion was that three types of intrafusal fibre could be distinguished; nuclear-chain fibres, the small fibres possessing high succinate dehydrogenase, phosphorylase and myofibrillar ATPase activity after alkali pre-incubation; and two types of nuclear-bag fibre, a large size with low SDH, phosphorylase and high ATPase after acid pre-incubation, and a medium size with moderate SDH, low ATPase after acid or alkali pre-incubation. Those two kinds of bag fibre were designated as nuclear bag and intermediate by Barker and Stacey (1970), and as bag<sub>2</sub> and bag<sub>1</sub> by Ovalle and Smith (1972), who found the two types in cat and monkey spindles.

Barker and Stacey (1970) studied the intrafusal muscle fibres of rabbit tenuissimus muscle using histochemical, ultrastructural and

histological stains. They were able to demonstrate three types of intrafusal muscle fibre and named them nuclear bag fibre, the longer and thicker bag fibre which has low activity with phosphorylase and medium activity with ATPase after alkali pre-incubation; the **intermediate fibre**, shorter than the bag fibre and showing low activity with both phosphorylase and ATPase after alkali; and **nuclear-chain fibres**, with high activity of both phosphorylase and ATPase after alkali. Banks (1971) using phosphorylase stain followed by treatment with iodine, distinguished three types of intrafusal fibre in rabbit. James (1971c) suggested a new nomenclature for the three types of rat intrafusal fibre that were usually found in each spindle. According to their enzyme profiles, he termed them Types 1, 2 and 3 fibres, corresponding to the old terminology of chain, bag and intermediate fibres respectively.

Further histochemical and morphological studies on rat spindles by Milburn (1973a) led her to describe three types of intrafusal fibre and to propose the term 'typical bag', since the thickest and longest fibre has a high ATPase activity and lacks an M-line in ultrastructural observation. Similar observations have been noted for guinea-pig spindle fibres by Banks and James (1971); again the thickest bag fibre did not possess M-lines. Yellin (1969a & b); James (1971c); Milburn (1973a & b); Soukup (1976); Khan and Soukup (1979) have all shown that there are three types of intrafusal fibre present in rat spindles.

Banks *et al.* (1975) devised a technique which enabled them to correlate histochemical and ultrastructural studies for the same spindle. Banks *et al.* (1975), and Banks, Harker and Stacey (1977) found two types of nuclear-bag fibre in cat, rabbit and rat hindlimb muscle spindles. Variations in the histochemical profile along the length of all intrafusal types were observed. Ultrastructural

observations revealed regional variation in the M-line condition along bag fibres.

Table 10 shows the main histochemical, immunohistochemical and some morphological features characteristic of intrafusal muscle fibres.



**Table 10**

Characteristics of intrafusal muscle fibres in the equatorial (A) and polar (B) regions of mammalian muscle spindles.

Feature	bag <sub>2</sub>	bag <sub>1</sub>	chain
<b><u>region A</u></b>			
Relative diameter	very large	large	small <sup>1</sup>
Equatorial nucleation	bag	bag	chain
<b><u>region B</u></b>			
ATPase after alkali	moderate <sup>2</sup>	low	high
ATPase after acid	very high	high	low <sup>3</sup>
Phosphorylase activity	medium	low	high
Succinate dehydrogenase activity	low	medium-high	high
Mitochondrial size	small	medium	large
Mitochondrial density	low	low	high
M-line	present	absent	present
<b><u>Reaction with antibodies</u></b>			
Anti-I	strong	strong	no
Anti-IIA	moderate	weak	strong

**Notes:**

- <sup>1</sup> - In polar region the diameter of long chain may reach that of bag fibres.
- <sup>2</sup> - Bag fibres only show regional variation with some histochemical stains.
- <sup>3</sup> - Some chains of some slow and fast muscles of rat hindlimb showed strong reaction with acid-stable ATPase (Khan and Soukup, 1988).

## B. Results

### 1. Extrafusal fibres of masseter muscle

#### 1.1. Superficial masseter

All the fibres were type IIA possessing alkali-stable and acid-labile ATPase activity. There were some fibres that appeared to be intermediate between the IIA and IIB fibres, but no true type IIB fibres were found.

The use of succinate dehydrogenase (SDH) reaction showed that no fibre had SDH activity as low as in the classical IIB fibres of extensor digitorum longus (EDL) (figure 35A). On the other hand, there was some variation in SDH activity, which seemed to be higher in the deep masseter muscle (plate 6); this corresponds with the findings made by Schiaffino (1974).

#### 1.2. Deep masseter

All the fibres in this part of the muscle were found to be of type IIA, as in the superficial part, with the exception of a very few slow types. This was clear from the ATPase reaction after acid preincubation, when the fibres of deep masseter muscle were compared with light colour type IIA fibres indicated by the arrows in EDL (figure 33). Using the succinate dehydrogenase reaction no fibres had succinate dehydrogenase activity as low as in classical IIB fibres (Stein and Padykula, 1962; Reichmann and Pette, 1982), such as were seen in EDL (figure 35B).

All the muscle fibres reacted strongly with anti-IIA antiserum, except for those true type I fibres, around the spindle clusters (figure 39). This result corresponds very well with the alkali-ATPase reaction (figure 36).

In the anteromedial region of the muscle, around the spindle cluster, a small number of type I fibres and type IIC fibres were found (plates 7 & 8). Maier (1979) and Rokx *et al.* (1984) described these fibres as SO and SR respectively. Some fibres of the slow type were also found around one or both of the minor clusters in the zygomatico-mandibular. The anterior of these was always surrounded by such fibres, the posterior, when present, only occasionally. Suzuki (1977) has found 3-5 fibres showing a strong reaction to acid-stable ATPase in this region.

The histochemical identification of these slow-type fibres was confirmed immunohistochemically, since all of them reacted strongly with anti-I antiserum (figure 40). Plate 7 illustrates the differences between subtype IIC and true type I fibres. Type IIC (open triangles) reacted strongly with anti-IIA antiserum whereas true type I (stars) reacted strongly with the anti-I antiserum (figure 37). These possessed alkali-labile ATPase activity (figure 36) and very acid-stable ATPase activity (figure 38). IIC fibres, by contrast, reacted strongly or moderately with anti-I antiserum (figure 37), but also have moderate to strong alkali-stable activity (figure 36), and partially acid-stable ATPase activity (figure 38).

There were other fibres in the restricted area around the spindle cluster (filled circles in plate 7) which contained some slow myosin, staining positively with anti-I antiserum. However, their ATPase stability in acid or alkali preincubation was opposite to that of type I fibres and to type IIC fibres in acid only. These slow fibres are similar to type IIA fibres and appear to be type IIC<sup>o</sup> (Billeter, Weber, Lutz, Howald, Eppenberger and Jenny, 1980).

In order to ensure that IIC fibres were not transitional between fast and slow types, a sample of deep masseter of an eight-month male

rat was processed for ATPase reactions; the results obtained (plate 9) were the same as those for the six week old rat, suggesting that in the masseter IIC fibres are a distinct type.

The total number of slow-myosin containing fibres did not exceed 200, i.e. less than 0.3% of the total extrafusal population in the deep masseter and zygomatico-mandibular muscle (see p. 30). In three animals counts of the numbers of type I and IIC fibres surrounding the anterior spindle cluster were 119(45:I, 74:IIC), 84(40:I, 44:IIC), and 72(24:I, 48:IIC).

Finally, there was no positive reaction of extrafusal fibres with anti-fast antiserum specific for IIM type myosin (Bosley and Rowleron, 1980; Rowleron *et al.*, 1981).

## 2. Intrafusal fibres

As described previously the greatest number of spindles were found in deep masseter; many spindles were grouped together in two major clusters, one located anteriorly, consisting of about 40 spindles (plates 7, 8, 9 and figures 46-51), and the other posteriorly, consisting of about 20. The rest were scattered throughout the deep portion, either singly or in pairs or in threes. The zygomatico-mandibular contained either one or two minor clusters of about 6 spindles each.

The examination of intrafusal fibres was carried out in region B of the spindles. Three types of intrafusal fibre were clearly distinguished histochemically in this study. Some staining characteristics were found to vary along the fibres. Their histochemical and immunohistochemical properties are summarized in Table 11 and illustrated in figures 36-44. They were similar to those of intrafusal fibres of limb muscles, as described by Yellin (1969a & b); James

(1971c); Milburn (1973a & b); Soukup (1976); Khan and Soukup (1979);  
Kucera (1977) and Kucera *et al.* (1978).

**Table 11**

Some characteristics of intrafusal muscle fibres of rat deep masseter in region B.

Feature	bag <sub>2</sub>	bag <sub>1</sub>	chain
diameter	large	medium	small
ATPase after alkali	moderate	low	high
ATPase after acid	very high	high*	low
succinate dehydrogenase activity	low	medium-high	high
number per spindle	1-2	1	2-6
<b><u>reaction with antiserum</u></b>			
anti-I	strong	strong	no
anti-IIA	moderate	weak	strong

\* bag<sub>1</sub> fibre showed regional difference in ATPase reaction after acid preincubation.

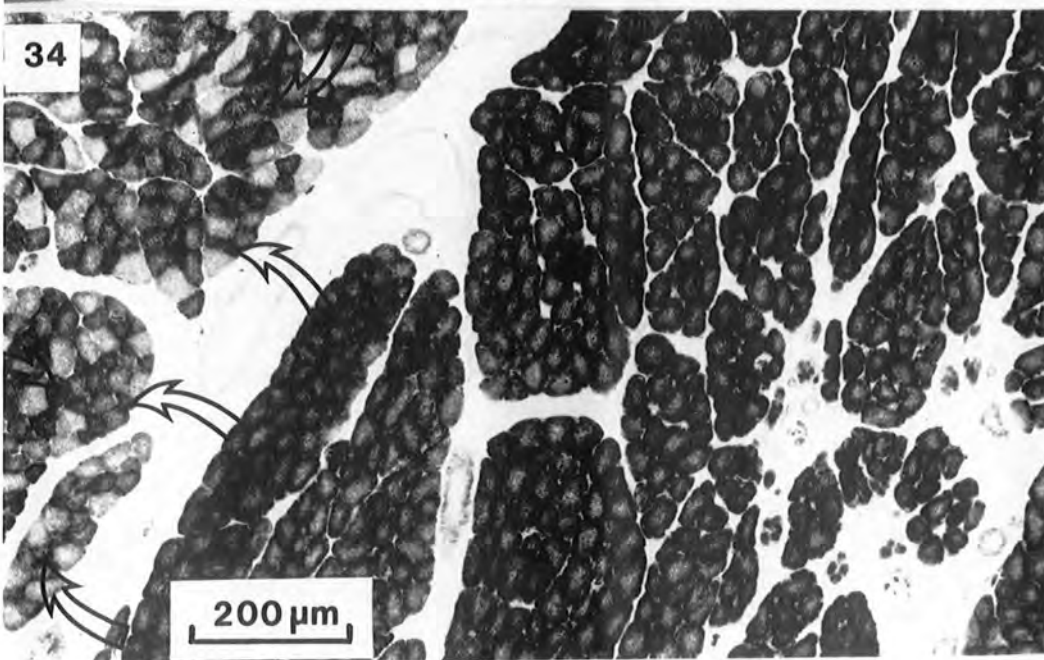
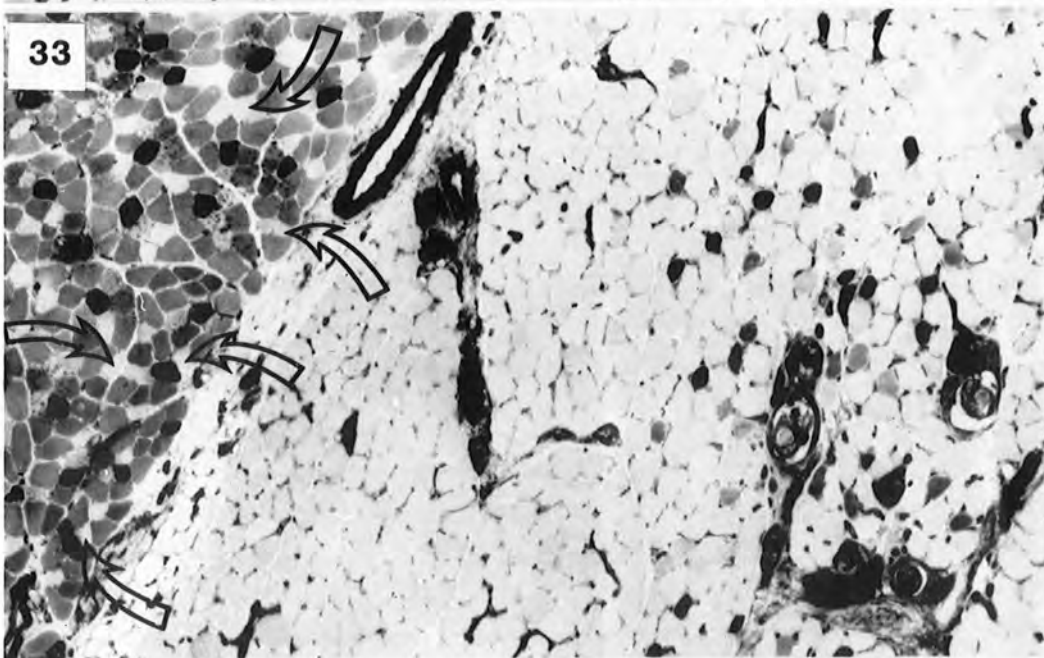
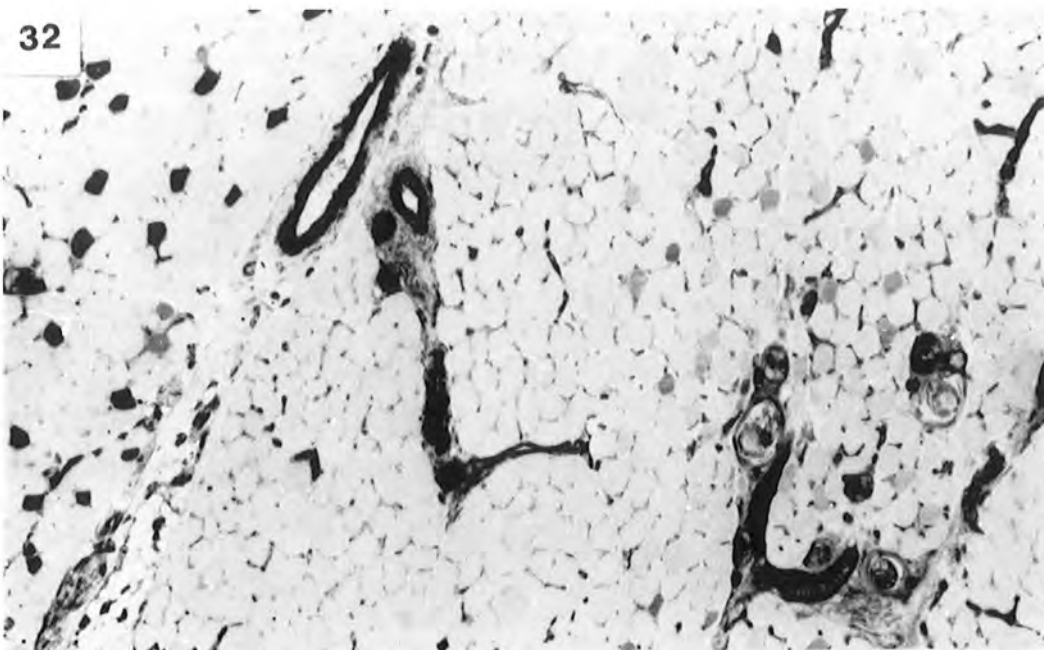
## Plate 5

Figures 32-34. Semiserial transverse frozen sections 15  $\mu$ m thick from a block composed of rat extensor digitorum longus (EDL) muscle (left) and part of deep masseter muscle containing the anterior spindle-cluster (right). Sections 32 and 33 were incubated for myosin ATPase after acid pre-incubation at pH 4.35.

Figure 32. The section was pre-incubated in acid buffer of 0.2 M Na-acetate. Only two types of fibre were differentiated in EDL, type I fibres (dark) and type II fibres (pale).

Figure 33. The section was pre-incubated in acid buffer of 0.1 M Na-acetate. The normal three fibre types of EDL can be seen very clearly. Type I fibres strongly stained, type IIA fibres (indicated by arrows) weakly stained and type IIB fibres moderately stained. The masseter muscle appears to be composed exclusively of type IIA fibres (compared with type IIA fibres in EDL) except in the area of the spindle-cluster where some type I fibres are present (strongly stained in figure 33, moderately in figure 32) and several type IIC fibres (moderately stained in figure 33) and type IIC' fibres (weakly stained in figure 33) can be recognized. See also plate 7.

Figure 34. The section was stained with succinate dehydrogenase. The enzymatic activity of the three types of fibre can be noted in EDL, high in small type I fibres, low in large type IIB fibres and intermediate in medium type IIA fibres (arrows). The cytological patterns characteristic of the three types can be seen at high magnification in plate 6.

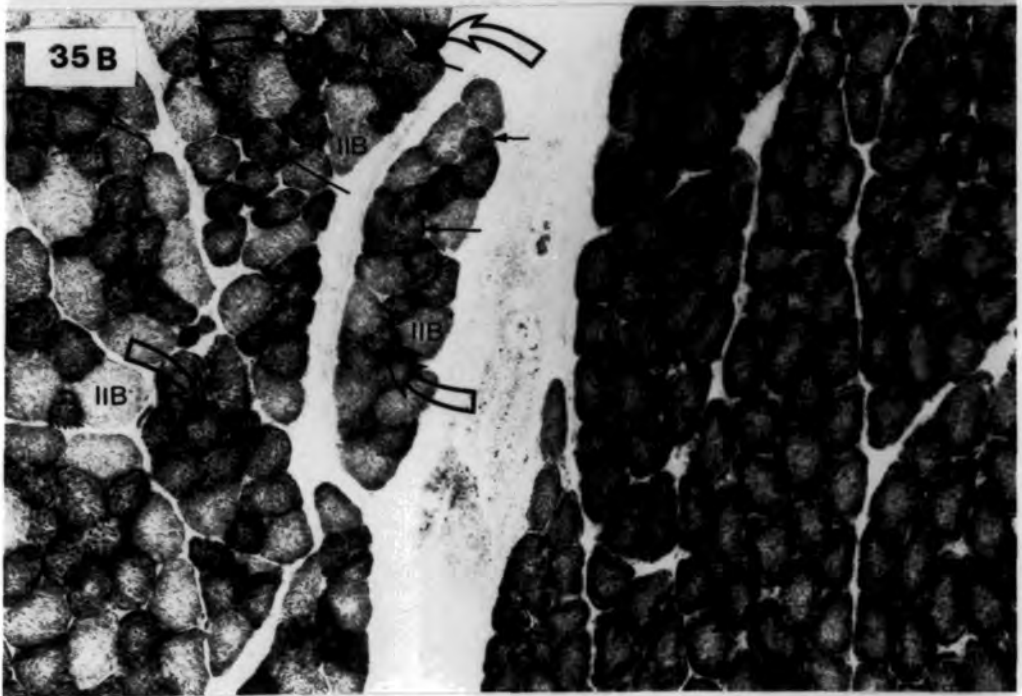
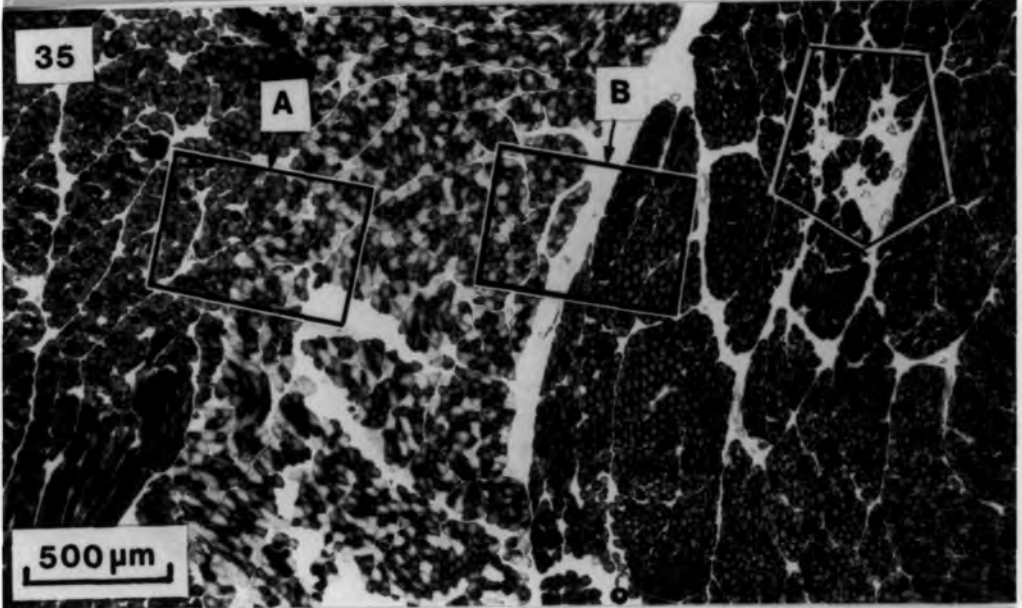
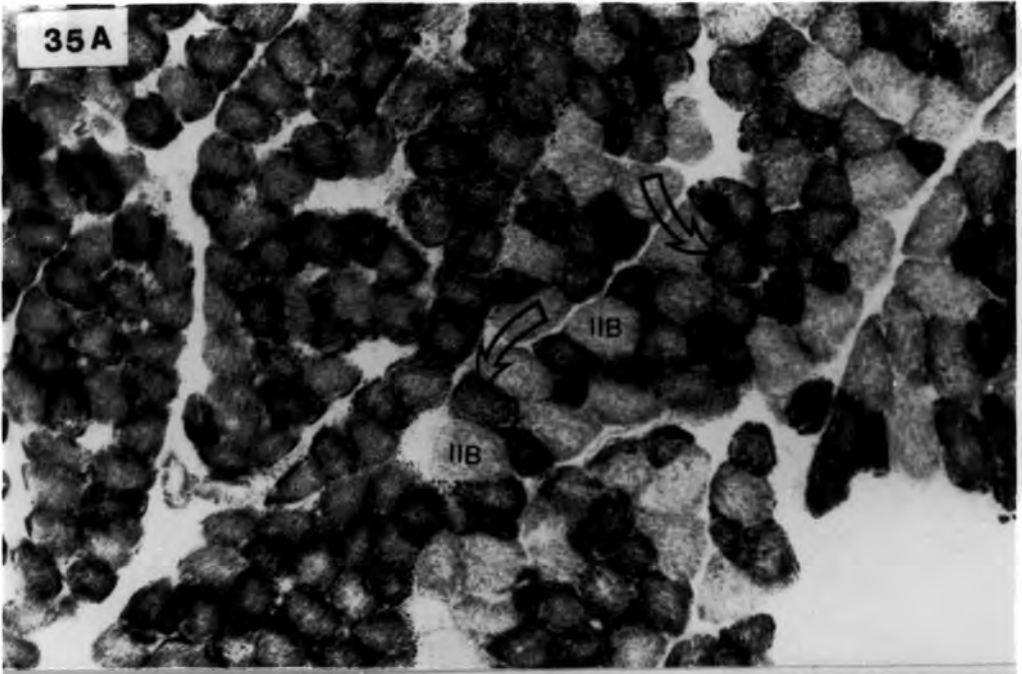




## Plate 6

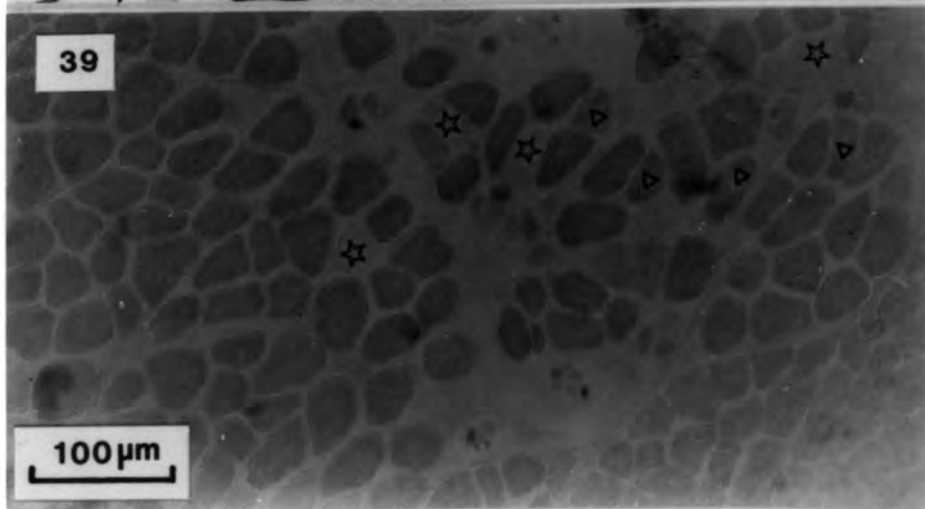
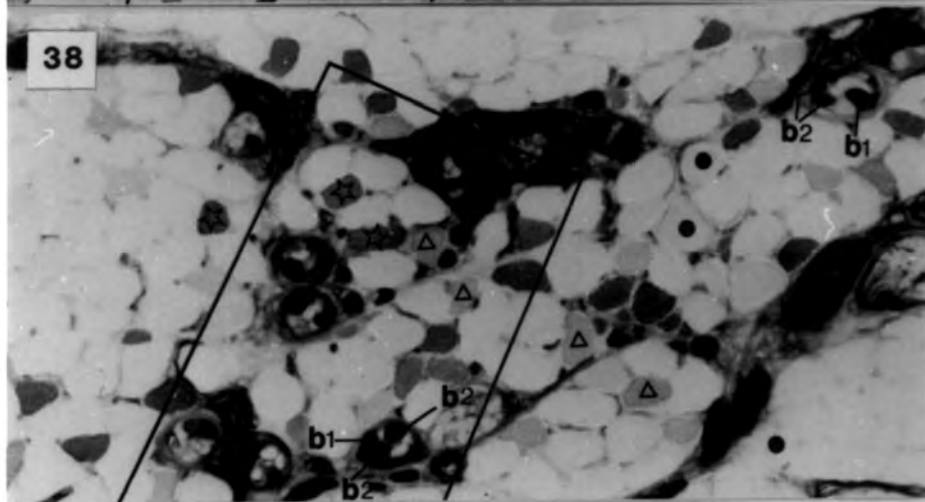

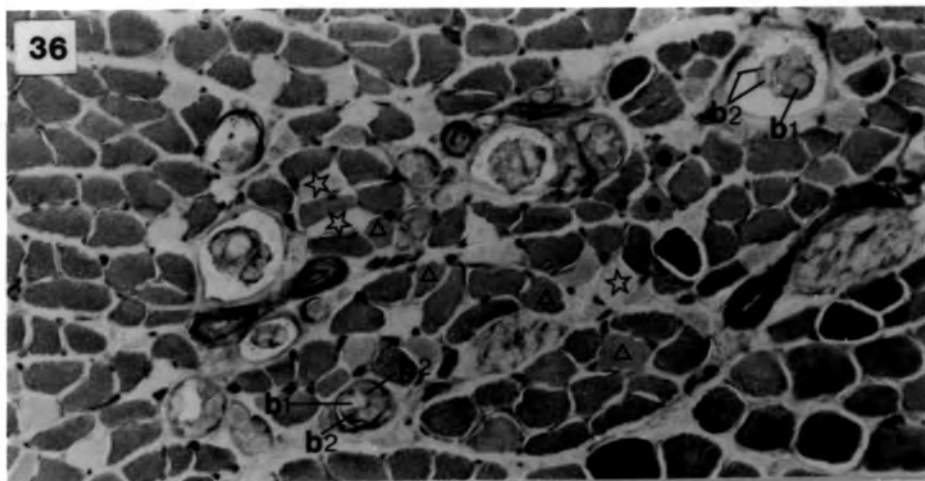
Figure 35. Transverse frozen section composed of rat superficial masseter (SM) (left), extensor digitorum longus (EDL) (middle) and deep masseter (DM) (right) muscles, to show succinate dehydrogenase activity. The figure illustrates the heterogeneous fibre composition of EDL and the homogeneity of superficial and deep masseter. Notice, however, that deep masseter is more intensely stained than superficial masseter. The circumscribed area on the right contains the anterior spindle-cluster.

Figure 35A (SM + EDL) and 35B (DM + EDL) show at higher magnification the boxed areas labelled A and B in 35. Three types of fibre can be seen in EDL but only one type in SM and DM. Type I are small fibres with very high dehydrogenase activity (small arrows in 35B), type IIB are large fibres with low activity, and type IIA are intermediate fibres with high activity and clear subsarcoplasmic succinate dehydrogenase activity (open arrows in 35A and B). Masseter fibres are similar to type IIA of EDL.



### Plate 7

Figures 36-39. Photographs of semiserial frozen sections of rat deep masseter containing the anterior spindle-cluster. (36) mATPase activity after alkali pre-incubation, (37) anti-I immunoperoxidase, (38) mATPase activity after acid pre-incubation, and (39) anti-IIA immunoperoxidase. Some extrafuscal fibres (stars) around and among the spindles which react most strongly with anti-I (37), are true type I fibres showing alkali-labile (36) and acid-stable (38) mATPase activity. IIC fibres (open triangles) react strongly or moderately with anti-I but also have moderate to strong mATPase activity, and partially acid-stable mATPase activity. IIC' fibres (filled circle) give a weak reaction with anti-I but have an alkali-stable, acid-labile mATPase activity like surrounding IIA fibres. Insets in 37 and 38 are shown at high magnification in plate 8.



## Plate 8

**Figure 40.** Frozen, 20  $\mu\text{m}$  thick sections of rat deep masseter in the area containing the anterior spindle-cluster showing anti-I immunoperoxidase activity. Many fibres react with this antibody. Large (extrafusal) fibres show three main levels of positive reaction: (i) very strong - in type I and some IIC fibres, (ii) moderate - in type IIC fibres and (iii) weak - in type IIC $\prime$  fibres. The very small strongly stained fibres are spindle bag fibres. Inset is shown at higher magnification in figure 42.

**Figure 41.** High magnification of inset in figure (38) showing some spindles cut through region B (sleeve region). Note each spindle possesses usually one large diameter bag<sub>2</sub> fibre, stained very dark (acid pre-incubation), one medium diameter bag<sub>1</sub> fibre, stained moderate-dark and two-three small diameter chain fibres unstained. Some spindles possessed two bag<sub>2</sub> fibres. In spindles cut through the polar (C) region, both bag fibres stained dark.

**Figure 42.** High magnification of inset in figures 37 and 40. Note the high reaction of bag fibres with anti-I antibody in contrast to the low reaction of chain fibres.

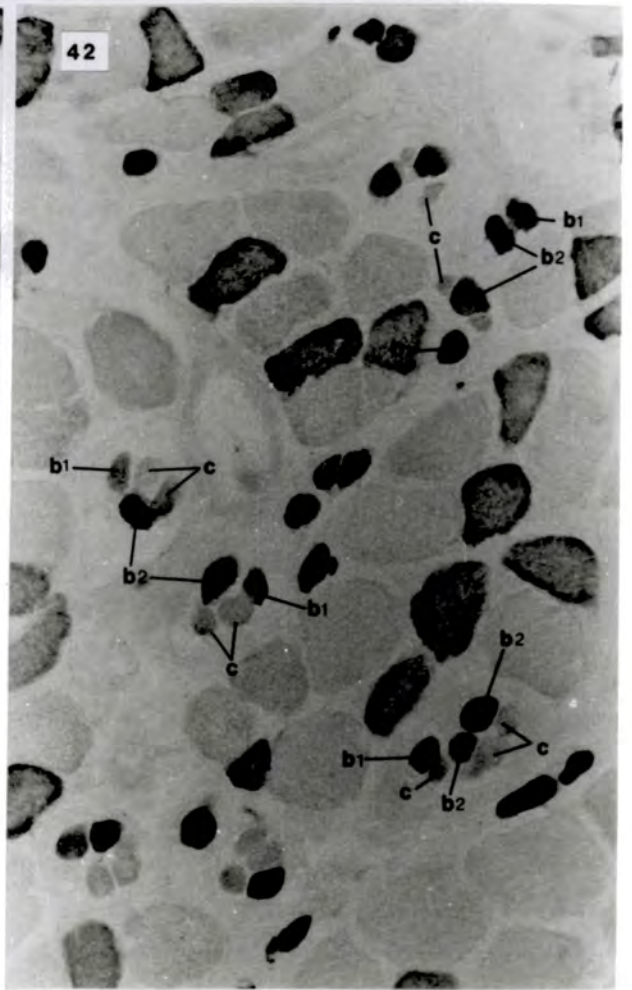
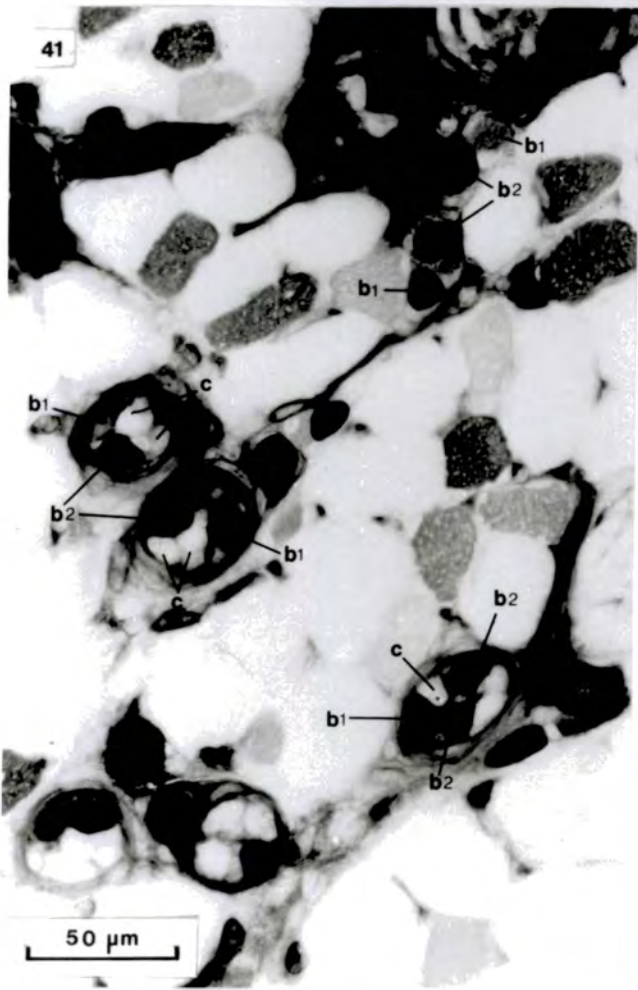
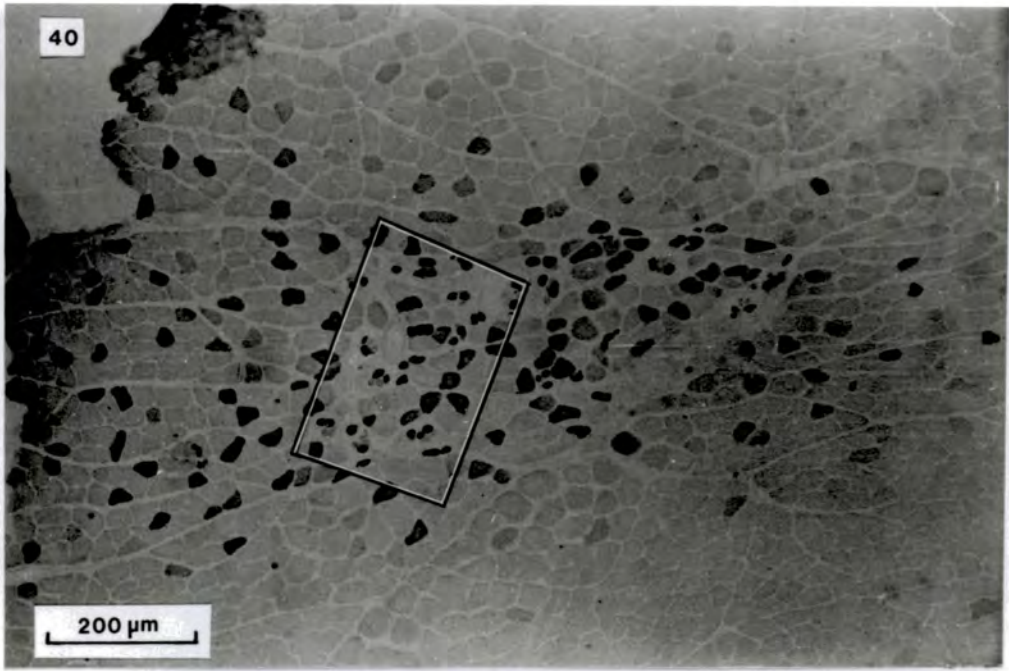


PLATE 8


## Plate 9

Figures 43 and 44. Semiserial 20  $\mu\text{m}$  transverse frozen sections of 8 month old rat deep masseter muscle stained with ATPase reaction to show extrafusal muscle fibres containing slow myosin types true I and IIC in the anterior cluster area.

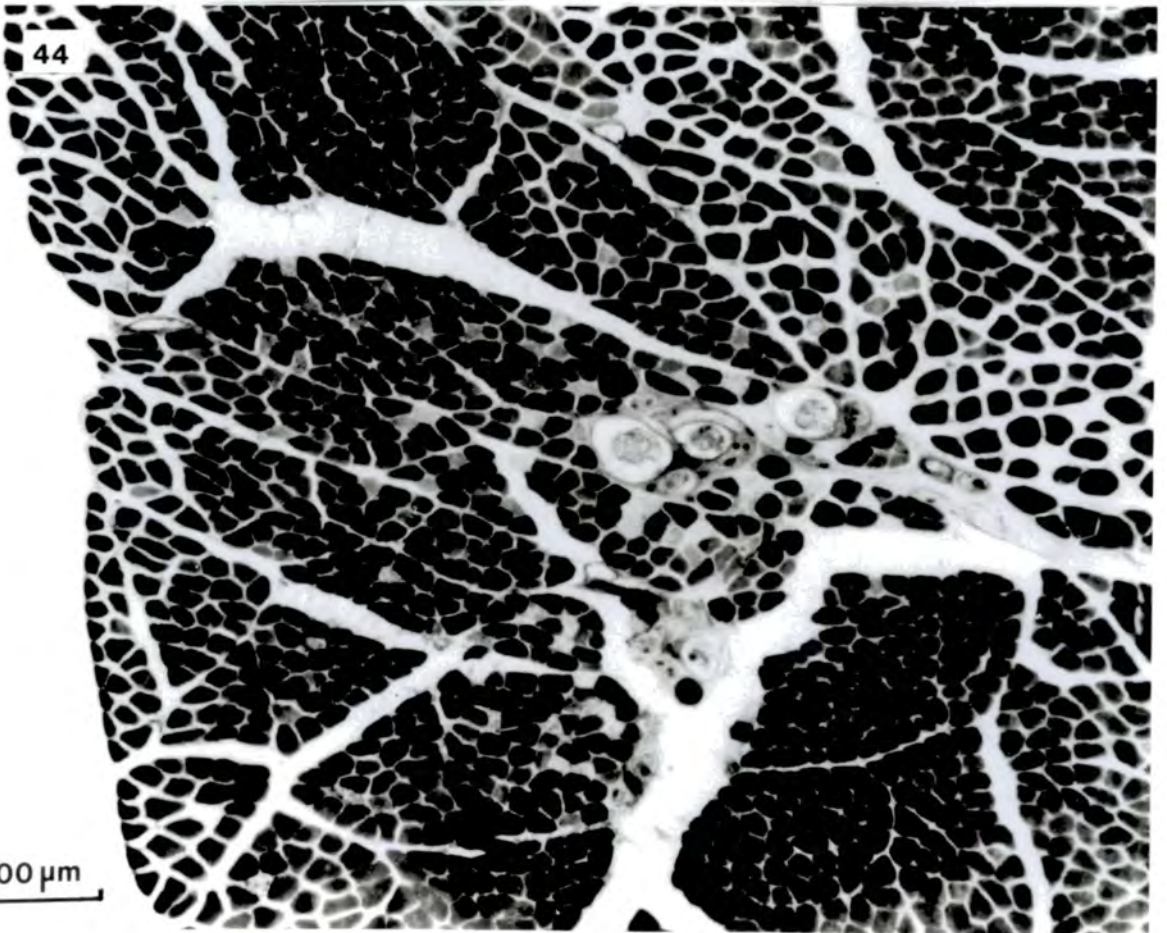
Figure 43. Acid pre-incubation in ATPase reaction, the true type I fibres very strongly stained while IIC types strongly or moderately stained.

Figure 44. Alkali pre-incubation in ATPase reaction, the true type I fibres weakly stained while IIC type moderately to strongly stained.

43



44



200  $\mu$ m



## C. Discussion

### 1. Extrafusal muscle fibres

As mentioned in the Introduction, there are a large number of classification systems for describing muscle fibre types, that were based on the methods used for this study. Two systems have been widely used to study mammalian muscle fibres because they have been correlated with muscle and motor unit physiological properties. These are the Brooke and Kaiser (1970) (types I, IIA, IIB, IIC) system, a histochemically based system that distinguishes between the various forms of fast and slow myosin found in limb and jaw muscles; and the Peter *et al.* (1972) (SO, FOG, FG) system, a histochemically and biochemically based system incorporating the oxidative and glycolytic properties of the muscle fibres.

In the present study I considered it essential to re-examine the fibre-type composition of rat masseter muscle using modern histochemical and immunohistochemical techniques. The fibre-types can be identified histochemically by their myosin ATPase and succinate dehydrogenase activities, and immunohistochemically by using antibodies specific for Type I, IIA and IIM. This modern method is useful for distinguishing between the different sub-types of fast and slow fibre (Billeter *et al.*, 1980).

As an internal standard, a muscle of known fibre-type composition from the same animal was incubated with masseter muscle in composite block for cryosectioning. The extensor digitorum longus (EDL) was chosen for this purpose since it contains the three types, I, IIA and IIB (Pullen, 1977b).

Using myosin ATPase staining (method A in Snow *et al.*, 1982) to stain the frozen sections from a composite block of masseter and EDL

muscles I have found that a reduced molarity of Na-acetate from 0.2 M to 0.1 M as acid pre-incubation buffer was necessary to exhibit the three fibre types of EDL muscle (figures 32 & 33). The majority of masseter fibres were type IIA in composition, i.e. very acid-labile and alkali-stable. This is in agreement with Schiaffino (1974) and Suzuki (1977) but in disagreement with Hiraiwa (1978) and Rokx *et al.* (1984) since no white fibres (IIB) were found. Type I fibres were concentrated in the deep part of the muscle and exclusively in the areas which contained the spindle-cluster. This is in complete agreement with the finding of both Maier (1979) and Rokx *et al.* (1984). Maier (1979) and Rokx *et al.* (1984) did not detect the IIC fibres containing slow myosin when using only histochemical mATPase reactions.

The absence of type IIB fibres from rat masseter muscle is supported by the succinate dehydrogenase reaction. Type IIB fibres contain few mitochondria, and stain weakly with succinate dehydrogenase. Comparing the fibres of the masseter with the classical IIB fibres of the EDL muscle in figure 35, all the fibres of masseter muscle had high oxidative activity, and the staining intensity in the deep masseter muscle fibres was found to be higher. This is similar to the observation described by Schiaffino (1974) for rat deep masseter muscle.

When the immunohistochemical technique was employed, using type-specific antisera I, IIA and IIM, all the muscle fibres in masseter muscle were revealed to be type IIA, except for a few which were type I, IIC and IIC<sup>o</sup> restricted to spindle-cluster areas. The total number of such fibres was less than 0.3% of the total fibres of deep masseter muscle as counted in this study (Chapter III). This was found to be the case for young rats (six weeks old) and older rats (up to eight months old). Similarly, the same feature was found in

masseter muscles of rabbit and monkey (Rowlerson *et al.*, 1988), for which reason it is suggested that the IIC fibre is a constant type in masseter muscle of these animals rather than transitional between types IIA and I as has been suggested to occur in limb muscles (Kugelberg, 1976; Jansson, Sjodin and Tesch, 1978; Billeter *et al.*, 1980; Howald, 1982).

The observation in this study that most of the spindles occur in deep layers of the masseter muscle in the region containing the slow fibre type mainly in the anteriomedial part of the muscle is in agreement with those of Maier (1979) and Rokx *et al.* (1984). In the jaw-closing muscles of other species the association between spindles and slow fibres is also stronger than that between spindles and oxidative fibres. Similarly, Yellin (1969a) observed in some rat hindlimb muscles that the muscle spindles were present in areas containing oxidative fibres, mostly composed of type B and type C fibres [i.e. slow (I) and fast red (IIA) respectively]. Gonyea and Ericson (1977) found the muscle spindles always in the region which contains slow twitch fibres in cat flexor carpi radialis muscle. These authors and also Botterman, Binder and Stuart (1978), believed that such a structure reflects a functional compartmentation within these muscles.

The presence of a very few oxidative fibres in rat masseter raises the question of their functional significance. Their clear association with muscle spindles led Professor Barker to speculate that they might represent the extrafusal component of  $\beta$ -innervated motor units. The validity of such an assumption has been demonstrated in some cat hindlimb muscle spindles by Barker *et al.* (1977). This speculation was confirmed in part of the present study (Chapter VI) when some examples were found by using teased silver preparations. Further investigation

on rat masseter muscle similar to that carried out by Barker *et al.* (1977) (glycogen-depletion experiments) needs to be done to see whether the IIC fibres are also  $\beta$ -innervated.

## 2. Intrafusal muscle fibres

The mammalian intrafusal muscle fibre types can be demonstrated histochemically by using different reactions. For example, mATPase after acid and alkali pre-incubation reaction is routinely used to classify muscle fibres.

Ogata and Mori (1962 & 1964); Yellin (1969a & b); James (1971c); Milburn (1973a); Soukup (1976); Banks *et al.* (1977); Khan and Soukup (1979); Kucera (1977); Kucera *et al.* (1978) and Khan and Soukup (1988) all described three intrafusal fibre types in each spindle of rat limb muscles. These types are now designated as bag<sub>2</sub>, bag<sub>1</sub> and chain fibres, based on their morphological and histochemical staining characteristics. Bag<sub>2</sub> is the largest fibre exhibiting both high alkali and high acid pre-incubated mATPase activity; bag<sub>1</sub> is medium sized with low activity for alkali and low or high activity for acid pre-incubated mATPase activity; the smallest fibres are chains, and have high alkali-stable, acid labile mATPase activity (James, 1971c; Ovalle and Smith, 1972; Banks *et al.*, 1975 & 1977; Kucera, 1977; Kucera *et al.*, 1978).

James (1971c) has described three types of intrafusal muscle fibre in rat using different histochemical stains. The three fibre types are similar to those of rat deep masseter muscle described in the present study. The large intrafusal muscle fibre in the spindles of rat deep masseter found here possessed high mATPase activity and corresponds to that intrafusal muscle fibre in rat hindlimb muscle designated as "typical bag" fibre by Milburn (1973a). Using mATPase and succinate

dehydrogenase activities in the present study, the three intrafusal muscle fibres of the spindle in rat deep masseter showed the same profiles described by Soukup (1976) as the intrafusal muscle fibres in rat extensor digitorum longus and soleus muscles as follows: typical bag (bag<sub>2</sub>) fibre exhibited a high alkali and acid-stable mATPase; intermediate bag (bag<sub>1</sub>) fibre showed low mATPase activity after alkali pre-incubation, and after acid pre-incubation showed regional differences in reaction; chain fibres of extensor digitorum longus muscle showed a high alkali-stable activity after alkali pre-incubation and low activity after acid pre-incubation. Similar results have been demonstrated by Khan and Soukup (1979) using other rat muscles.

The intrafusal muscle fibres of the rat deep masseter muscle in the present study corresponded well with the following descriptions of regional staining variation in bag fibres: Banks *et al.* (1975), who reported that the histochemical profile of the three types of intrafusal muscle fibre showed regional variations along their length; Yellin (1974), who found that bag<sub>1</sub> fibres showed regional differences in staining after acid pre-incubation; and Kucera (1977), who noted that both bag fibres displayed regional differences in staining properties with acid-stable mATPase.

According to acid and alkali pre-incubation mATPase staining characteristic in the sleeve (B) region, some spindles in rat deep masseter muscle in the present study contained two bag<sub>2</sub> fibres (figures 36-38, plate 7 and figures 41 & 42, plate 8). Kucera *et al.* (1978) reported a similar result using rat soleus muscle spindles.

Using an immunohistochemical technique Rowlerson, Gorza and Schiaffino (1985) found that antibodies specific for slow-twitch fibre myosin reacted strongly with the bag fibres of cat spindles, though bag<sub>2</sub> usually stained darker than extrafusal type I fibres. Employment

of this technique in the present study confirmed the mATPase activity findings (figure 37, plate 7 and figure 42, plate 8) that some spindles contained two bag<sub>2</sub> fibres.

CHAPTER VI

Structure and somatic innervation of muscle spindles  
in rat deep masseter muscle

A. Introduction

The muscle spindle is a complex mechanoreceptor which lies in parallel with the ordinary extrafusal muscle fibres of skeletal muscles of vertebrate animals. Weismann, in 1861, first noticed and described the muscle spindle in a frog (Barker and Banks, 1986). The most detailed physiological and histological descriptions of muscle spindles have been carried out on the cat, particularly of hindlimb muscles. Each spindle consists of small (intrafusal) muscle fibres, their ends attached to connective tissue, tendon or extrafusal endomysium. For most of their length, they are enclosed by a fusiform cellular multi-lamellated capsule containing a fluid. This encloses the sensory innervation and extends as a sleeve on each side to enclose part of each pole. In the equatorial region of the muscle spindle the bundle of intrafusal fibres is separated from the capsule by a prominent periaxial space. The equatorial length of the periaxial space and the length of capsule vary according to the number of sensory endings present. Two types of innervation are supplied to the intrafusal bundle: a) primary and secondary sensory endings occur in the equatorial region and respond to active and passive changes in muscle length; b) motor endings occur in the polar regions, where the intrafusal fibres are contractile.

The term tandem muscle spindle was introduced by Cooper and Daniel (1956) to describe those spindles that possess two or more periaxial

spaces each with its own intrafusal bundle but linked end to end by usually a single bag<sub>2</sub> fibre.

Recent histological studies have shown that some spindles receive autonomic innervation distributed to their capsule wall in the equatorial region and in neuroeffective association with intrafusal fibres inside the periaxial space (for more information see Barker, 1974; Barker and Saito, 1981; Barker and Banks, 1986).

### 1. Intrafusal muscle fibres

As mentioned in Chapter Five, rat muscle spindles usually contain three types of intrafusal muscle fibre: bag<sub>1</sub>, bag<sub>2</sub> and chains, which resemble the intrafusal muscle fibres of other mammals. Their morphological and innervation features have been described by many authors.

Chain fibres usually end within the limits of the capsule, whereas bag fibres extend beyond its poles. The diameter of bag fibres is typically greater than that of chain fibres (Porayko and Smith, 1968; Ovalle, 1971; Milburn, 1973a & b; Soukup, 1976; Walro and Kucera, 1985a), however, it was found that bag<sub>2</sub> fibres are thickest in regions A and B and usually longer than bag<sub>1</sub> fibres. However, the diameters of bag<sub>1</sub> and chain fibres are not significantly different in region B (Soukup, 1976; Banks *et al.*, 1977). Diameter measurement of intrafusal muscle fibres for some rat hindlimb muscles is shown in Table 12. The lengths of spindles in the anterior digastric muscle of the rat varies between 0.63 mm and 1.17 mm (Lennartsson, 1980b); in the lateral pterygoid muscle between 0.2 mm and 2.2 mm (Rakhawy, Shehata and Badawy, 1971) whereas in jaw muscles examined by Karlsen (1965) the length of spindle capsules varied from 0.7 to 1.5 mm. In lumbrical muscles the



Table 12

Diameter measurement of intrafusal muscle fibres for some rat limb muscles.

According to	diameter ( $\mu\text{m}$ )			region	muscle
	bag <sub>2</sub>	bag <sub>1</sub>	chain		
Porayko and Smith '68	10.0 $\pm$ 1.6		7.7 $\pm$ 1.0	pole	lumbrical
Ovalle '71	10.28		6.85	pole	IV lumbrical
Soukup '76	11-16	9-14	6-9	juxtaeq- uatorial	EDL, EHL & Soleus
Banks <i>et al.</i> , '77	14.4 $\pm$ 0.69 18.7 $\pm$ 2.30	11.3 $\pm$ 0.59 12.3 $\pm$ 0.56	9.4 $\pm$ 0.38 9.1 $\pm$ 0.61	pole equator	PL, PDQ & Soleus

EDL: extensor digitorum longus

EHL: extensor hallucis longus

PL: peroneus longus

PDQ: peroneus digiti quinti

mean length of capsules was less than 1.0 mm; bag fibres were  $1.5 \text{ mm} \pm 0.5$  in length; and the length of chain fibres was  $1.2 \text{ mm} \pm 0.6$  (Porayko and Smith, 1968). Walro and Kucera (1985a) obtained the following results for rat soleus spindle poles which were reconstructed from serial  $1 \mu\text{m}$  thick transverse sections: mean length of 6 pole spindles from the centre of the equator to the end of the longest intrafusal muscle fibre was  $2769 \pm 362 \mu\text{m}$ . All bag fibres were found to extend beyond the capsule ends and bag<sub>1</sub> fibres were usually shorter than bag<sub>2</sub> fibres. Mean length of 7 bag<sub>1</sub> fibres was  $2482 \pm 571 \mu\text{m}$  and that of 6 bag<sub>2</sub> fibres was  $2667 \pm 351 \mu\text{m}$  (measurements calculated from the centre of the equator). 60% of chain fibres terminated within the limits of the capsule, the mean polar length of 25 chain fibres was  $1270 \pm 240 \mu\text{m}$ .

Elastic fibres of rat muscle spindles have been studied by Landon (1966a) in his E.M. study; by Cooper and Daniel (1967); and by Cooper and Gladden (1974). They were found to be similar in appearance and disposition to those in cat and human muscle spindles. Elastic fibres around intrafusal muscle fibres are more numerous than extrafusal muscle fibres, and there are many more elastic fibres around bag fibres than around chain fibres. In the extracapsular polar regions there is an abundance of elastic fibres associated with bag<sub>2</sub> by contrast to bag<sub>1</sub> (Gladden, 1976; Walro and Kucera, 1985a & b). Recently Arbuthnott, Gladden and Sutherland (1989) reported that elastic fibres in the extracapsular region of rat soleus muscle spindles were distributed equally to each bag fibre. The number of elastic fibres around the chain fibres becomes greatly reduced as they enter the periaxial space, but they increase in number around the region of the nuclear chains. At the beginning of the outer capsule the elastic fibres divide, some branches passing into the layers of the outer capsule and others

continuing along the intrafusal muscle fibres. In the equatorial region the elastic fibres which surround the bag fibres divide, some branches continuing to run with the bag fibres, while some pass outwards into the inner capsule (Cooper and Gladden, 1974). Banks (1984) described the attachment of elastic fibres to bag-fibre surfaces of cat tenuissimus muscle spindles over a length of about 300  $\mu\text{m}$  on either side of the primary region. The muscle fibres bore peg-like projections directed towards the equator indicating the direction of maintained tension. Banks suggested that this arrangement of elastic fibres would increase the stiffness of the equatorial region.

The main ultrastructural features of intrafusal muscle fibres are: transverse sections of the polar regions of bag fibres are characterized by ill-defined myofibrils which are tightly packed together with little interfibrillar sarcoplasm, and contain few sarcoplasmic organelles (glycogen, mitochondria and sarcoplasmic reticulum elements) whereas in the polar region of chain fibres the myofibrils are discrete units with abundant interfibrillar sarcoplasm containing various sarcoplasmic organelles (Merrillees, 1960; Landon, 1966a; Ovalle, 1971). Longitudinal sections show the sarcomere length of bag fibres to be similar to that of extrafusal muscle fibres but longer than that of chain fibres (Landon, 1966a). Moreover, the sarcomeres of bag<sub>1</sub> fibres were found to be longer than those of bag<sub>2</sub>, chain and extrafusal muscle fibres (Banks *et al.*, 1977). In chain fibres the mitochondria are larger, longer and more numerous than in bag fibres and are usually oriented parallel to the longitudinal axis (Landon, 1966a; Ovalle, 1971; Milburn, 1973a & b).

According to Merrillees (1960) the nuclei are elongated, centrally placed and widely spaced along the polar region of all fibre types, but according to Landon (1966a) these nuclei are peripherally placed, they

are elongated in bag fibres and lenticular in longitudinal outline at the ends of chain fibres.

In the myotube regions adjacent to the nuclear bag of bag fibres a row of closely-placed, elongated nuclei lies within a core of sarcoplasm surrounded by a peripheral shell of myofibrils. The number of nuclei, and the volume of the sarcoplasm surrounding the nuclei, increase in the equatorial region (nuclear bag), whereas the myofilaments decrease. Chain fibres contain a single row of elongated, well-separated nuclei (the nuclear chain) which lie centrally along the equatorial region of the muscle fibre. The myofibrils are as in bag fibres. The sarcoplasm that fills the internuclear spaces of both bag and chain fibres contains many organelles; small mitochondria, Golgi complexes, clusters of ribosomes, and sometimes rough endoplasmic reticulum (Merrillees, 1960; Landon, 1966a; Ovalle, 1972a). The nuclear bag of bag<sub>2</sub> fibres contains more nuclei (3-4 abreast on average) than that of bag<sub>1</sub> fibres (2-3 abreast on average) (Soukup, 1976).

Ovalle (1971) described a prominent **M-line**, present in each sarcomere in the polar region of chain fibres of rat lumbrical muscles, similar to the M-line in sarcomeres of extrafusal muscle fibre. In contrast, the M-line of bag fibres was said to be ill-defined, and in the form of two faint parallel lines. Ovalle (1972a) found the same structure of the two forms of M-line in the equatorial regions of both intrafusal fibre types. Landon (1966a) mentioned the presence of an **M-band** in the sarcomere of chain and bag fibres in their polar regions. The M-band was prominent in chain fibre, and ill-defined in bag fibre. However, it was subsequently found that a prominent M-line is present throughout the length of the chain fibre but only in the polar regions of the bag<sub>2</sub> fibre. The bag<sub>1</sub> fibre possesses an M-line consisting of

two faint parallel lines, throughout the length of the fibre (Banks *et al.*, 1975; Barker, Banks, Harker, Milburn and Stacey, 1976; Banks *et al.*, 1977). Kucera *et al.* (1978) found the same result in the bag<sub>2</sub> fibre, but that the bag<sub>1</sub> fibre possesses a distinct M-line in the extreme extracapsular region only, and lacks one in other regions.

## 2. Capsule, periaxial space and axial sheath

Ultrastructural study of spindle capsules in rat lumbrical muscles has been done by Merrillees (1960) and Landon (1966a). The intrafusal bundle for most of its length is surrounded by a fusiform capsule, which at the equatorial region consists of about 6-9 layers of very thin, flat cells. The number of layers gradually decreases towards the polar regions and ends in a single layer, usually with the end of chain fibres, closely investing the bag fibres which pass beyond it. These layers are arranged in a concentric tubular fashion, alternating with layers filled with collagenous fibrils. They possess a basement membrane on both surfaces, and contain small mitochondria, numerous pinocytotic vesicles and sometimes ribosomes. Their edges overlap forming regions of intimate contact known as **desmosomes** (Merrilles, 1960); and **terminal-bar tight junctions** (Landon, 1966a).

The spindle capsule is a modified extension of epineurium and endoneurium connective cellular layers that enclose the spindle nerve (Shantha, Golarz and Bourne, 1968; Low, 1976). Barker and Banks have agreed with this interpretation (1986).

In the equatorial region some fibrocytes from the innermost capsular layer cross the periaxial space obliquely to join other cells of the same type forming the axial sheath and endomysial cells to enclose the intrafusal muscle fibres. These cells have no basement

membrane, have terminal-bar tight junctions at their adjoining edges, and form more or less complete envelopes around each intrafusal muscle fibre at the equator, but towards the ends of the periaxial space the covering becomes less complete to enclose two or more intrafusal muscle fibres in each compartment. Myelinated and non-myelinated axons, collagen fibrils, loose strands of basal lamina and elastic fibres are found between these thin cellular layers.

One or two capillaries are found between or outside the layers of the outer sheath. A group of myelinated axons of different diameters usually penetrate the capsule, passing through the periaxial space to innervate the intrafusal muscle fibres. Unmyelinated axons were also found to pass through together with myelinated axons within capsular lamellar layers (Merrillees, 1960; Landon, 1966a).

### 3. The sensory innervation

#### 3.1. The primary endings and axons

Most studies have been carried out on cat and rabbit muscles using gold chloride and silver techniques (Barker, 1974, Banks, Barker and Stacey, 1982; Barker and Banks, 1986; Banks, 1986).

Each muscle spindle is supplied by a thick sensory fibre (afferent), known as a **group Ia axon**, which enters the spindle near the equator of the capsule. Within the periaxial space the axon divides into several branches to form the terminal branches (sensory endings) on the densely nucleated equatorial regions of the three types of intrafusal muscle fibres (the nuclear bags, myotubes, and nuclear chains). These terminals are known as the **primary endings**.

The terminals appear to consist of spirals, half rings and a few complete rings. According to Boyd (1962c), large spirals are

distributed to the bag fibres and small spirals to the chain fibres. They are arranged closely together around the middle of each nuclear bag, but more widely spaced to either side, where they may be disposed as irregular forms or run diagonally (Barker, 1948). Spirals are more common and more extensive around chain fibres than around bag fibres. The number of spiral turns per unit length is greater in the middle of the bag<sub>1</sub> than the bag<sub>2</sub> primary terminals and the bag<sub>1</sub> possesses more extensive irregular portions than does the bag<sub>2</sub>. Moreover, a close association between nucleation and innervation was found (Banks *et al.*, 1982). Banks (1986), using a reconstruction technique, described the form and distribution of primary terminals of cat tenuissimus muscle spindle. He found that all ring features on the intrafusal muscle fibres were open, all the terminals remain separate and do not fuse, most of them are located on the bag<sub>1</sub> and the position of each terminal determines its form.

Sometimes two axons enter the same spindle to terminate around bag fibres (Barker, 1974). Banks (1973) found that some rabbit spindles contained two separately innervated primary endings, the endings lying side-by-side or end-to-end. Banks *et al.* (1982) found some cat spindles innervated by two Ia axons, referring to the endings as **double primaries**.

Ultrastructural studies carried out on rat lumbrical muscles by Merrillees (1960) and Landon (1966b) showed that the axon terminals lie in shallow grooves on the surface of the muscle fibres, they are devoid of Schwann cells, and are enclosed by the basal lamina of the intrafusal fibres. The terminals on bag fibres usually bulge outwards from the muscle fibre's surface whereas those on the chain fibres are usually low and flattened (Barker, 1974; Banks, 1986). Sometimes a terminal wraps two or three adjacent muscle fibres to form a **sensory**

**cross-terminal** (Adal, 1969). Sensory cross-terminals usually occur between chain fibres, but may also occur between a chain and a bag fibre (Barker, 1974; Banks *et al.*, 1982; Kucera, Walro and Reichler, 1988a), and between a bag<sub>1</sub> and a bag<sub>2</sub> fibre (Diwan and Milburn, 1986; Walro and Kucera, 1987).

### 3.2. The secondary endings and axons

The secondary-ending terminals are supplied by afferents thinner than group Ia axons, and these are known as **group II axons**. They usually enter the spindle together with the primary afferent.

Secondary endings are located on one or both sides of the primary ending. In cat and rabbit mostly only one secondary ending is present adjacent to the primary, but there may be up to five on one side, and up to six on both sides. The afferent may occasionally branch to supply two endings in one spindle located on each side of the primary or located in different spindles (Barker, 1974). According to the position of the secondary endings on either side relative to the primary ending region, a notation of S<sub>1</sub>, S<sub>2</sub>, S<sub>3</sub> and so on has been widely used after its introduction by Boyd (1962c).

The most common form of ending is annulospiral, the terminals mainly distributed to chain fibres. A small spray form (flower-spray) of ending is usually found when bag fibres are involved in such innervation and bag<sub>1</sub> usually receives fewer secondary endings than bag<sub>2</sub>. The ultrastructural features of secondary endings are similar to those of primary endings. Cross-terminals occur similarly (Barker, 1974; Banks *et al.*, 1982; Barker and Banks, 1986; Kucera *et al.*, 1988a).

To date, there is insufficient information about the sensory innervation of rat muscle spindles, both axons and endings, as compared



with cat and rabbit sensory innervation. This is due to the difficulty of staining the nerve endings with silver and teasing muscles when using an impregnation method.

In this study I have been able to get good quality silver impregnated muscles from the jaw and hindlimb which has allowed a full analysis of the spindle innervation.

According to Porayko and Smith (1968) and Gladden (1969) all rat muscle spindles of lumbrical and intertransverse caudal muscles contained one primary ending only, or one primary ending plus up to three secondary endings. The form of the primary ending on both bag and chain fibres was tightly wound spirals. The form of the secondary endings was fine sprays of nerve terminals supplied to chain fibres (Porayko and Smith) or else took the form of rings and spirals on those secondaries next to the primary endings. Some secondary branches appeared to end in the region occupied by the primary (Gladden, 1969).

#### 4. The motor innervation

The mammalian muscle spindle is supplied with motor innervation at its poles. Two kinds of motor system are involved in spindle motor innervation: a fusimotor ( $\gamma$ ) system, which is exclusively intrafusal, and a skeletofusimotor ( $\beta$ ) system, in which intrafusal and extrafusal muscle fibres share a common innervation, as in non-mammalian spindles. The motor innervation consists of a diffuse multiterminal trail ending and two types of plate known as  $p_1$  and  $p_2$ . These endings are distinguished by shape, length, location and there are differences in the complexity of their subneural apparatus (Barker, Stacey and Adal, 1970; Barker, 1974; Banks, Barker and Stacey, 1985; Walro and Kucera, 1985a & b, Kucera and Walro, 1987a & b; Kucera *et al.*, 1988a).

#### 4.1. Types of fusimotor ending

i) The  $\beta$  innervation,  $p_1$  plates: The  $p_1$  plate is the terminal of an axon derived from a collateral branch of a  $\beta$  axon. It occurs in the form of a taper and occasionally knob or ring, and often occurs in the polar regions either just before or just after the muscle fibres pass out of the capsule. In cat spindles  $p_1$  plates were usually found to innervate bag fibres (Barker *et al.*, 1970). The  $p_1$  plate is longer but similar to an extrafusal end plate and has a nucleated sole-plate and a Doyère eminence.

Using the glycogen-depletion method, in cat spindles, it became clear that  $\beta$  axons innervated the bag<sub>1</sub> fibre or the long chain fibre (Barker *et al.*, 1977; Jami *et al.*, 1978 and 1979). From serial 1  $\mu$ m-thick transverse sections of a sample of 15 spindles of rat lumbrical muscle, Walro and Kucera (1985b) reported that 7  $\beta$  axons each terminated on one intrafusal fibre only, 5 on the bag<sub>1</sub> and 2 on chain fibres.

ii) The  $\gamma$  innervation,  $p_2$  plates: The  $p_2$  plates of cat are much longer and more elaborate than  $p_1$  and extrafusal plates. They are knob-like axon terminals, lacking a nucleated sole-plate and Doyère eminence. Their location in cat spindles is the same as that of  $p_1$  plates. Barker *et al.* (1970) reported that in cat spindles 90% of  $p_2$  plates were located on bag fibres, and 10% on chain fibres. In rabbit spindles, the  $p_2$  plate was described as claw like. They were distributed to bag fibres only (Barker and Stacey, 1970).

iii) The  $\gamma$  innervation, trail ending: The trail ending is so called because the terminal branches travel for relatively long distances

within the spindle before terminating. Its location is mainly intracapsular and juxta-equatorial. Non-myelinated trail fibres were sometimes found to participate in the trail innervation of cat muscle spindles. Trail endings may overlap with secondary endings, and both trail and sensory axon terminals may occasionally occur side by side on the same muscle fibre. The trail endings were found distributed to both bag and chain fibres (for more information see Barker, 1974; Banks *et al.*, 1985).

Rat motor innervation has been described often in conflicting ways by Karlsen (1965); Porayko and Smith (1968); Gladden (1969); Hennig (1969); Mayr (1969); Ovalle (1972b), Andrew, Part and Wait (1971); Kucera, Dorovini-Zis and Engel (1978); Walro and Kucera (1985a & b); Kucera and Walro (1987a & b); Kucera, Walro and Reichler (1988a); and Arbuthnott, Gladden and Sutherland (1989). According to Porayko and Smith (1968), rat lumbrical spindles are supplied with two motor axons, one innervating the bag fibres, the other innervating the chain fibres. Ovalle (1972b) found two fusimotor nerve fibres entering together with Ia afferent nerves, each one supplying a pole of the spindle. An additional one or two fusimotor fibres may supply each pole. Two types of motor ending were described by Porayko and Smith (1968): one resembled the plate ending of cat muscle spindles; the other was a fine single filament. Gladden (1969) identified three types of fusimotor endings in rat tail muscles. These motor endings appear to correspond to the  $p_1$ ,  $p_2$  and trail endings in cat. Ovalle (1972b) claims to have demonstrated that the smaller plates ( $p_1$ ) are located on bag fibres, whereas the larger plates ( $p_2$ ) terminate on chain fibres and the trail endings in the juxta-equatorial region terminated on both fibre types in the spindles of rat lumbrical muscles. Andrew *et al.* (1971) found that some muscle spindles of segmental tail muscles of the rat were

without  $\gamma$ -efferents. Moreover, Andrew and Part (1974) demonstrated physiologically the presence of static and dynamic  $\beta$  fibres in rat segmental tail muscles.

Kucera *et al.* (1978) described the location of motor endings along the three types of intrafusal muscle fibres of rat soleus muscle. Two types of ending were localized in the encapsulated region, and were designated as 'diffuse' and 'plate' endings, some with and others without underlying muscle fibre nuclei. Bag fibres possessed multiple motor endings. However, bag<sub>1</sub> fibres were characterized by a richness of motor endings, and possessing 'plates' on its extracapsular region. Each pole of a chain fibre was supplied with a 'plate' ending, but occasionally one of the two poles was devoid of a motor ending. No 'diffuse' endings were seen on chain fibres.

Reconstructions of 15 spindle poles of rat lumbrical muscles of hindlimb made by Walro and Kucera (1985b) showed that motor axons supplied all but one pole of a bag<sub>1</sub> fibre, whereas only 67% of chain and 33% of bag<sub>2</sub> fibre poles received motor innervation. Chain fibres received fewest motor endings, moreover both types of bag fibre were innervated by multiple motor endings, whereas only one motor ending was found in each pole of the chain fibres. Arbuthnott *et al.* (1989) reconstructed 13 spindle poles of rat soleus muscles. Forty efferents innervated 15 bag<sub>1</sub>, 15 bag<sub>2</sub> and 31 chain fibre poles; 67.5% of them were selective efferents, the rest were nonselective. Three bag<sub>1</sub>, one bag<sub>2</sub> and five chain fibre poles did not receive motor innervation (for more information see Walro and Kucera, 1985a & b; Kucera *et al.*, 1988a; and Arbuthnott *et al.*, 1989).

## B. Results

### 1. Structure and arrangement of muscle spindles in deep masseter muscle

The results were obtained from one anterior spindle cluster which was serially sectioned transversely (section thickness 1  $\mu\text{m}$  approximately) and stained with toluidine blue. From the reconstruction of the spindles (see figure 45) it was found that this cluster consisted of 57 spindles which were arranged in parallel and partially overlapped for a distance of more than 6 mm. The total length of each spindle is correctly represented in figure 45, as is the length of the capsule plus the longest bag fibre at each pole. Table 13 shows the amount by which the bag and chain fibres extend beyond the capsule, from a sample of spindles. The mean length of a sample of 42 spindles of this cluster was 2959.5  $\mu\text{m}$  in a range of 950-4000  $\mu\text{m}$  and the mean length of 56 capsules was 1395  $\mu\text{m}$  in a range of 400-2600  $\mu\text{m}$ . However, the shortest spindle (14) was exceptional, since no other spindle was less than 2150  $\mu\text{m}$  in length, with a capsule length of no less than 950  $\mu\text{m}$ .

According to the morphological features of the intrafusal muscle fibres, three distinct types were recognized; bag<sub>1</sub>, bag<sub>2</sub> and chain fibres. The spindles contained 2-7 intrafusal muscle fibres. Usually each spindle possessed one bag<sub>1</sub>, one bag<sub>2</sub> and 2 or 3 chain fibres. One spindle contained only one bag<sub>1</sub> and one bag<sub>2</sub> (spindle no. 14), and some others contained one bag<sub>1</sub>, two bag<sub>2</sub> and 2-3 chain fibres (spindles nos. 5, 11 and 15). The feature of the spindles of which this cluster was composed were as follows:

**Table 13**

Sample of measurement of extension of intrafusal muscle fibres beyond the capsule ends. Results are arranged thus: proximal pole / distal pole ( $\mu\text{m}$ ).  
 - , the fibre terminated within or before the limit of the capsule.

Spindle no.	Bag <sub>1</sub>	Bag <sub>2</sub>	Bag <sub>2</sub> .	Chains				Capsule length
				i	ii	iii	iv	
1	850 / 100	1000 / 100		250 / 50	100 / 50	250 / 50		1450
2	900 / 50	950 / 50		400 / 50	400 / -			1450
3	650 / 200	750 / 200		100 / 100	- / 100	- / 200		1500
4	350 / 200	900 / 200		100 / 100	100 / 100			1250
5	450 / -	700 / 150	700 / 200	- / 200	- / 100			1400
7	550 / 500	500 / 450		- / 150	- / 150	- / -		1550
8	300 / 250	800 / 250		- / 100	- / 100			1450
9	850 / 450	550 / 400		- / -	- / -			2150
10	100 / 250	650 / 400		- / 400	- / -			2600
11	800 / 150	500 / 150	200 / -	100 / 50	- / 50	100 / -		1550
12	850 / 250	300 / 200		- / 200	- / 200			1400
13	950 / 1000	800 / 1700		100 / 200	- / -	100 / -		1350
15	200 / 1000	800 / 1050	650 / 900	- / -	- / -			1650
16	200 / 1050	300 / 1100		50 / 250				1100
17	1250 / 1000	1250 / 850		100 / -	- / -	- / -		1450

continued ...

Spindle No.	Bag <sub>1</sub>	Bag <sub>2</sub>	Bag <sub>2</sub> .	Chains				Capsule length
				i	ii	iii	iv	
18	$\frac{450}{800}$	$\frac{450}{750}$		$\frac{50}{-}$				1250
19	$\frac{1050}{1450}$	$\frac{700}{1500}$		$\frac{-}{50}$	$\frac{100}{50}$	$\frac{100}{50}$		1400
20	$\frac{550}{800}$	$\frac{550}{850}$		$\frac{350}{-}$	$\frac{50}{-}$			1300
21	$\frac{900}{1350}$	$\frac{900}{1400}$		$\frac{-}{300}$	$\frac{-}{150}$	$\frac{-}{-}$		1500
22	$\frac{500}{250}$	$\frac{650}{150}$		$\frac{-}{-}$	$\frac{-}{-}$	$\frac{-}{100}$		1900
23	$\frac{550}{450}$	$\frac{900}{550}$		$\frac{-}{-}$	$\frac{-}{-}$	$\frac{-}{-}$		1650
24	$\frac{-}{1350}$	$\frac{650}{1350}$		$\frac{-}{200}$	$\frac{-}{-}$	$\frac{-}{-}$	$\frac{-}{-}$	1550

<u>Bags</u>	Chains						<u>Total</u>
	0	1	2	3	4	5	
2	1	5	17	23	4	3	53
3			2	1			3
<b>Total</b>	1	5	19	24	4	3	56

Twelve spindle units were found in adjacent pairs, each pair sharing one capsule between the two units. The capsules were fused together in region A to enclose the two bundles in a common periaxial space. Those spindles were: 1+2, 8+11, 36+37, 40+50, 45+48 and 52+53.

In figure 46 spindles 1+2 were cut at their periaxial spaces and spindles 8+11 at their equatorial regions. In figure 49 spindles 37+38 were cut at their equatorial regions. In any single cross-section of this cluster between 20 and 31 spindles would appear cut at different levels, some cut through their equatorial regions, some cut at their polar regions. Others were sectioned beyond the end of spindle capsules (see figures 46-51).

Table 14 shows the measurement parameters for a sample of 22 spindles. Bag<sub>2</sub> fibres usually appeared longer than bag<sub>1</sub> fibres, the second bag<sub>2</sub> (bag<sub>2</sub>.) fibres, when present, were shorter than bag<sub>1</sub> and bag<sub>2</sub> fibres. Chain fibres were shorter than bag<sub>1</sub> and bag<sub>2</sub> fibres, 66% were longer than the capsules, 30% were shorter than the capsules and only 4% of them ended with the capsule ends on both sides of the spindle. Some chain fibres were seen to end at the equatorial region. Two chain fibres (arrows) in two spindles were branched (spindles no. 6 and 24).

Diameters of the three fibre types in transverse section in each of the three regions (A, B and C) were measured. The number of nuclei abreast in the equatorial region was counted. These results are shown



**Table 14**

Sample of length measurements of intrafusal muscle fibres and capsules ( $\mu\text{m}$ ), calculated from table 13.

Spindle no.	Bag <sub>1</sub>	Bag <sub>2</sub>	Bag <sub>2</sub> .	Chains				Capsule length
				i	ii	iii	iv	
1	2400	2550		1750	1600	1750		1450
2	2400	2450		1900	1850			1450
3	2350	2450		1700	1600	1550		1500
4	1800	2350		1450	1450			1250
5	1850	2250	2300	1600	1500			1400
7	2600	2500		1700	1700	1450		1550
8	2000	2500		1550	1550			1450
9	3450	3100		2100	1950			2150
10	2950	3650		3000	1500			2600
11	2450	2150	1700	1650	1550	1600		1550
12	2500	1900		1600	1600			1400
13	3300	3850		1650	1250	1450		1350
15	2850	3500	3200	1650	1600			1650
16	2350	2500		1400				1100
17	3600	3450		1450	1400	1150		1450
18	2500	2400		1300				1250
19	3900	3600		1450	1550	1550		1400
20	2650	2700		1650	1350			1300
21	3750	3800		1800	1650	350		1500
22	2650	2700		1600	1400	1400		1900
23	2650	3100		1650	1600	1150		1650
24	2900	3550		1750	{ 1350 600	1500	1150	1550
Mean	2720	2863	2440	1698	1550	1354.4	1150	1538.6

**Table 15**

Diameter measurements ( $\mu\text{m}$ ) at different levels for intrafusal muscle fibres and for capsules at equator region. Numbers of nuclei abreast in bag fibres.

m.f. region	b <sub>2</sub>					b <sub>1</sub>					b <sub>2</sub> '					Ci			Cii			Ciii			cap at m. equat
	C	B	A			C	B	A			C	B	A			B	A		B	A					
			pr.	eq.	n.			pr.	eq.	n.			pr.	eq.	n.		pr.	eq.		pr.	eq.	pr.	eq.		
1	10.0	9.0	6.9	3.0	3	9.8	9.3	7.0	3.5	3					7.8	6.7	3.3	7.4	5.3	3.0	7.0	5.3	3.1	82.0	
2	8.0	9.0	7.7	3.6	2	11.3	10.1	7.6	4.0	4					9.4	4.5	3.1	10.3	6.0	3.2				82.0	
3	10.1	9.4	7.8	3.5	2	14.0	9.2	7.0	2.5	1					8.9	7.0	3.0	8.2	7.0	3.0	7.7	6.8	3.0	64.0	
4	10.3	8.5	6.8	3.5	2	9.5	7.7	6.5	2.0	2					7.6	6.0	2.0	8.1	6.2	2.0				45.0	
5	10.0	9.5	6.5	3.0	3	6.0	5.5	7.2	2.5	2	6.0	5.5	5.5	2.0	2	7.0 <sup>+</sup>	6.5	2.7	6.5	6.5	2.7				60.5
6	12.0	10.0	8.5	3.8	2	12.0	8.0	6.2	3.5	3					5.5	4.5	2.5	6.0	5.3	2.0				52.3	
7	10.1	8.5	6.7	3.5	4	7.7	7.5	5.6	3.5	3					6.0 <sup>+</sup>	4.5	2.5	8.5	5.5	2.8	6.8	4.4	2.5	60.0	
8	9.3	8.5	7.5	2.5	2	7.5	7.5	7.4	3.5	4					7.0	6.6	3.0	7.0	6.5	3.0				82.5	
9	10.6	9.5	9.3	4.0	2	9.5	7.8	8.3	3.5	2					6.3	6.0	3.2	6.3	6.1	3.2				55.5	
10	10.1	9.4	6.6	3.6	3	8.4	9.3	6.6	3.2	2					7.9 <sup>+</sup>	6.2	2.8	8.0	6.2	2.8				50.0	
11	10.5	9.1	8.0	3.0	3	6.5	8.8	7.2	2.5	3	6.5	8.8	6.9	2.5	1	8.0 <sup>+</sup>	6.6	3.0	7.2	6.5	3.0	7.2	6.5	2.8	82.5
12	7.5	7.5	6.5	3.5	3	7.2	7.5	5.5	3.0	3					6.5 <sup>+</sup>	5.2	2.0	6.5	5.0	2.0				43.3	
15	9.6	9.0	7.0	3.5	3	8.3	8.8	5.5	3.5	3	8.5	8.5	6.5	3.5	3	6.5	6.0	2.5	6.5	6.0	2.5				80.0
16	7.5	7.5	7.0	3.5	2	7.5	7.0	6.8	3.0	1					6.0	5.5	3.0	-	-	-				51.0	
17	10.0	8.0	7.0	3.0	3	9.0	8.0	7.0	2.8	3					5.7	7.0	2.5	4.0	6.0	2.5	4.4	4.0	2.5	62.5	
18	8.7	8.5	6.2	2.5	3	8.2	7.2	6.5	2.0	2					-	3.0	2.0	-	-	-				39.5	
20	7.2	8.2	7.5	3.0	2	6.2	6.5	6.3	3.0	2					6.0	7.0	2.5	6.5	9.0	2.0				44.0	
21	9.3	8.3	7.8	2.5	3	7.7	8.3	7.0	2.0	3					7.0	7.0	2.0	6.3	7.0	2.0				70.5	
22	12.0	10.4	7.8	3.5	3	9.0	8.7	6.8	3.2	2					7.7 <sup>+</sup>	6.0	2.5	-	6.0	2.5	-	6.5	2.5	66.3	
23	8.3	7.4	6.4	3.5	3	8.8	7.4	6.7	3.0	3					6.2	6.3	2.0	5.5	6.3	2.0	5.5	6.8	2.0	51.5	
mean	9.55	8.76	7.28	3.28	2.7	8.70	8.00	6.73	2.98	2.5	7.0	7.6	6.3	2.7	2	7.00	5.90	2.60	6.98	6.26	2.56	6.43	5.76	2.62	61.2
SE	0.303	0.184	0.176	-	-	0.443	0.243	0.156	-	-	0.764	1.054	0.416	-	-	0.249	0.240	-	-	-	-	-	-	-	-

abbreviations:

A : region A  
 B : region B  
 C : region C  
 pr. : periaxial region  
 eq. : mid equatorial region  
 n. : number of nuclei abreast in bag fibres  
 + : long chain fibre  
 sp. : spindle  
 i.m.f. : intrafusal muscle fibre

b<sub>1</sub> : bag<sub>1</sub> fibre  
 b<sub>2</sub>, b<sub>2</sub>' : bag<sub>2</sub> fibre  
 Ci, Cii, Ciii : chain fibres  
 cap : capsule

share capsule:

sp. 1 & sp. 2  
 sp. 8 & sp. 11

in Table 15. Using Student's t test, bag<sub>2</sub> fibres were significantly larger in diameter than bag<sub>1</sub> fibres in each of the three regions (see figure 51). The diameter of bag<sub>2</sub> fibres appeared to be similar to that of bag<sub>1</sub> fibres (see spindles 5 and 11, figure 51). In the equatorial region, bag<sub>2</sub> fibres usually possessed more nuclei abreast (2-4) than bag<sub>1</sub> fibres (1-4), whilst chain fibres contained only one nucleus. The diameters of the three fibre types showed less variation from each other elsewhere along the spindle. In mid-polar regions bag<sub>1</sub> and chain-fibre diameters were usually similar. Using a t test for a sample of intrafusal muscle fibre diameters (see Table 16), it was found that the diameter of bag<sub>2</sub> fibres and bag<sub>1</sub> fibres were significantly different in the three regions. The diameters of bag<sub>2</sub> and bag<sub>2</sub> fibres were significantly different only in region C. The diameters of bag<sub>1</sub> and bag<sub>2</sub> were not significantly different in any region, whereas diameters of bag<sub>1</sub> and chain fibres were significantly different in all regions.

The mean diameter for a sample of 20 capsules at their mid-equators was 61.25  $\mu\text{m}$  in a range of 39.5-82.5  $\mu\text{m}$ .

Elastic fibres were associated with all the three fibre types, but in regions C and B they were particularly associated with one of the bag fibres, which was therefore identified as the bag<sub>2</sub>, see for example, spindles no. 15, 17, 18, 20, 22, 23, 26 and 27 (figure 51) and from teased silver preparation (see figure 65). Note that some elastic fibres were associated with chain fibres, for example in spindles no. 4, 7, 9 and 10 (figure 51).

One tandem muscle spindle was observed, spindle no. 6 (figures 46-52), which consisted of three unconnected capsules linked in linear succession by a single bag<sub>2</sub> fibre (figure 52). The total length of this spindle was 6.15 mm. Capsule 1 contained two chain fibres (Ci and

**Table 16**

t-test of diameters of intrafusal fibre types in rat deep masseter in different regions.

i.m.f.	region	b <sub>2</sub>			b <sub>1</sub>			b <sub>2</sub> .			Ci	
		C	B	A(pr)	C	B	A(pr)	C	B	A(pr)	B	A(pr)
b <sub>2</sub>	C	-	-	-	*** 6.9096	-	-	*** 3.8336	-	-		
	B	-	-	-	-	** 3.4146	-	-	1.9448	-		
	A(pr)	-	-	-	-	-	*** 10.0025	-	-	2.0188		
b <sub>1</sub>	C				-	-	-	1.4295	-	-	-	-
	B				-	-	-	-	0.5783	-	** 2.8862	-
	A(pr)				-	-	-	-	-	1.0010	*** - 12.5448	
b <sub>2</sub> .	C											
	B										0.8235	-
	A(pr)										-	0.6084

b<sub>1</sub>: bag<sub>1</sub> fibre

b<sub>2</sub> b<sub>2</sub>.: bag<sub>2</sub> fibre

Ci: chain fibre

pr: periaxial space

i.m.f.: intrafusal muscle fibre

\* : significant (P < 0.05)

\*\* : highly significant (P < 0.01)

\*\*\* : very highly significant (P < 0.001)

Cii) and one bag<sub>1</sub> fibre passed through capsule 2 to end in the periaxial space of capsule 3. Capsule 2 contained two chain fibres: one of them (Civ) branched into two; the distal end of the other chain fibre (Ciii) extended 400  $\mu\text{m}$  beyond the distal end of capsule 2, and the proximal end extended 50  $\mu\text{m}$  beyond the proximal end of capsule 3. Capsule 3 contained one bag<sub>1</sub> fibre; its distal end passed through the proximal polar region of capsule 2 and came out from its wall to end in connective tissue. Two chain fibres (Cv and Cvi) additional to Ciii were found within this capsule.

## 2. Analysis of silver preparations

### 2.1. Number of spindles

Seventy-seven spindles were teased from the anterior clusters of two silver-impregnated, deep masseter muscles (40 from the first and 37 from the second) for analysis of the sensory innervation. The arrangement of the spindles was similar to that described on the basis of the reconstruction (figure 53). Samples of spindles were also teased from hindlimb muscles, peroneus longus, lumbrical and soleus, and used for comparative study of the sensory innervation.

### 2.2. The form of terminals

The terminals of the primary endings were annulospiral on both bag and chain fibres. They were thicker and wider on the bag fibres than on chain fibres (see figures 54-56 and figures of plates 10 and 11). In the mid-equatorial regions of bag fibres the turns were set more closely than on the immediately adjacent regions (see figure 55, figures 58, 60b plate 10, and figure 61a plate 11). In some of the preparations, nuclei of intrafusal fibres were visible (see figures 57,

60 plate 10, and figure 62a plate 11), and in others the elastic fibres were seen very clearly associated with the polar regions of the bag<sub>2</sub> fibres (see figure 65). Hence the analysis could be made for each fibre type with confidence. The number of bands per unit length appeared to be more in bag<sub>1</sub> than in bag<sub>2</sub> fibres (see figure 54d). The secondary endings were distributed to both bag and chain fibres usually in the form of fine sprays, though some coils and spirals were present particularly close to primary endings (see figures 54e & f, 59a, 60a plate 10, and figures 61, 62a, 63 plate 11).

### 2.3. Diameters of afferent fibres and length of sensory endings

Samples of spindles from deep masseter, peroneus longus and lumbrical muscles were chosen in order to obtain measurements of the primary and secondary afferent diameters and lengths of primary and secondary terminals. The selection was based on criteria of superior staining, good teasing quality and unbroken afferents. The results are shown in Table 17. The mean diameter of primary afferents in deep masseter and peroneus longus muscles were approximately similar to each other, whereas that of lumbrical muscles was smaller. The mean diameter of secondary afferents in each of the three muscles were approximately similar. Histograms in figure 66 show the percentage of primary and secondary axon diameters of deep masseter spindles.

The mean lengths of primary endings in masseter and peroneus longus spindles were closely similar, and longer than that in lumbrical spindles. The mean length of secondary endings was greatest in lumbrical and smallest in deep masseter spindles (see table 17).

### 2.4. Branching and distribution of sensory endings

i) Deep masseter muscle: The features of the sensory innervation of

**Table 17**

Samples of measurements of diameters for primary and secondary axons, lengths of primary and secondary endings of muscle spindles from different muscles of rat.

muscle	region	no. of axons	diameter of axons ( $\mu\text{m}$ )		no. of endings	length of endings ( $\mu\text{m}$ )	
			range	mean		range	mean
masseter	P	143	2.2-6.0	3.65	50	70-386	247.44
	S	50	1.1-4.9	2.34	60	20-225	101.1
peroneus longus	P	34	3.1-4.6	3.85	17	120-325	241.0
	S	16	1.6-3.5	2.78	12	110-220	157.5
lumbrical	P	12	1.9-3.6	2.56	9	105-250	169.0
	S	4	2.0-3.5	2.47	7	90-350	193.0

P: primary ending

S: secondary ending

the 77 spindle units of deep masseter muscles studied, and their afferents distribution are shown in Table 18. Altogether 263 afferents at spindle entry were distributed to the spindles in thirty different arrangements.

Each spindle received from 1-6 afferents. All sensory terminals in the equatorial regions, and which therefore formed primary endings or parts of primary endings, were supplied by large diameter axons (see figures 54, 55, 56 and figures in plates 10 and 11). A total of 173 afferents contributed to primary (single and multiple) endings; 81 afferents ended in secondary endings, this number included 8 afferents which branched to two secondary endings; and nine afferents which branched to end in primary and secondary endings, for example see figures 55 and 61, 63, plate 11.

A new phenomenon has been seen in this study: some afferents were found branched to supply primary endings to two bag fibres, usually bag<sub>1</sub>, in separate spindles (see figures 54 and 56). In one sample consisting of 37 spindles, the number of their afferents was 130, but at the spindle entry the total was 137 due to 7 axons that branched.

Twenty spindles of the two spindle clusters contained only primary endings (P); one P, 6 spindles; two P, 9 spindles; three P, 4 spindles and four P, 1 spindle. The other 57 spindles contained primary (single or multiple) plus up to 3 secondary endings. 26% of the total spindles above received only primary (single or more) endings, for more detail see Table 22.

ii) Peroneus longus muscle: Eighty three spindles were teased out from 6 muscles and their sensory innervation studied. The afferents were distributed in 15 arrangements mostly similar to those seen in deep masseter. Table 19 shows the distribution of their endings and afferents. Another new phenomenon was seen this time: a spindle



Table 18

Sensory innervation of rat deep masseter muscle spindles

(a)	<u>Type of sensory innervation</u>	<u>No. of afferents</u>	<u>No. of each type observed</u>	(b)	<u>Summary of the innervation</u>
1	P	1	6		only P = 26%
2	P P	2	9		P + 1S = 29%
3	P P P	3	4		P + 2S = 38%
4	P P P P	4	1		P + 3S = 8%
5	P S <sub>1</sub>	2	2		
6	$\overline{S_1 P S_1}$	2	1		one P afferent = 16%
7	P S <sub>1</sub> S <sub>2</sub>	3	1		multiple P afferents = 84%
8	S <sub>1</sub> P S <sub>1</sub> S <sub>2</sub>	4	2		
9	P P S <sub>1</sub>	3	9		
10	P $\overline{P S_1}$	2	1		
11	S <sub>1</sub> P P S <sub>1</sub>	4	7	(c)	Total of afferent = 263
12	$\overline{S_1 P P S_1}$	3	4		
13	$\overline{S_1 P P S_1}$	3	1		Ia = 173
14	P P S <sub>1</sub> S <sub>2</sub>	4	1		II = 81 (including 8 branched to 2 secondary endings)
15	P P $\overline{S_1 S_2 S_2}$	4	1		branched Ia + II = 9
16	S <sub>1</sub> P P S <sub>1</sub> S <sub>2</sub>	5	1		
17	P P P S <sub>1</sub>	4	5		
18	P P $\overline{P S_1}$	3	1		
19	S <sub>1</sub> P P P S <sub>1</sub>	5	4		
20	$\overline{S_1 P P P S_1}$	4	1	(d)	<u>No. of afferents</u> <u>Frequency of occurrence</u>
21	$\overline{S_1 P P P S_1}$	4	1		1                      6
22	P P P S <sub>1</sub> S <sub>2</sub>	5	2		2                      13
23	P P P $\overline{S_1 S_2}$	4	1		3                      20
24	P P $\overline{P S_1 S_1}$	4	1		4                      22
25	$\overline{S_1 P P P S_1 S_1}$	5	1		5                      13
26	S <sub>2</sub> P P $\overline{P S_1}$	4	1		6 $\frac{3}{77}$
27	P P P P S <sub>1</sub>	5	4		
28	P P P P S <sub>1</sub> S <sub>1</sub>	6	1		
29	S <sub>1</sub> P P P P S <sub>1</sub>	6	2		
30	$\overline{S_1 P P P P S_1 S_1}$	5	$\frac{1}{77}$		

Symbols: P, primary endings  
 S, secondary endings  
 Ia, primary afferent  
 II, secondary afferent  
 — indicates common nerve supply

Table 19

Sensory innervation of rat peroneus longus muscle spindles

(a) <u>Type of sensory innervation</u>	<u>No. of afferents</u>	<u>No. of each type observed</u>	(b) <u>Summary of innervation</u>
1 P	1	17	only P = 42%
2 P P	2	18	P + 1S = 33%
3 P S <sub>1</sub>	2	7	P + 2S = 21%
4 S <sub>1</sub> P S <sub>1</sub>	3	5	P + 3S = 4%
5 $\overline{S_1 P S_1}$	2	4	
6 S <sub>1</sub> P S <sub>1</sub> S <sub>1</sub>	4	1	one P afferent = 41%
7 P P S <sub>1</sub>	3	17	multiple P afferents = 59%
8 P $\overline{P S_1}$	2	3	
9 S <sub>1</sub> P P S <sub>1</sub>	4	3	
10 S <sub>1</sub> P P S <sub>1</sub> S <sub>2</sub>	5	1	
11 S <sub>1</sub> P $\overline{P S_1}$	3	3	(c) Total of afferents = 191
12 P $\overline{P S_1}$ S <sub>2</sub>	3	1	Ia = 124
13 S <sub>1</sub> P $\overline{P S_1}$ S <sub>1</sub>	4	1	II = 58 (including 1 branched to 2 secondary endings)
14 $\overline{S_1 P P S_1}$	2	1	branched Ia + II = 9
15 S <sub>1</sub> P P P S <sub>1</sub>	5	<u>1</u>	
		83	

(d) <u>No. of afferents</u>	<u>Frequency of occurrence</u>
1	17
2	33
3	26
4	5
5	<u>2</u>
	83

Use of the symbols is explained in Table 18.

innervated by two primary afferents, one of them gave two branches to two secondaries, one on each spindle pole.

iii) Lumbrical and soleus muscles: The sensory innervation of spindles in lumbrical and soleus muscles contained single and double primary endings. In lumbrical muscles 62% of the spindles possessed one primary ending, whereas in soleus muscles 62% of the spindles contained a double primary ending. Branching and distribution of afferents were the same as in deep masseter and peroneus muscles, except that afferent branching between secondary endings was not seen in soleus spindles. Tables 20 and 21 show the distributions of the sensory endings and afferents. Table 22 shows a summary of the percentage of each type of innervation in the spindles of the four muscles.

#### 2.5. Skeleto-fusimotor innervation, $\beta$ axons

This study revealed the presence of  $p_1$  plate type of motor endings as collateral branches of  $\beta$  fibres innervating spindle poles in rat masseter muscle. Three definite examples of  $\beta$  innervation were found, in teased silver preparations, supplying some spindles of the anterior clusters together with adjacent extrafusul muscle fibres. The common origin of the intra- and extrafusul were preserved (figure 67). In each case the plate endings were confined to the polar regions of bag<sub>1</sub> fibres (figure 68), the fibres being identified by their length, diameter and lack or scarcity of elastic fibres. Similar plates were often seen on the bag<sub>1</sub> fibres of other spindles in the cluster.

Table 20

Sensory innervation of rat lumbrical muscle spindles

(a)	<u>Type of sensory innervation</u>	<u>No. of afferents</u>	<u>No. of each type observed</u>
1	P	1	3
2	P P	2	1
3	P S <sub>1</sub>	2	3
4	$\overline{S_1 P S_1}$	2	1
5	$\overline{S_1 P S_1} S_2$	3	1
6	P $\overline{P S_1}$	2	3
7	$\overline{S_1 P P S_1} S_2$	3	<u>1</u>
			13

(b) Summary of innervation

only P = 31%  
 P + 1S = 46%  
 P + 2S = 8%  
 P + 3S = 15%

one P afferent = 62%  
 multiple P afferents = 38%

(c) Total of afferents = 25

Ia = 13  
 II = 7 (including 2 branched to 2 secondary endings)  
 branched Ia + II = 5

(d) No. of afferents      Frequency of occurrence

1                      3  
 2                      8  
 3                      2

13

Use of the symbols is explained in Table 18.

Table 21

Sensory innervation of rat soleus muscle spindles

(a)	<u>Type of sensory innervation</u>	<u>No. of afferents</u>	<u>No. of each type observed</u>
1	P	1	4
2	P P	2	10
3	P S <sub>1</sub>	2	5
4	S <sub>1</sub> P S <sub>1</sub>	3	1
5	P P S <sub>1</sub>	3	4
6	P $\overline{P S_1}$	2	1
7	S <sub>1</sub> P P S <sub>1</sub>	4	<u>1</u>
			26

Use of the symbols is explained in Table 18.

(b) Summary of innervation

only P = 54%  
P + 1S = 38%  
P + 2S = 8%

one P afferent = 38%  
multiple P afferents = 62%

(c) Total of afferents = 55

Ia = 41  
II = 12  
branched Ia + II = 2

(d) No. of afferents      Frequency of occurrence

1	4
2	16
3	5
4	<u>1</u>
	26

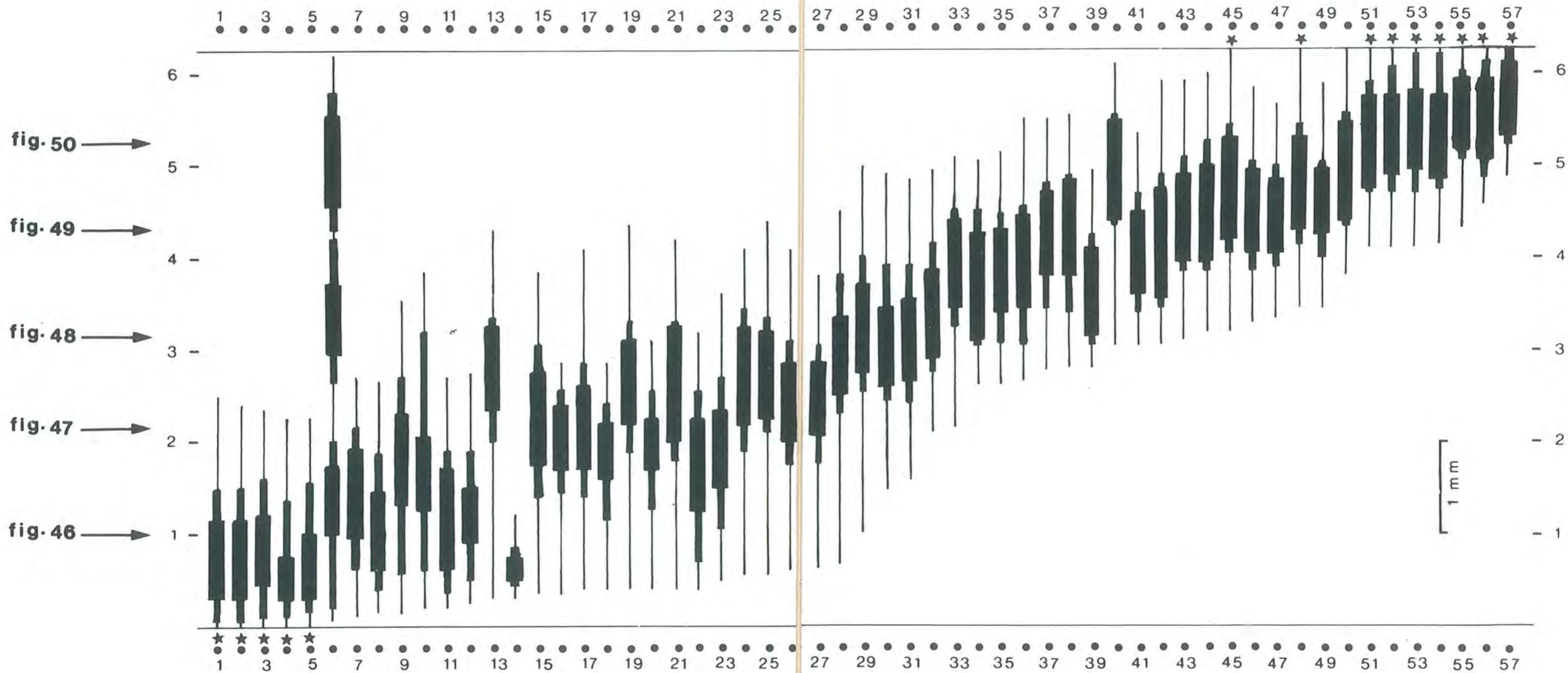
Table 22

A summary of the percentage of each feature of innervation of spindles in different muscles.

muscle	one P afferent	multiple P afferents	P only	P + 1S	P + 2S	P + 3S	no. of spindles examined
masseter	16%	84%	26%	29%	38%	8%	77
peroneus longus	41%	59%	42%	33%	21%	4%	83
lumbrical	62%	38%	31%	46%	8%	15%	13
soleus	38%	62%	54%	38%	8%	-	26

P: primary endings  
S: secondary endings

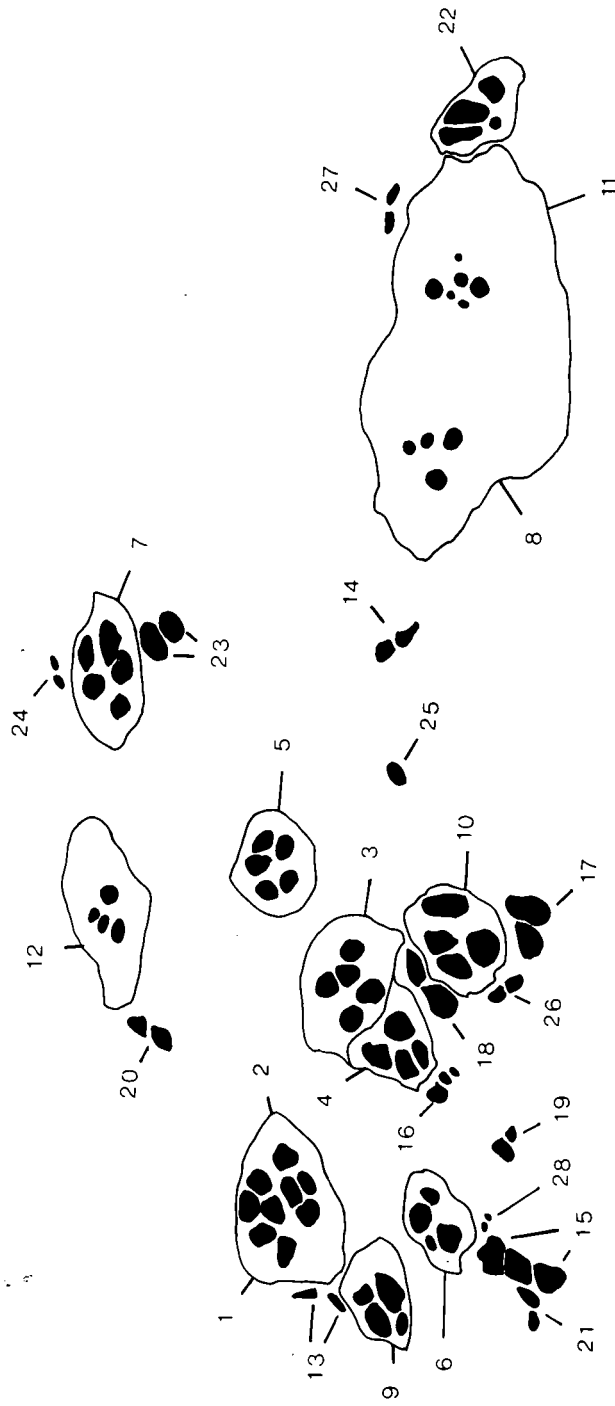
**Figure 45.** Schematic representation of an anterior spindle-cluster of the rat deep masseter composed of 57 spindles, reconstructed from serial transverse 1  $\mu$ m thick plastic sections. The bag muscle fibres of each spindle are represented as a single line, the capsule as a thickening of this line, further thickening indicating the length of the periaxial space. Stars indicate incomplete poles. Arrows indicate the plane of section illustrated in figures 46-50. Spindle no. 6 consisted of three spindle units in tandem, sharing one common bag<sub>2</sub> fibre.

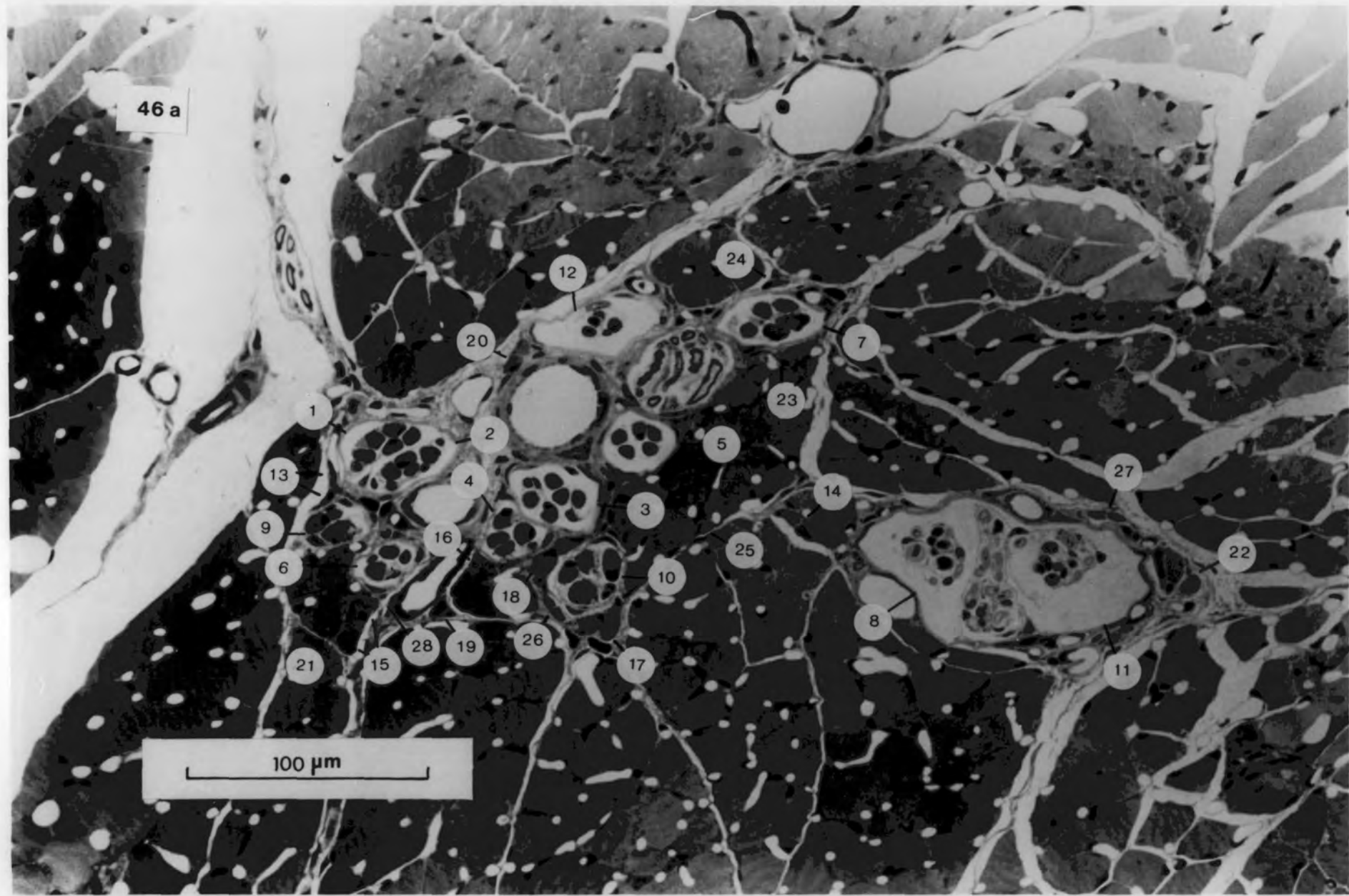




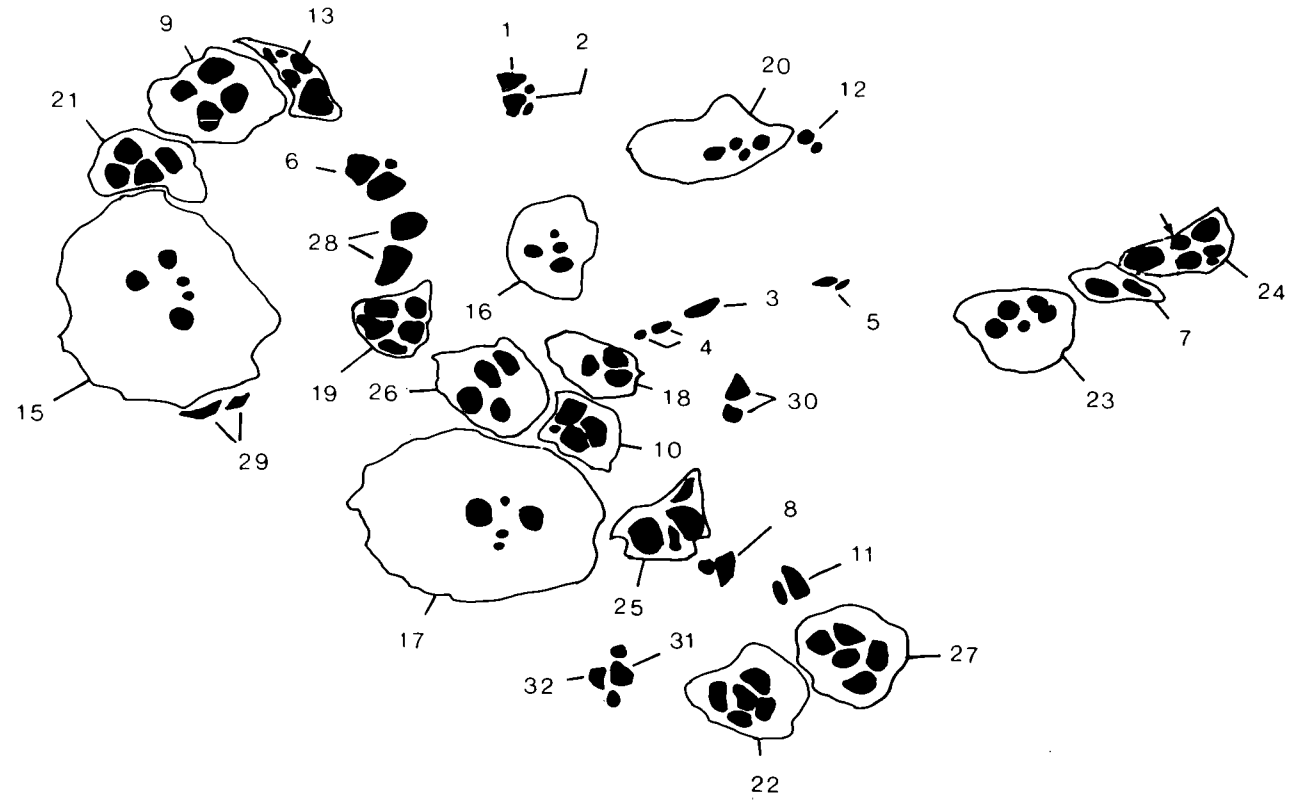
**Figures 46a-50a.** Photographs of toluidine blue-stained (1  $\mu\text{m}$ -thick) transverse plastic sections of the anterior spindle-cluster of the rat deep masseter muscle reconstructed in figure 45. Individual spindles are identified by numbers corresponding to those in figure 45. Each section contained 20-31 spindles cut at different levels. Note that some spindles shared a capsule.

**Figures 46b-50b.** Line drawings of the intrafusal muscle fibres and capsules shown in 46a-50a. Scale indicated in figure 46 refers to all figures.

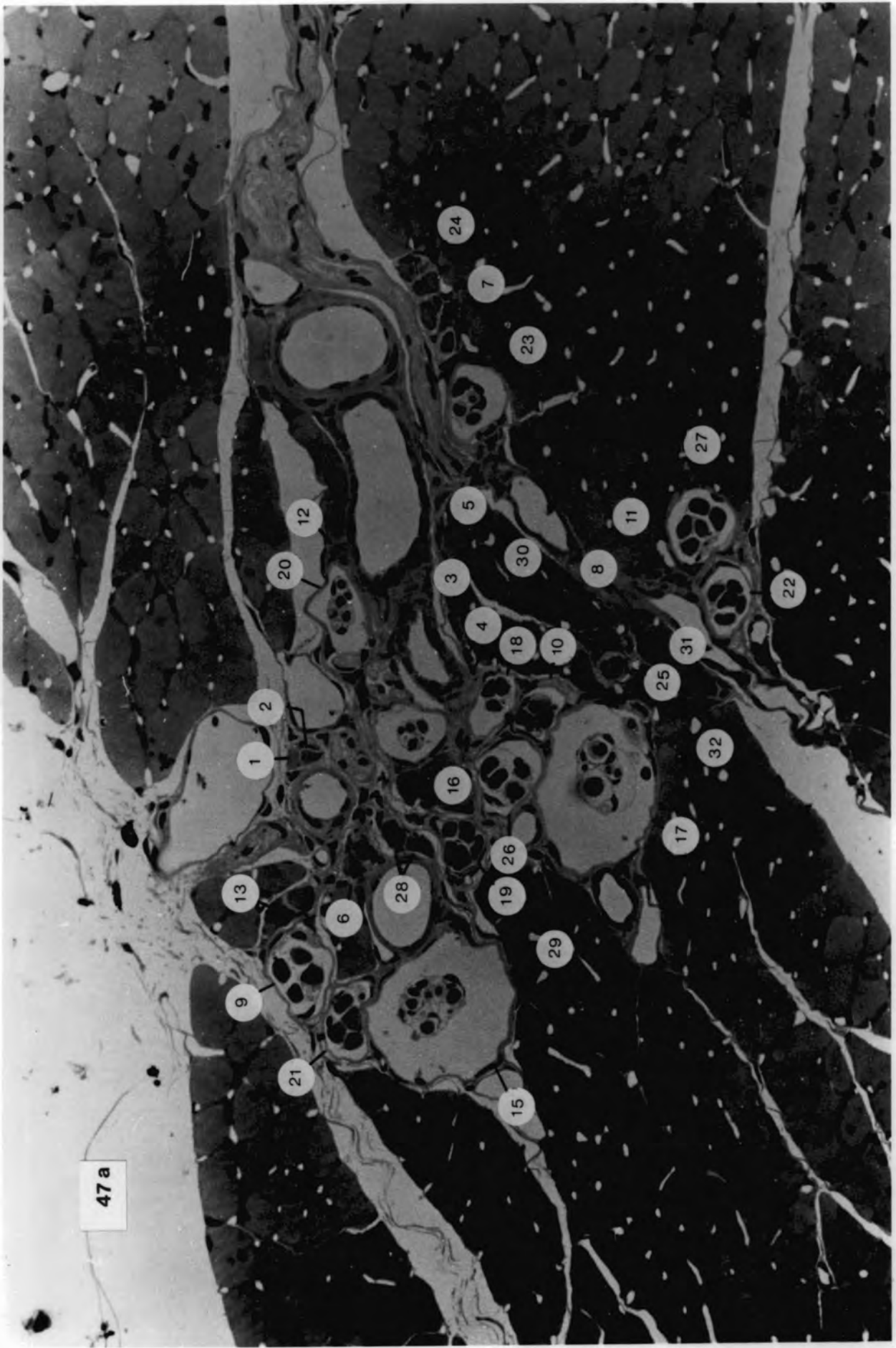




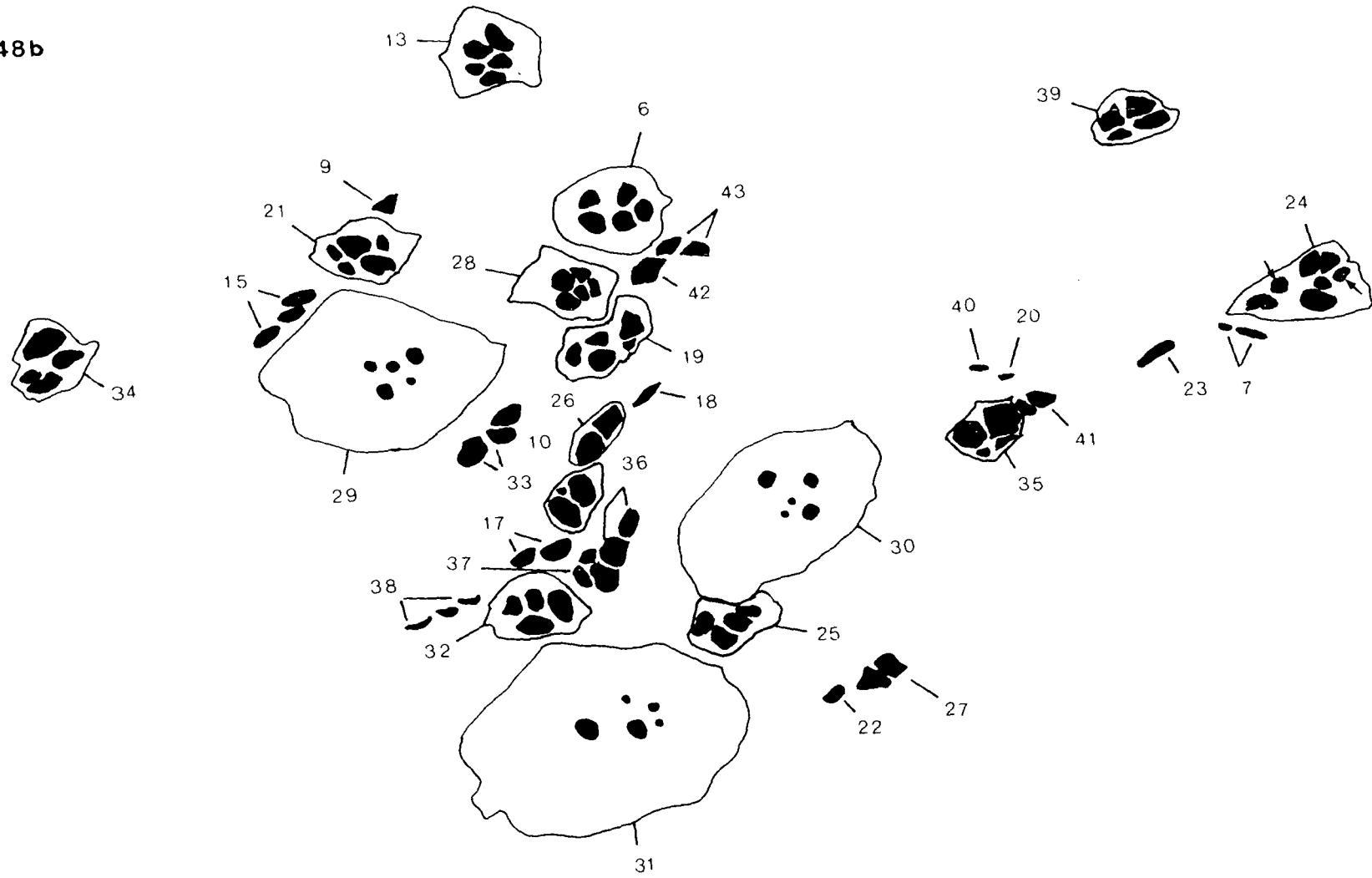
47b

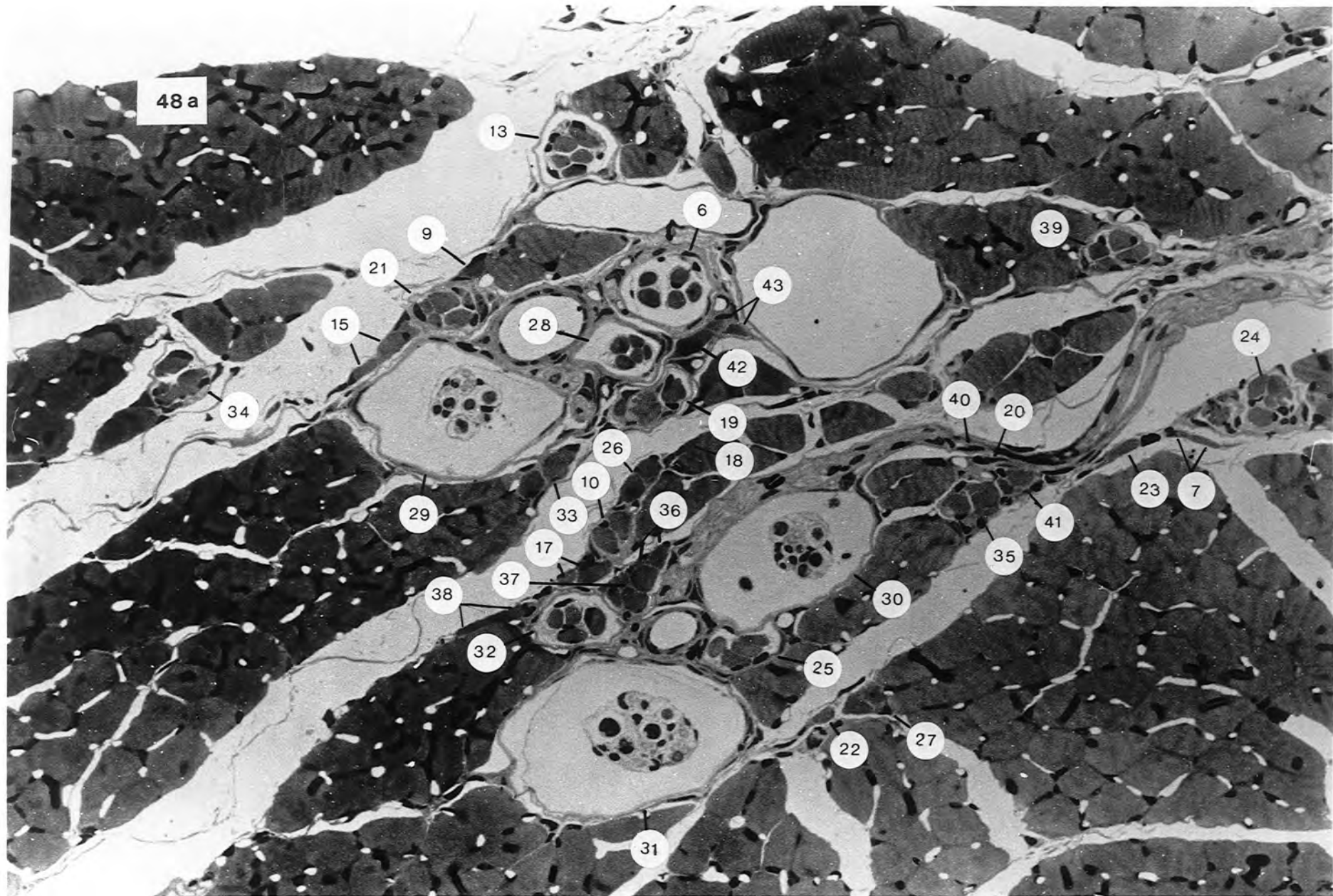


47 a

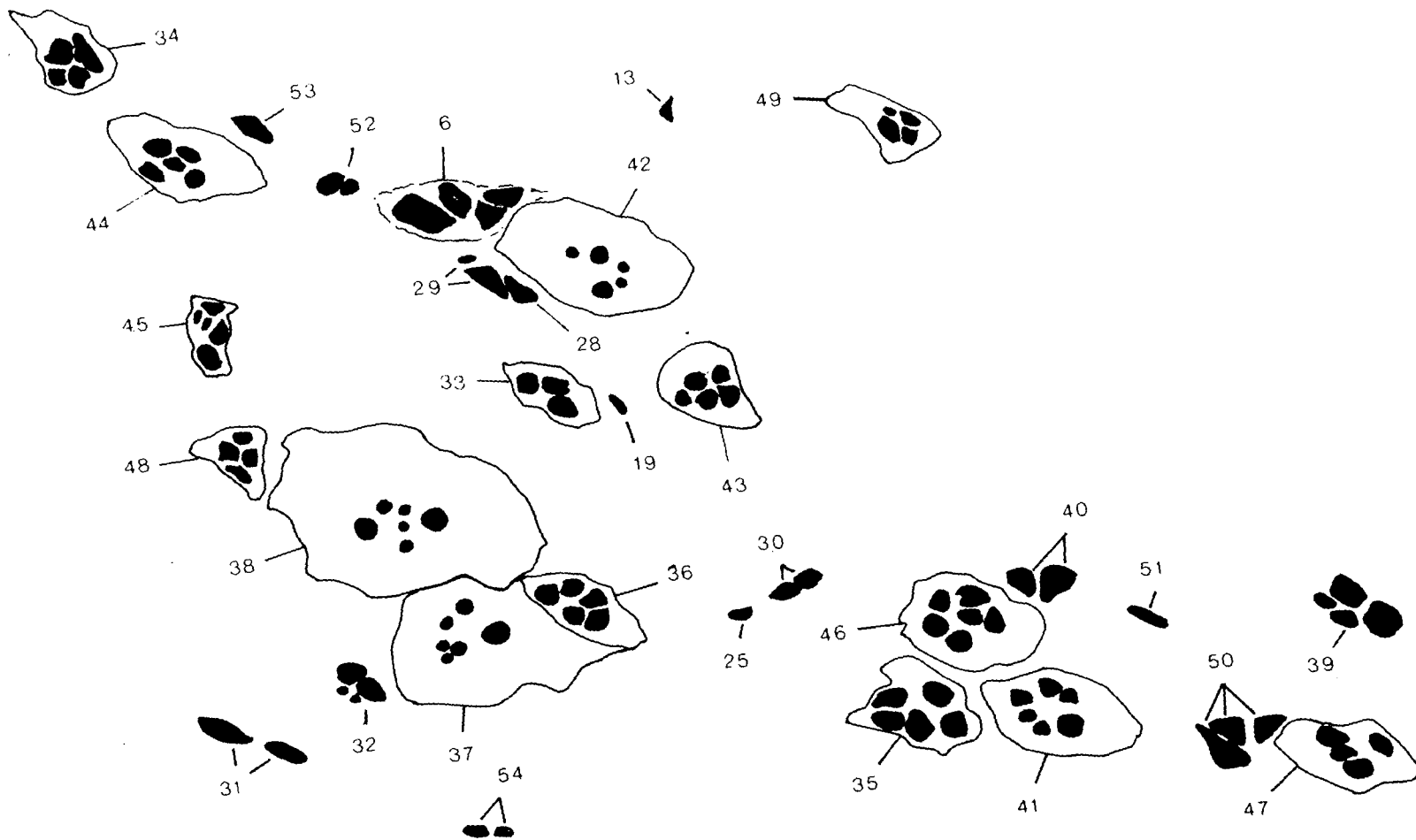


48b

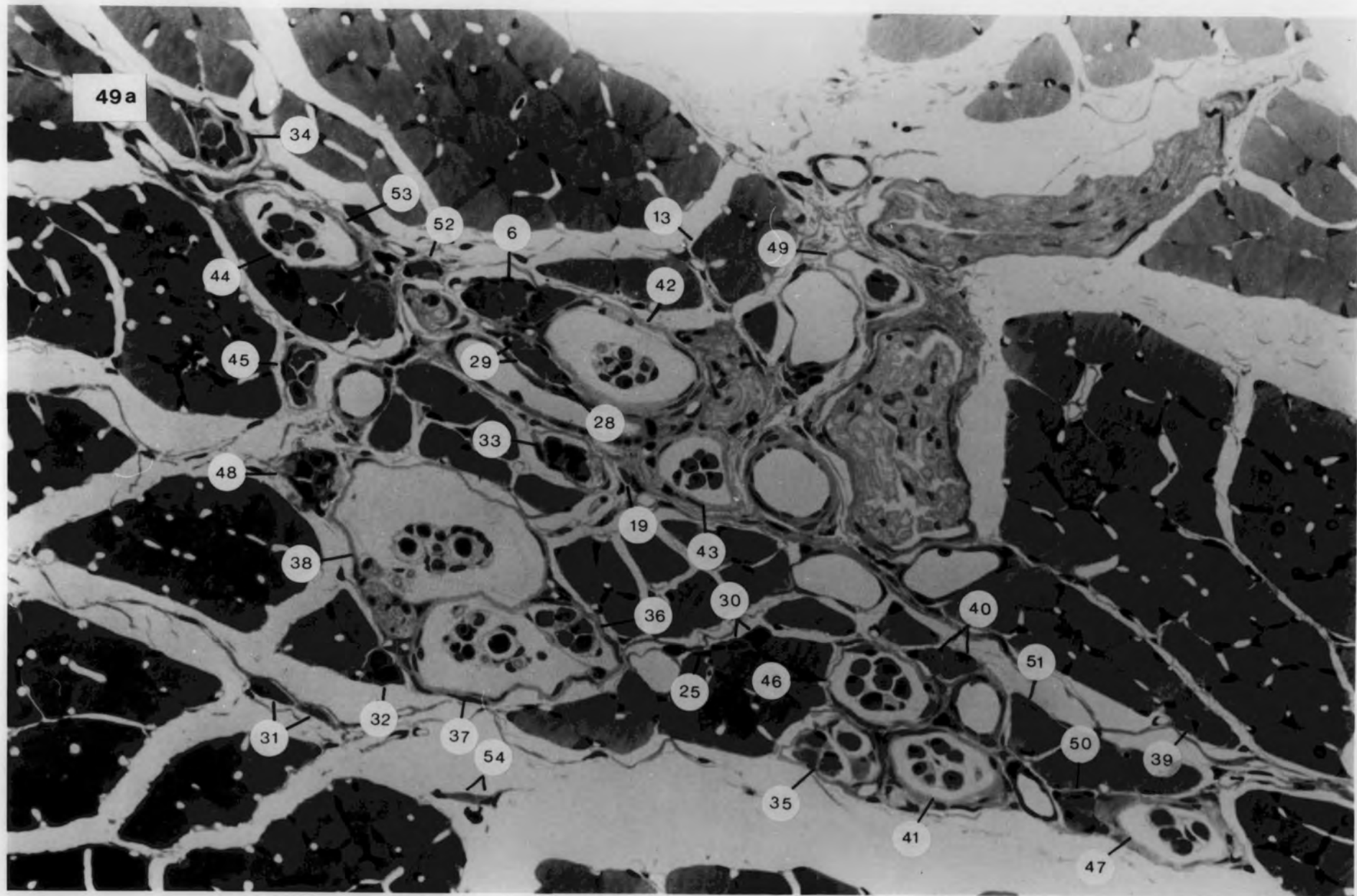




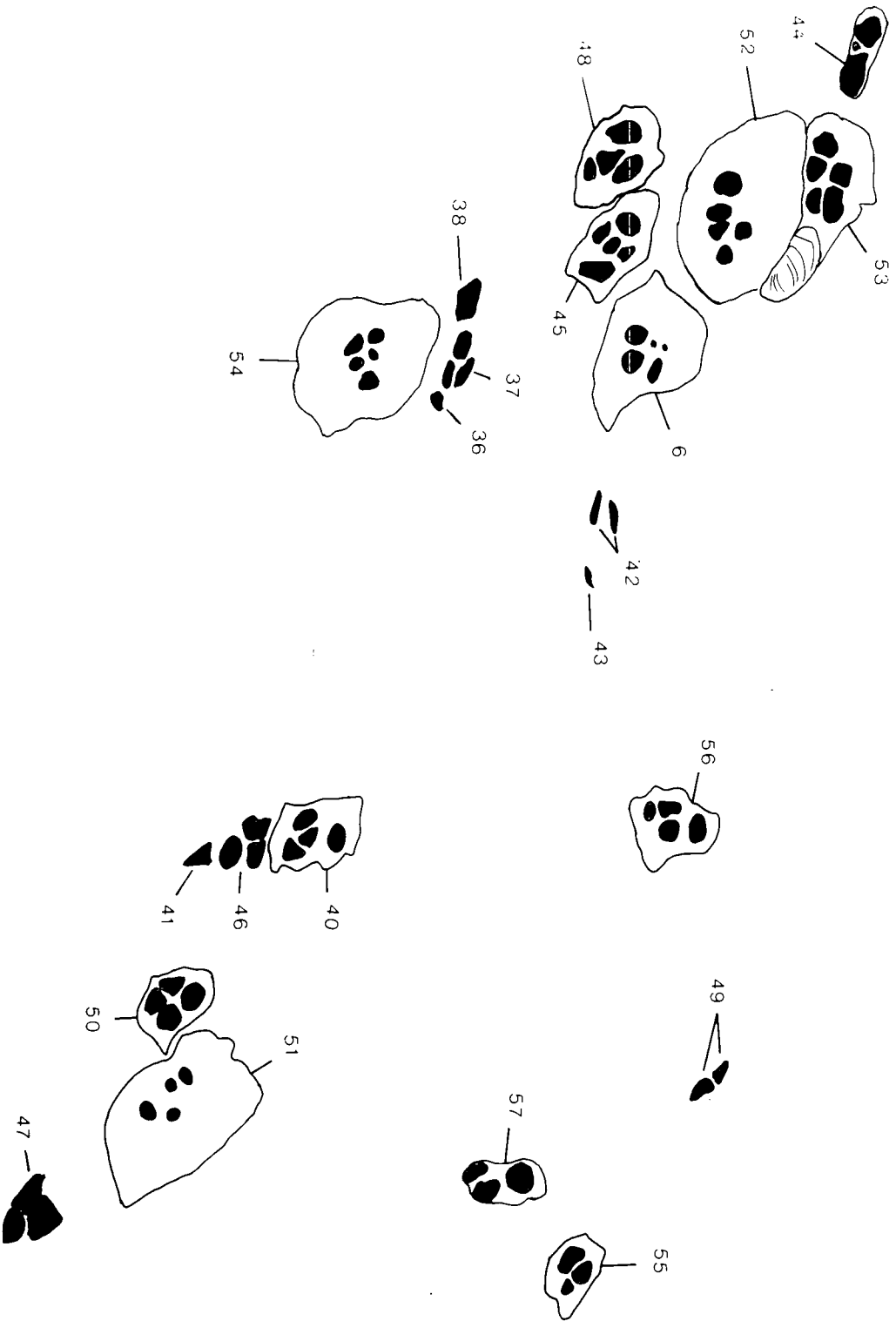
49b

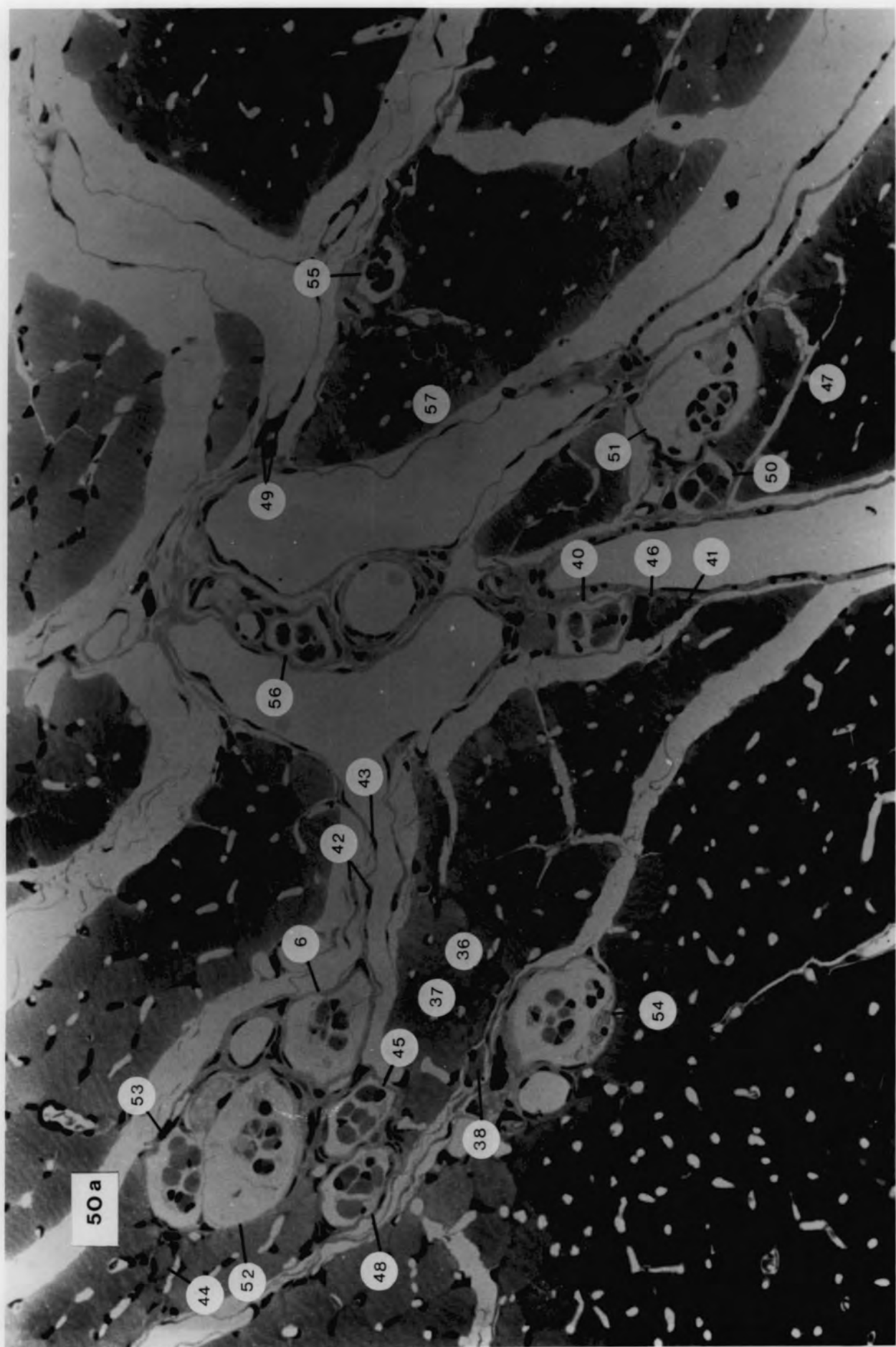






50b

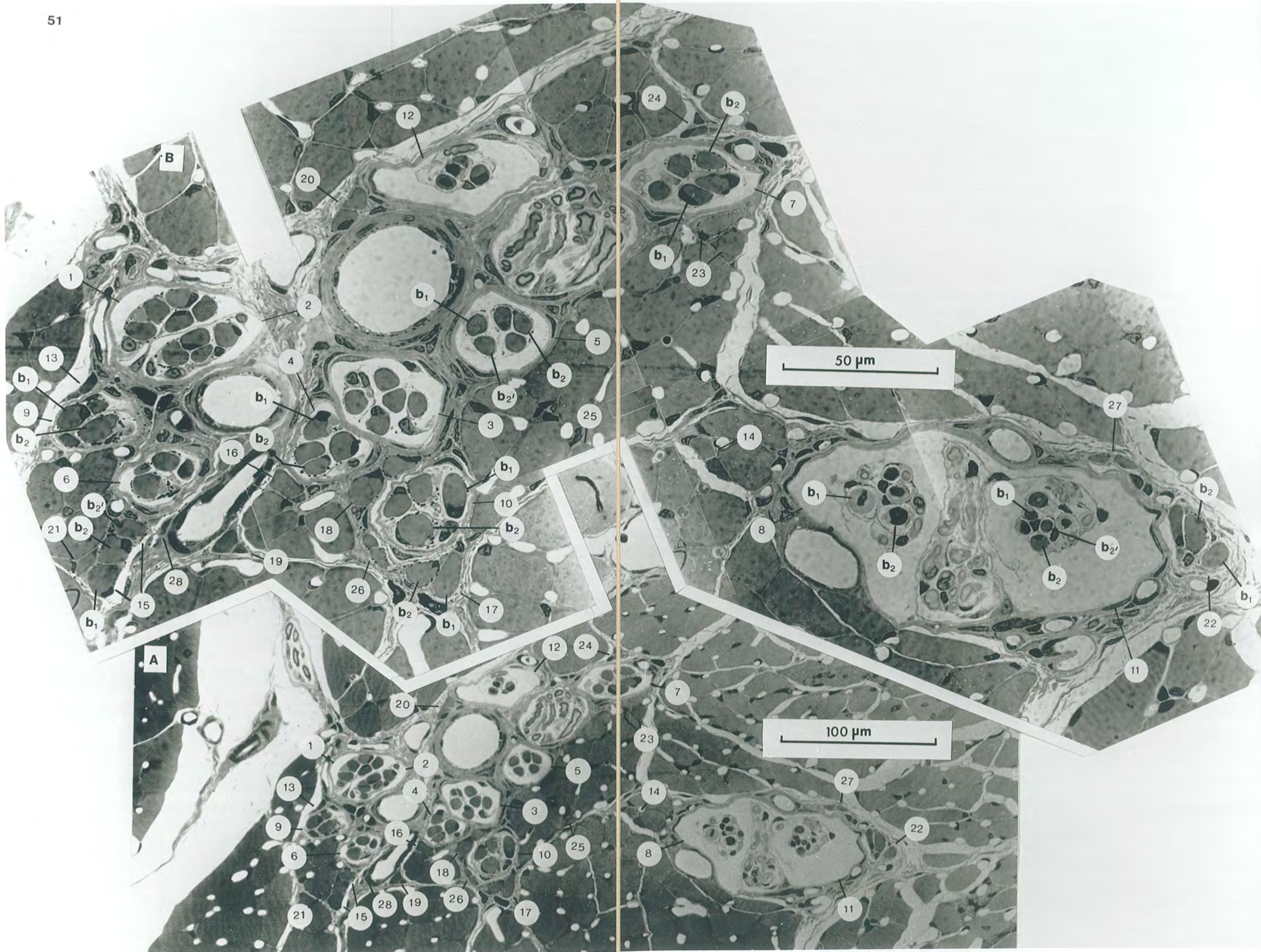




**Figure 51.** (A) A repeat of figure 46a with (B) an enlargement to show more clearly features of the muscle spindles. This section contained 28 spindles; 13 of them cut through regions A and B and the others cut through region C. Note that elastic fibres (black dots) are more abundantly associated with  $b_2$  fibres than with  $b_1$  fibres in regions B and C. Some elastic fibres associated with chain fibres are visible (see spindles no. 4, 7, 9 and 10).

**Abbreviations:**

- $b_1$  : bag<sub>1</sub> fibre
- $b_2, b_2.$  : bag<sub>2</sub> fibre
- C : chain fibre



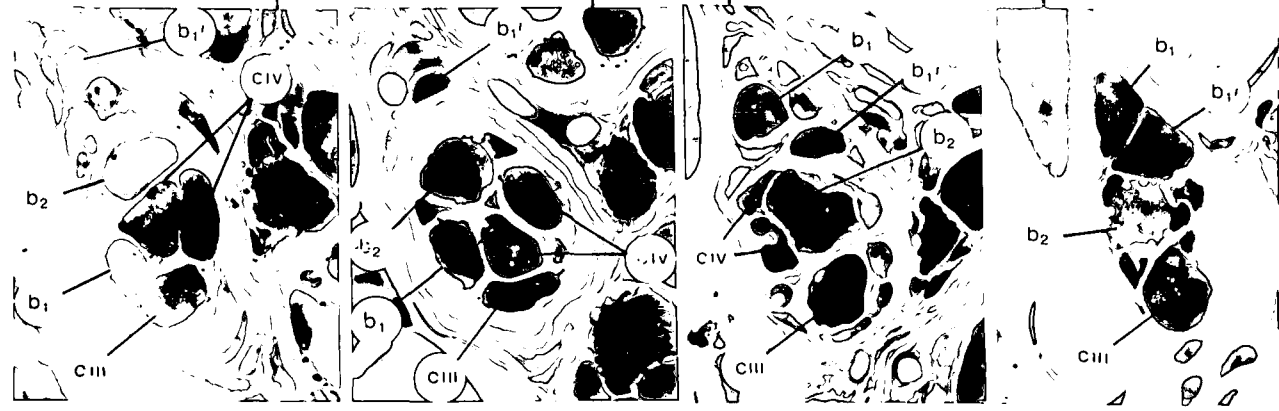
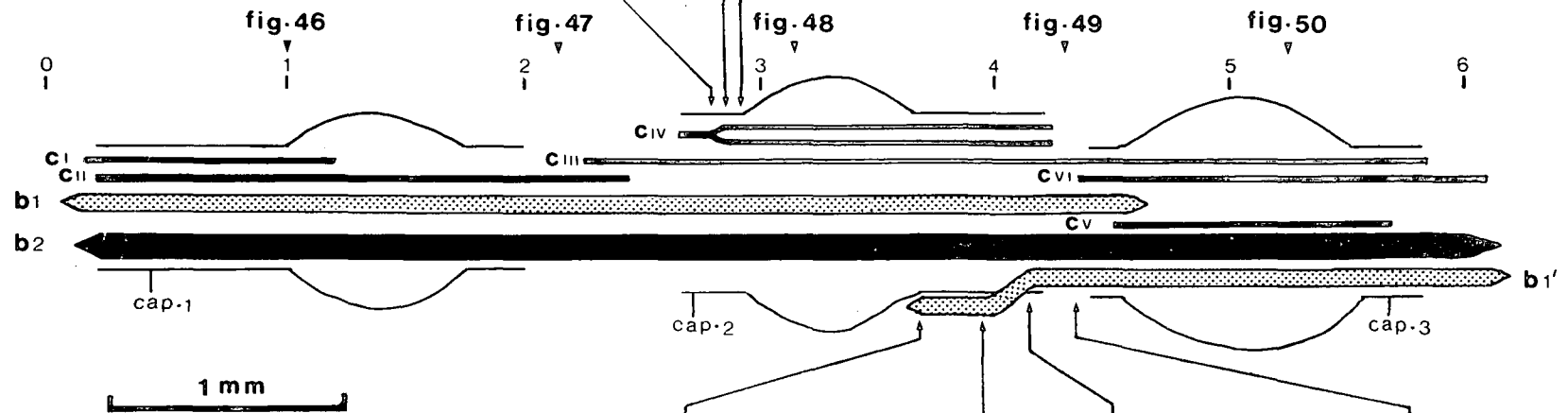
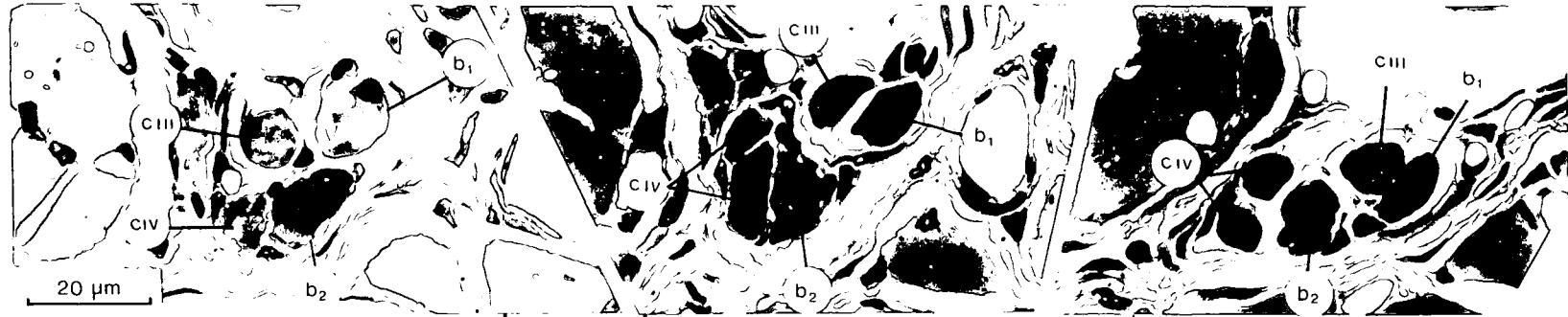
**Figure 52.** Diagram of the tandem spindle (number 6) from the anterior spindle-cluster of a rat deep masseter muscle reconstructed in figure 45. The spindle consisted of three unconnected capsules (curved light lines) sharing one common bag<sub>2</sub> fibre (thick line); bag<sub>1</sub> fibres are shown as shaded medium lines; chain fibres as thin lines.

Note the distal end of bag<sub>1</sub> fibre passed through the proximal polar region of capsule 2 and came out from its wall. Also note chain IV fibre branched into two.

Photographs are toluidine blue-stained (1 μm thick) transverse plastic sections of this tandem spindle at the levels indicated by the arrows to show the transitional zones in the spindle.

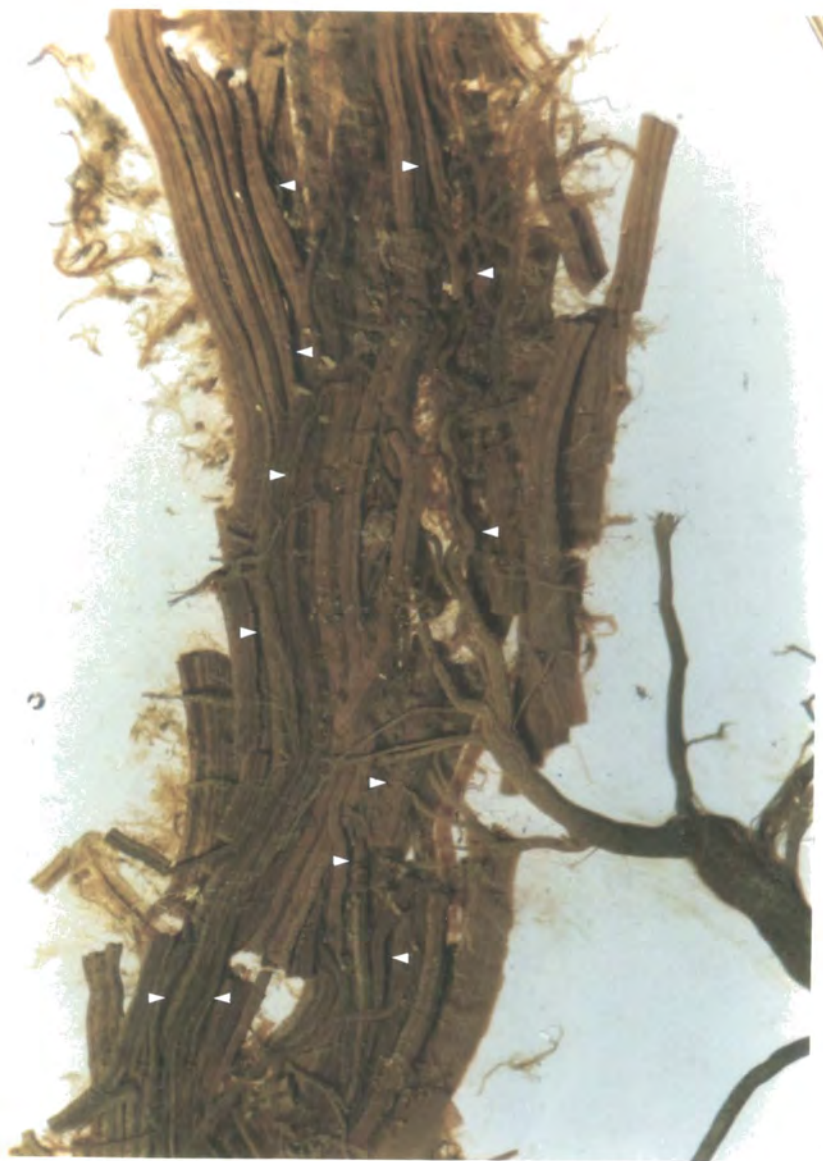**Abbreviations:**

b<sub>1</sub>, b<sub>1</sub>. ; bag<sub>1</sub> fibres, b<sub>2</sub>; bag<sub>2</sub> fibre, C; chain fibre, cap; capsule.



**Figure 53.** The anterior spindle-cluster (arrows) among a bundle of extrafusal muscle fibres of rat deep masseter. Note the large branch of the masseteric nerve feeding the spindles.





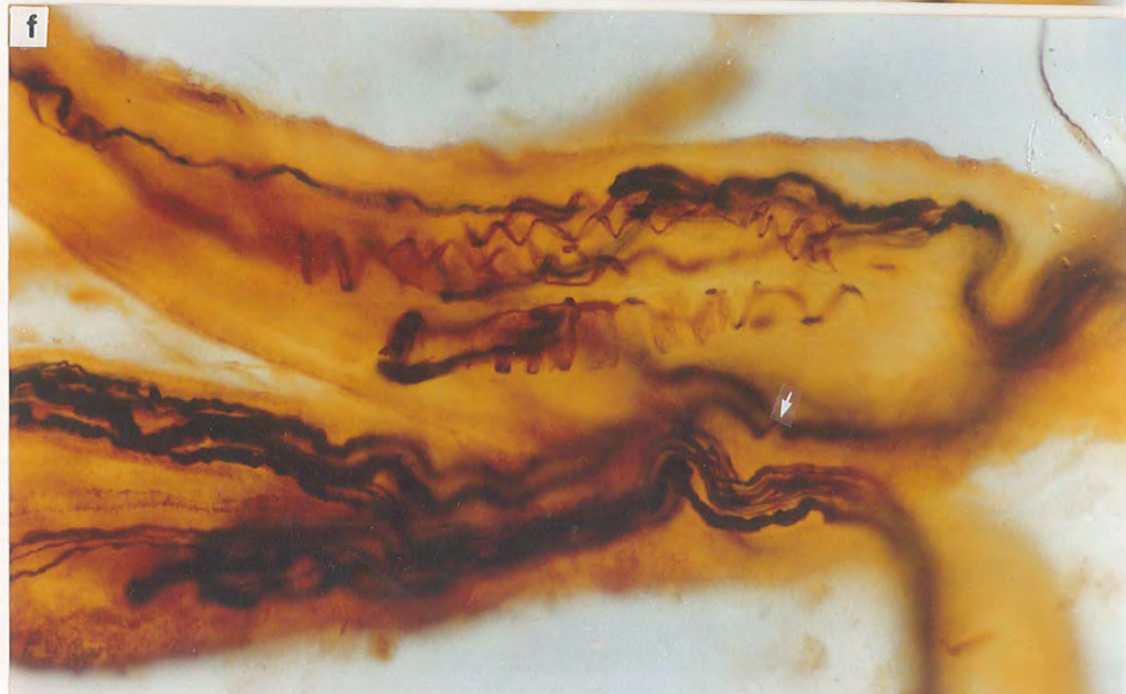
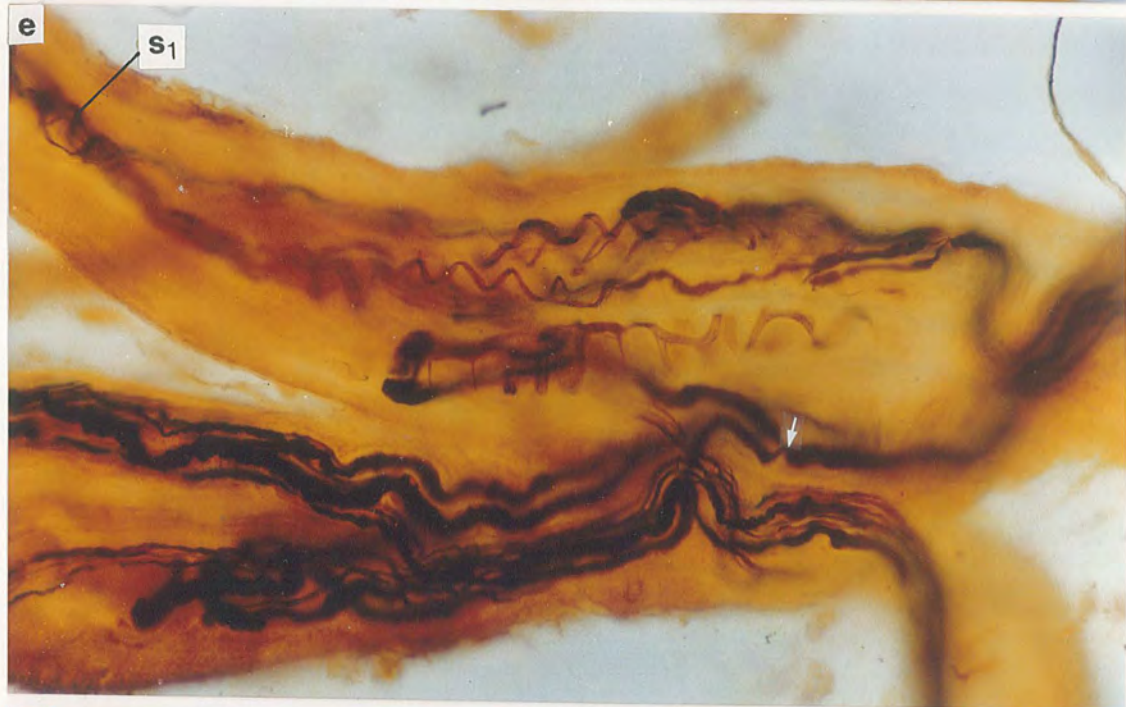
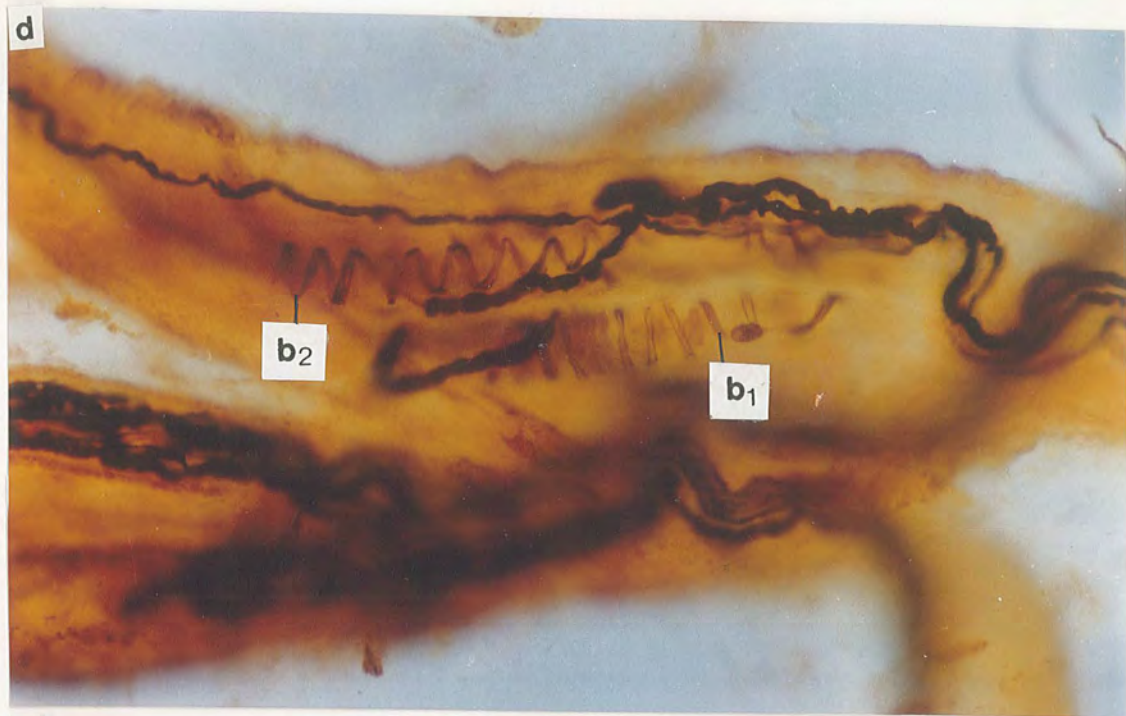
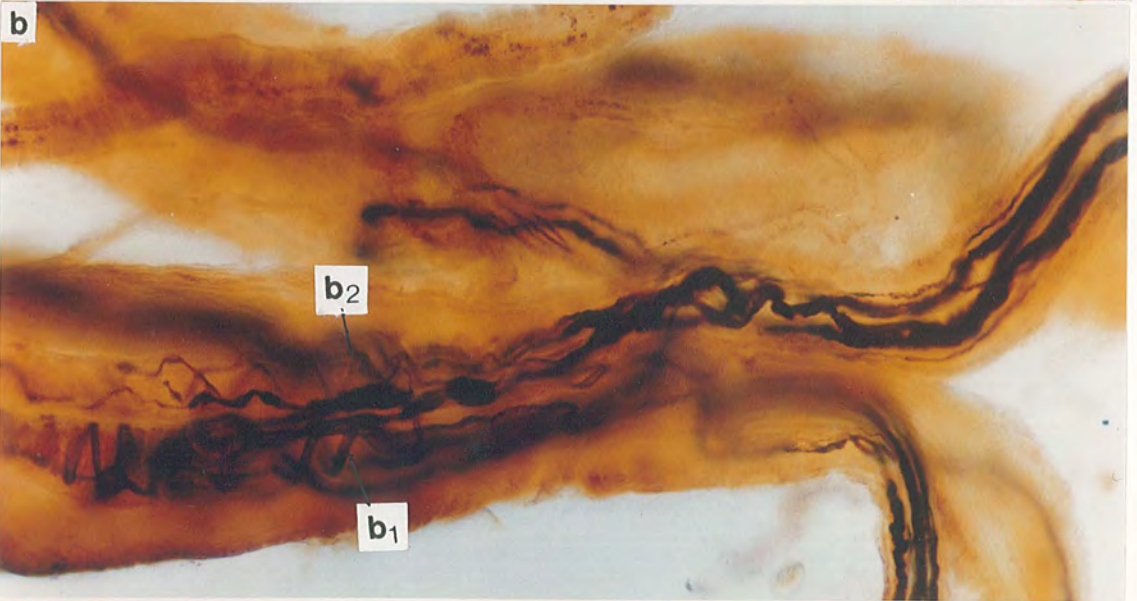
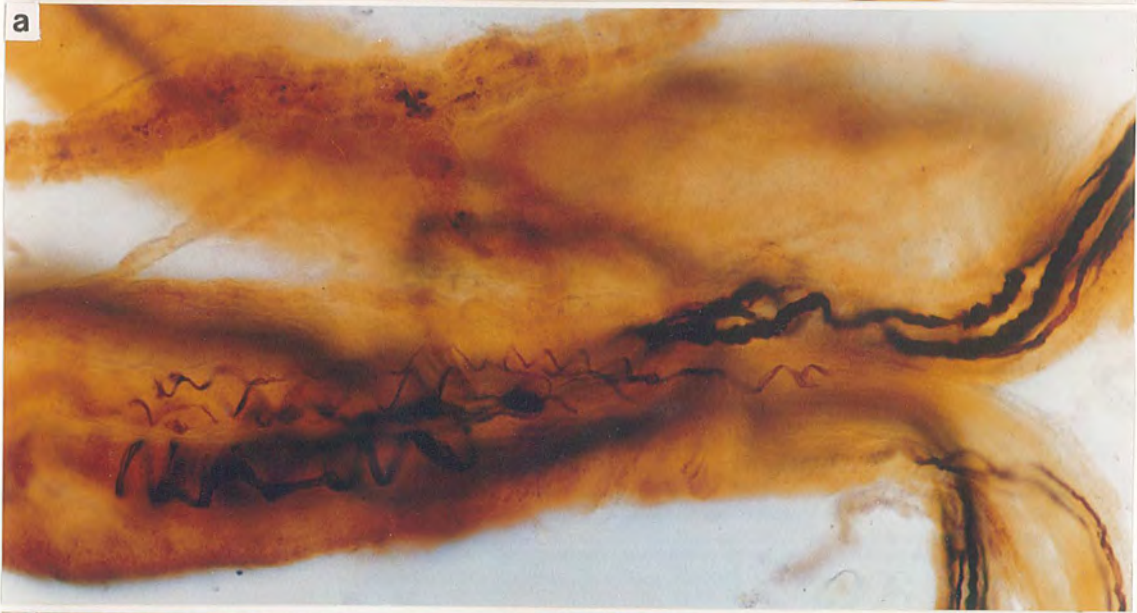**Figure 54.** Two closely adjacent spindles teased from the anterior spindle-cluster of a rat deep masseter muscle each with a double primary ending. The bag<sub>1</sub> of each spindle is innervated by a branch of a common axon (white arrow indicates the site of branching). The sensory innervation of the upper spindle was  $\overline{S_1 P P S_1}$  and of the lower one was P P.

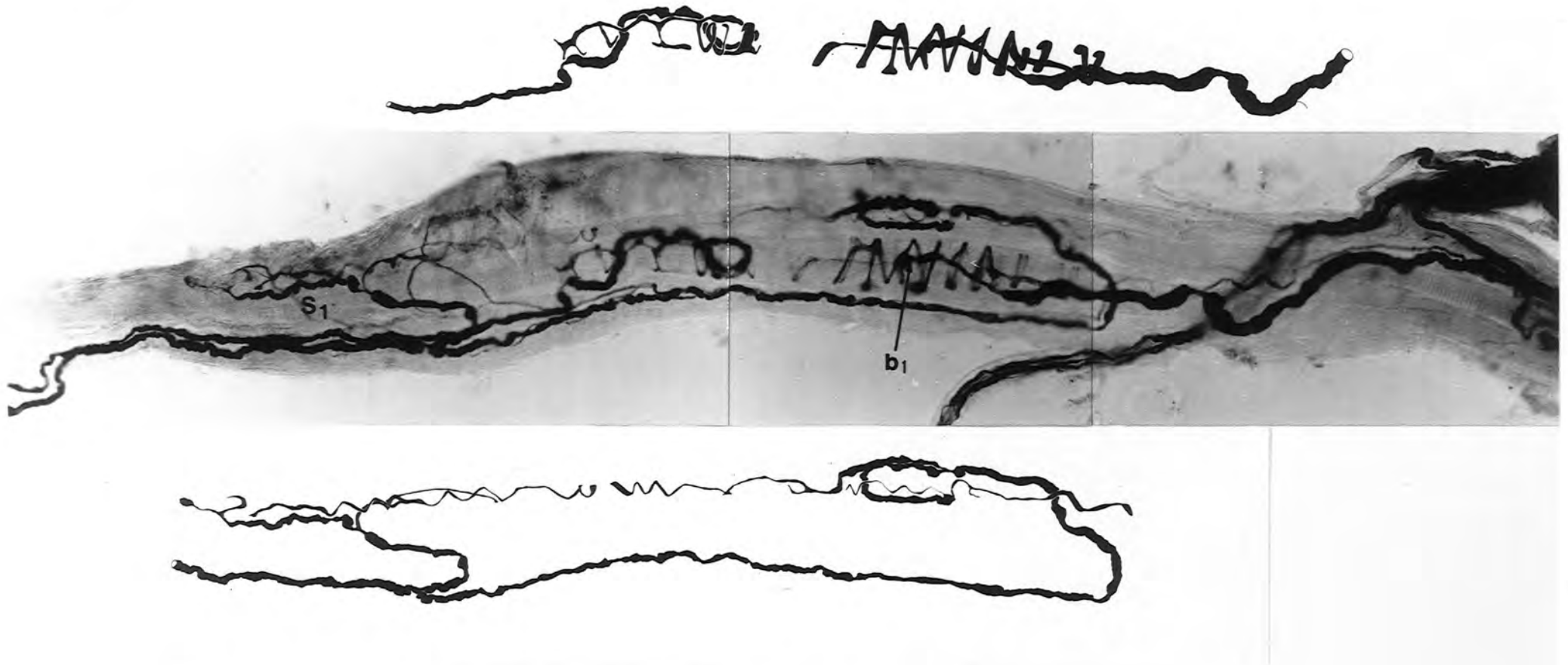
Figures a-f higher power at different focal planes to illustrate primary terminal systems supplied to each intrafusal muscle fibre.

**Abbreviations:**

- b<sub>1</sub> : bag<sub>1</sub> fibre
- b<sub>2</sub> : bag<sub>2</sub> fibre
- C : chain fibre
- S : secondary endings

54

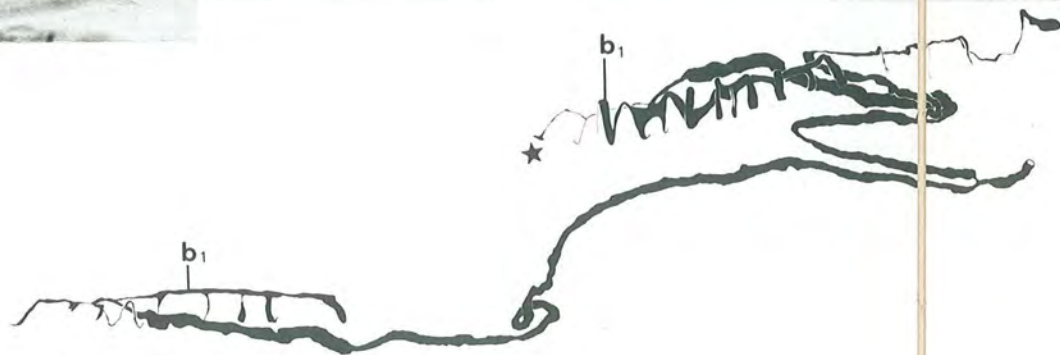
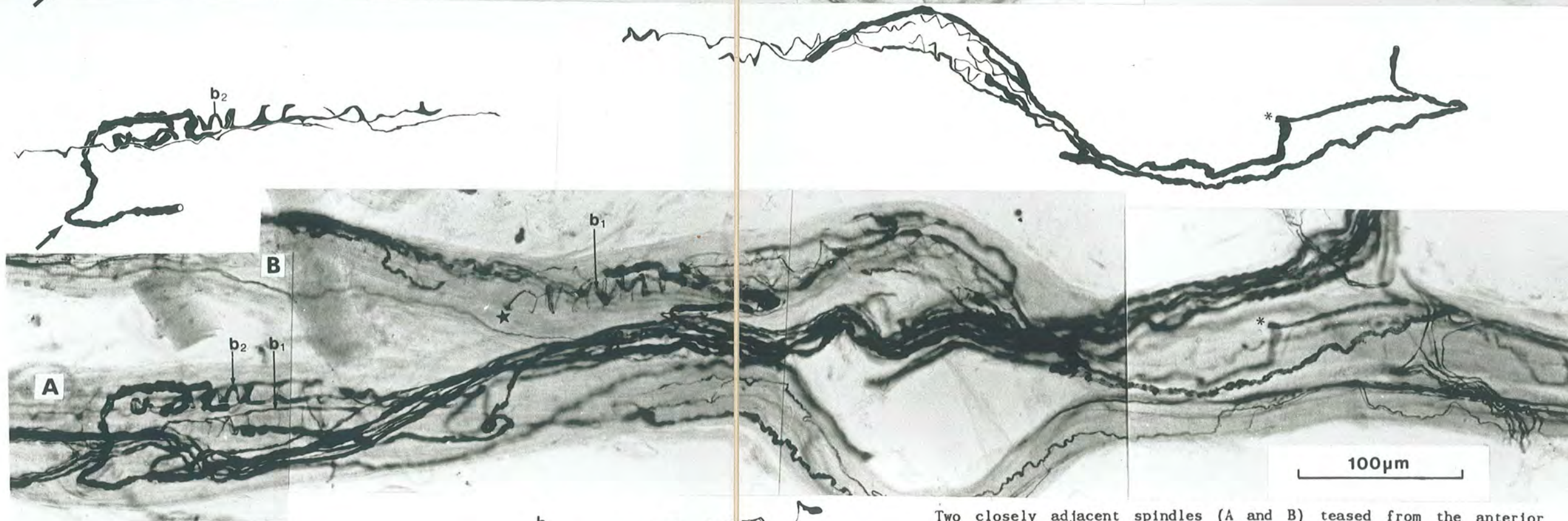
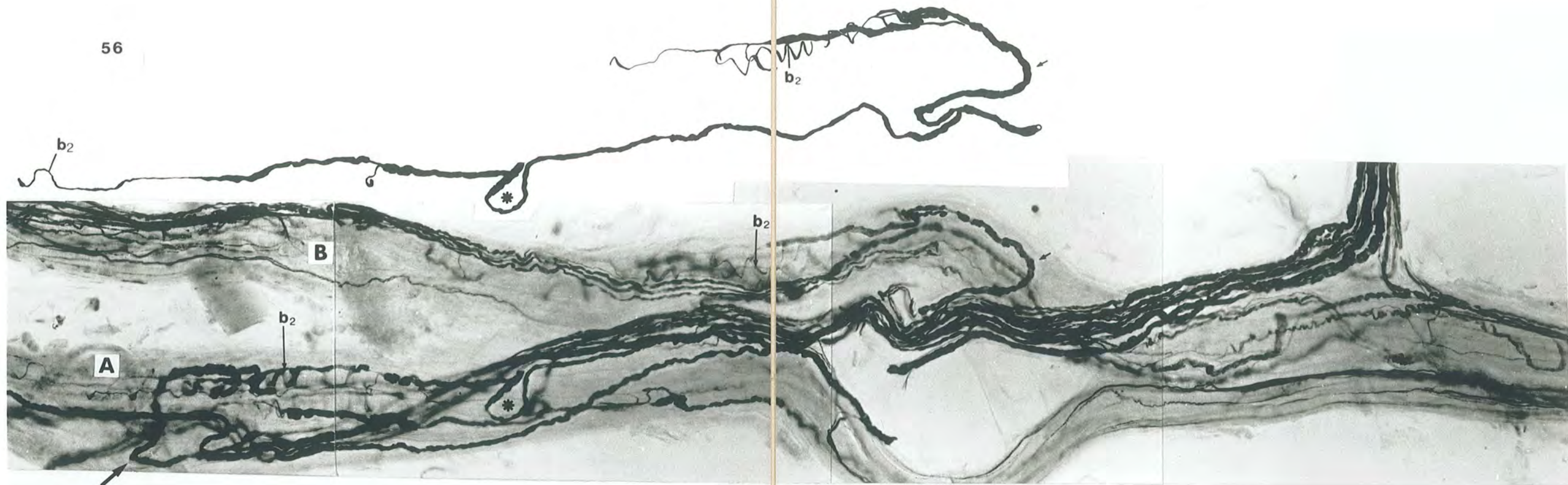




100 μm

In this teased spindle from the anterior cluster the primary region was innervated by three axons, shown separately above and below the micrograph, one of which (lower drawing) also supplied the adjacent (S<sub>1</sub>) secondary region.

**Figure 56.** Two closely adjacent spindles (A and B) teased from the anterior cluster of a rat deep masseter exhibit multiple innervation of each primary region as well as shared innervation of both. One axon, shown isolated in the lowermost drawing, supplied the bag<sub>1</sub> (b<sub>1</sub>) fibre in each spindle. The bag<sub>2</sub> (b<sub>2</sub>) and chain (c) fibres of spindle A were together supplied by a second axon (middle drawing, left), whereas in spindle B two further axons separately innervated the chain fibres (middle drawing, right) and the bag<sub>2</sub> fibre (uppermost drawing). This last axon also had a branch that supplied a small terminal to the bag<sub>2</sub> fibre of spindle A. Corresponding features in the drawings and micrographs are marked by pairs of symbols.



Two closely adjacent spindles (A and B) teased from the anterior cluster of a rat deep masseter exhibit multiple innervation of each primary region as well as shared innervation of both. One axon, shown isolated in the lowermost drawing, supplied the bag<sub>1</sub> (b<sub>1</sub>) fibre in each spindle. The bag<sub>2</sub> (b<sub>2</sub>) and chain (c) fibres of spindle A were together supplied by a second axon (middle drawing, left), whereas in spindle B two further axons separately innervated the chain fibres (middle drawing, right) and the bag<sub>2</sub> fibre (uppermost drawing). This last axon also had a branch that supplied a small terminal to the bag<sub>2</sub> fibre of spindle A. Corresponding features in the drawings and micrographs are marked by pairs of symbols.

## Plate 10

Photographs of teased silver preparations illustrating features of primary (P) and secondary ( $S_1$ ) endings innervating spindles in rat peroneus longus muscle. Abbreviations as in figure 54.

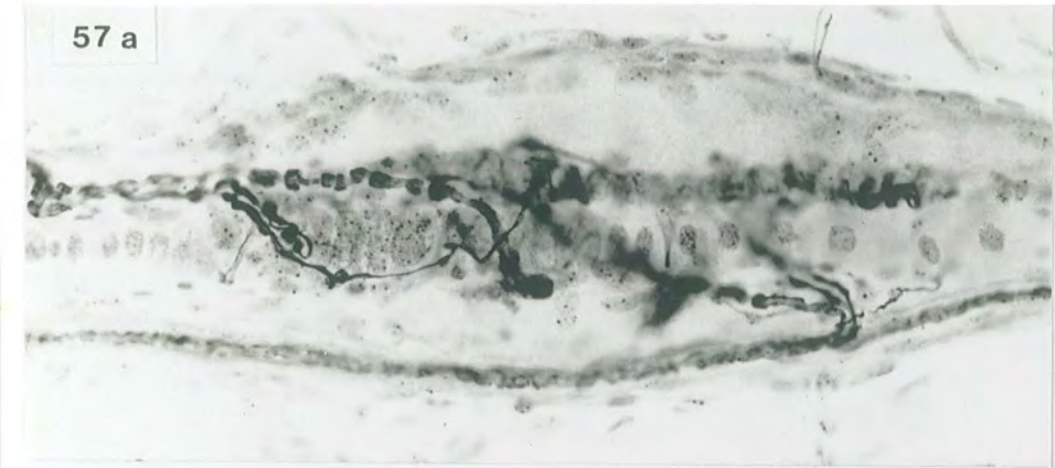
Figures 57a, b and c. Photographs at different focal planes to illustrate a primary ending innervated by two Ia axons. The equatorial nucleation of the intrafusal muscle fibres is visible. The terminal systems supplied to bag<sub>2</sub> fibres and to chain fibres are annulospiral.

Figure 58. A double primary ending supplied by two Ia axons.

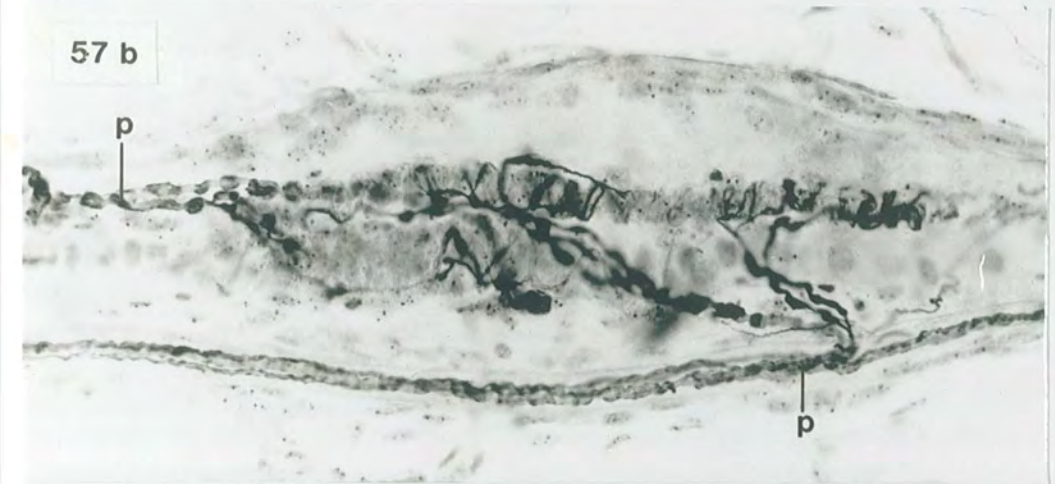Figures 59a, b and c. Photographs taken at different focal planes show a primary ending supplied by two Ia axons and a  $S_1$  ending supplied by a II axon. Note the long spirals on the chain fibres.

Figures 60a and b. Photographs at two different focal planes show the nucleation of the intrafusal muscle fibres and the primary terminal systems supplied to bag<sub>2</sub>, bag<sub>1</sub> and chain fibres. Figure 60a shows one  $S_1$  secondary ending (right) supplied to the three types of intrafusal muscle fibre.

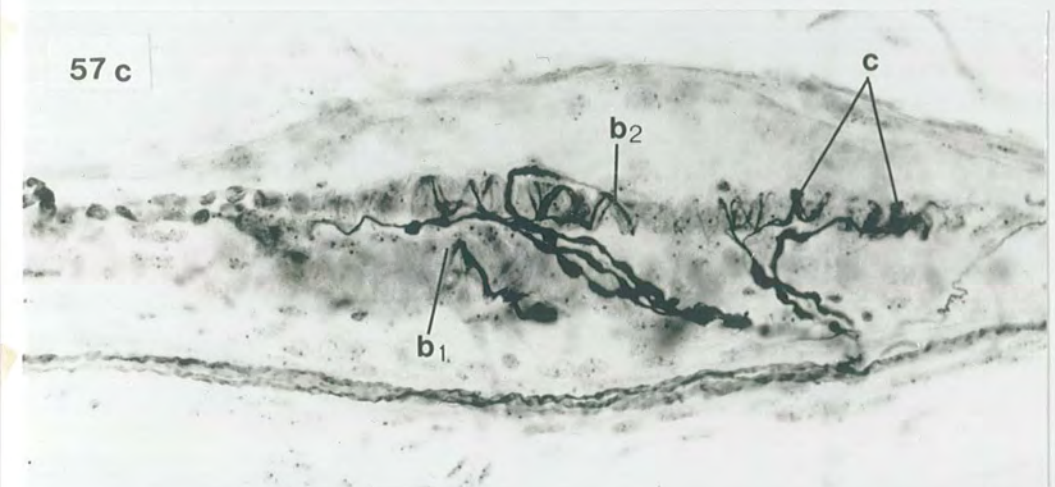
57 a



57 b

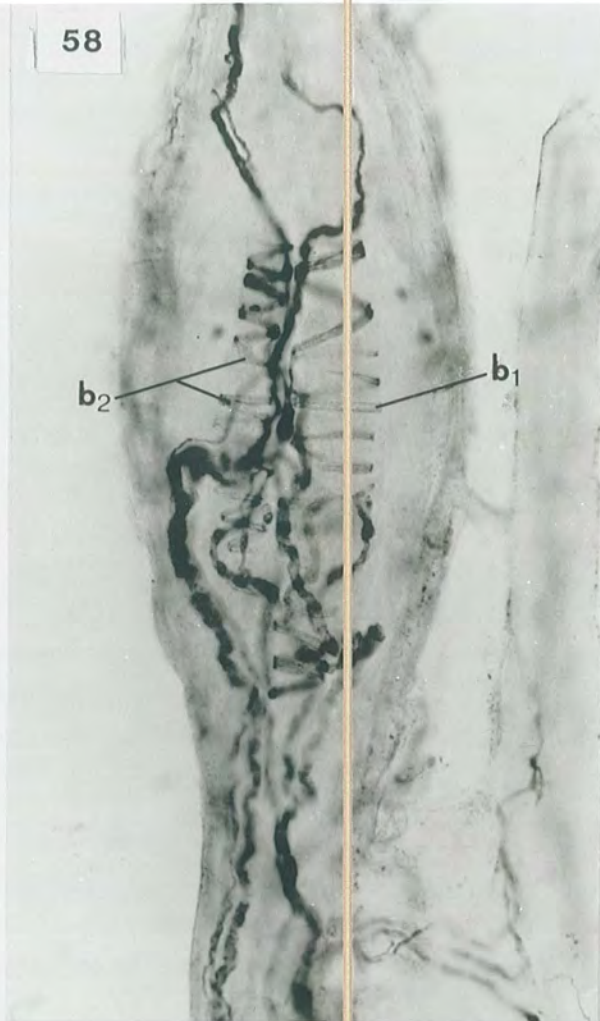


57 c

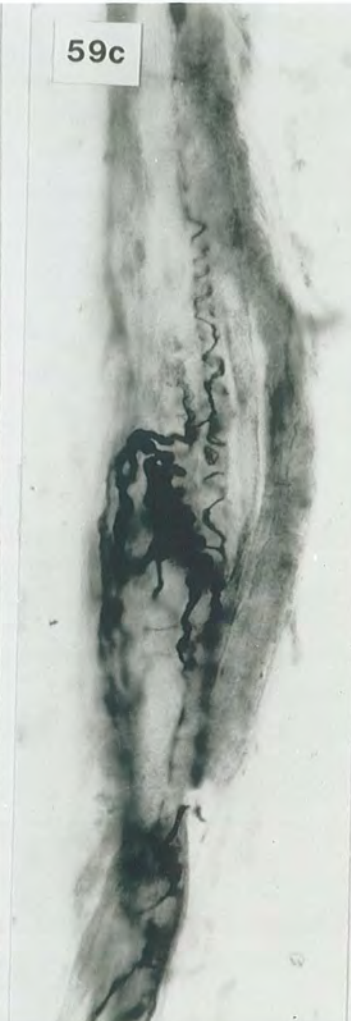

100 μm

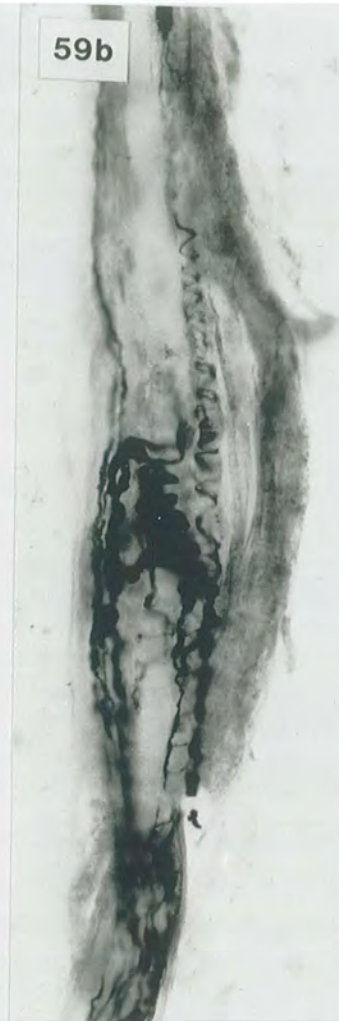58



59c



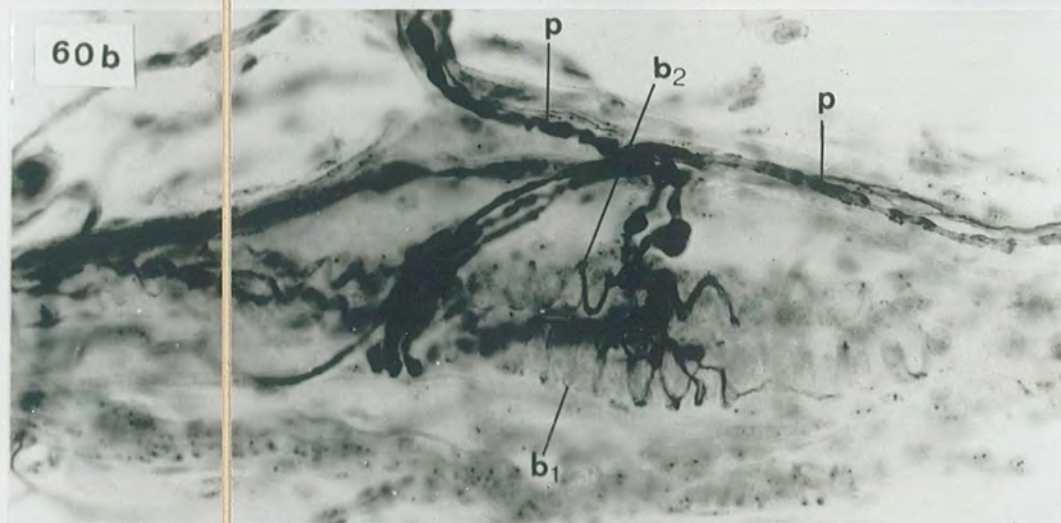
59b



59 a



60b



60a

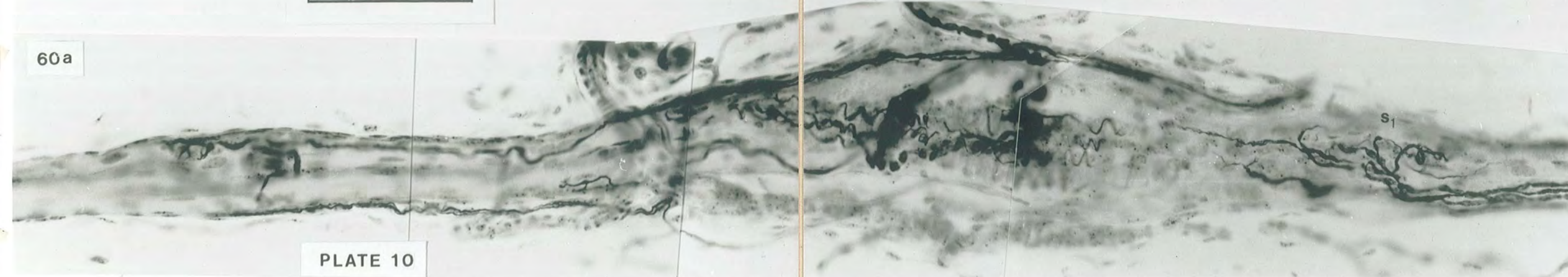


PLATE 10



## Plate 11

Photographs of teased silver preparation illustrating features of primary and secondary innervation of rat muscle spindle in masseter, soleus and lumbrical muscles, and equatorial nucleation of bag<sub>1</sub> and bag<sub>2</sub>. Figures 61, 62 and 64 were taken at two different focal planes. Abbreviations as in figure 54.

Figure 61a and b. Show the primary ending of a spindle in deep masseter supplied by a Ia axon. The primary terminal systems of the three types of intrafusal muscle fibre are quite clear. A II axon divided at the point arrowed to produce two branches that supplied S<sub>1</sub> secondary terminals to chain fibres on each side of the primary.

Figure 62a and b. Soleus spindle showing the equatorial nucleation of bag<sub>2</sub> fibre and spiral ending on bag<sub>1</sub> fibre. An II axon supplies an S<sub>1</sub> secondary ending (right) to chain fibre.

Figure 63. A lumbrical spindle innervated by three sensory axons, one each to the primary and an S<sub>1</sub> secondary and one to an S<sub>2</sub> secondary ( $\overline{S_1} \overline{P} \overline{P} \overline{S_1} S_2$ ). The axon on the left supplied a primary ending to b<sub>2</sub>C and an S<sub>1</sub> secondary ending to chain fibres, whereas that in the middle supplied a primary ending to b<sub>1</sub> and an S<sub>1</sub> secondary ending to chain fibres. The third is a II axon that supplied a S<sub>2</sub> ending to chain fibres.

Figure 64a and b. A lumbrical spindle containing primary endings supplied by two Ia axons, one to bag<sub>1</sub>, the other to bag<sub>2</sub> and chain fibres.

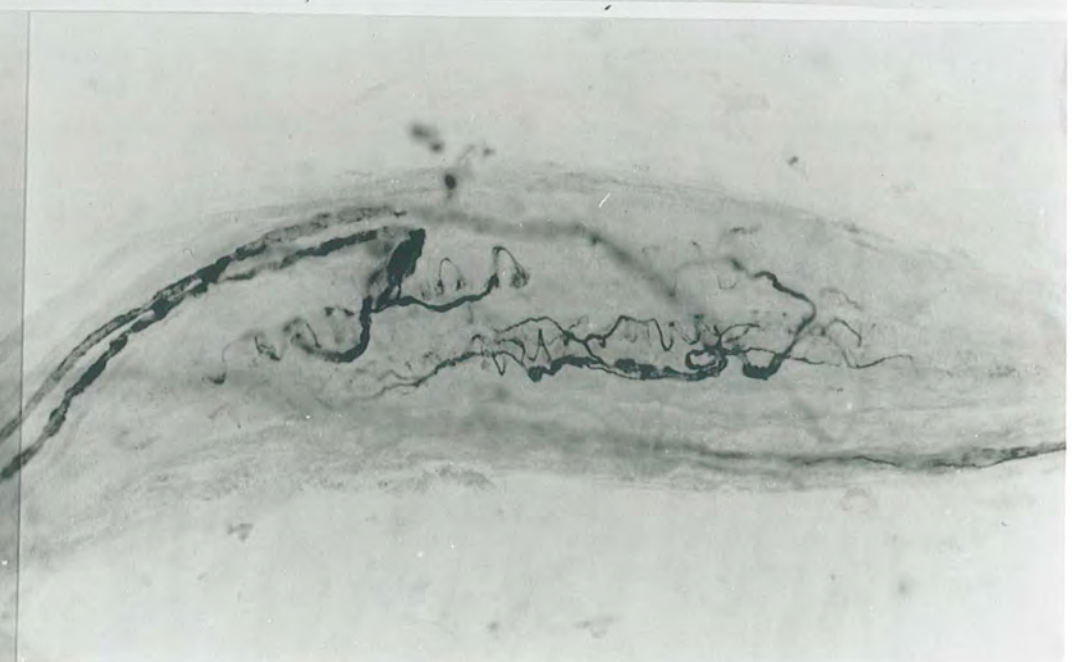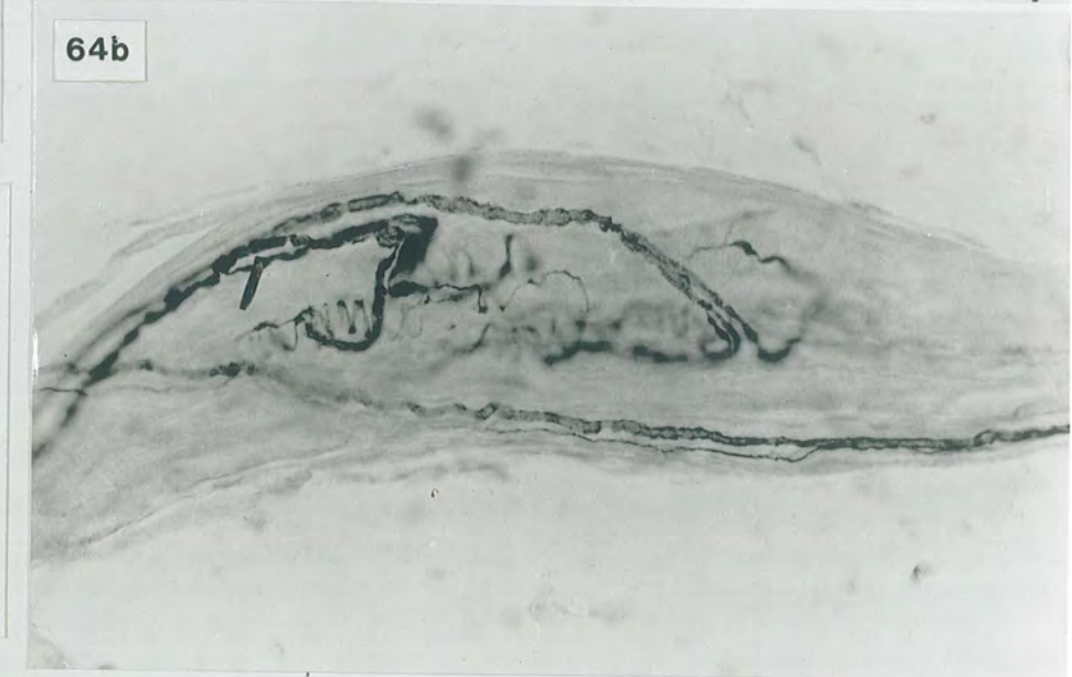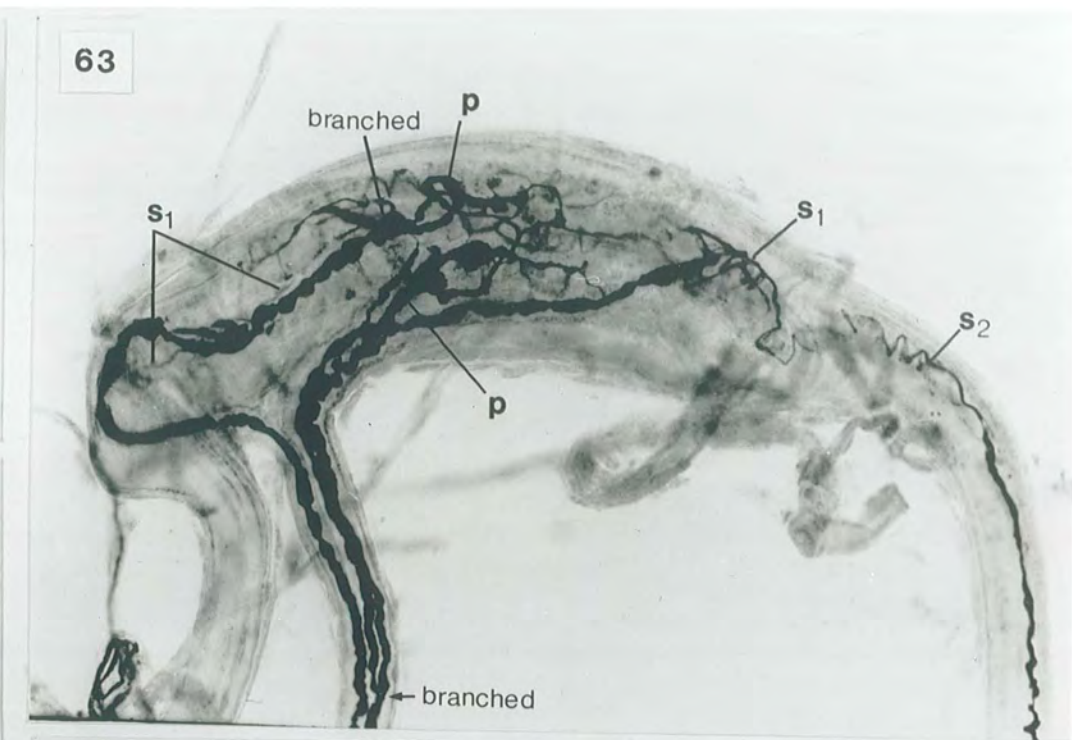
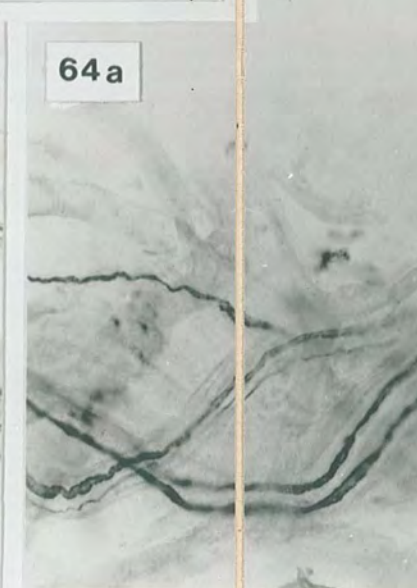
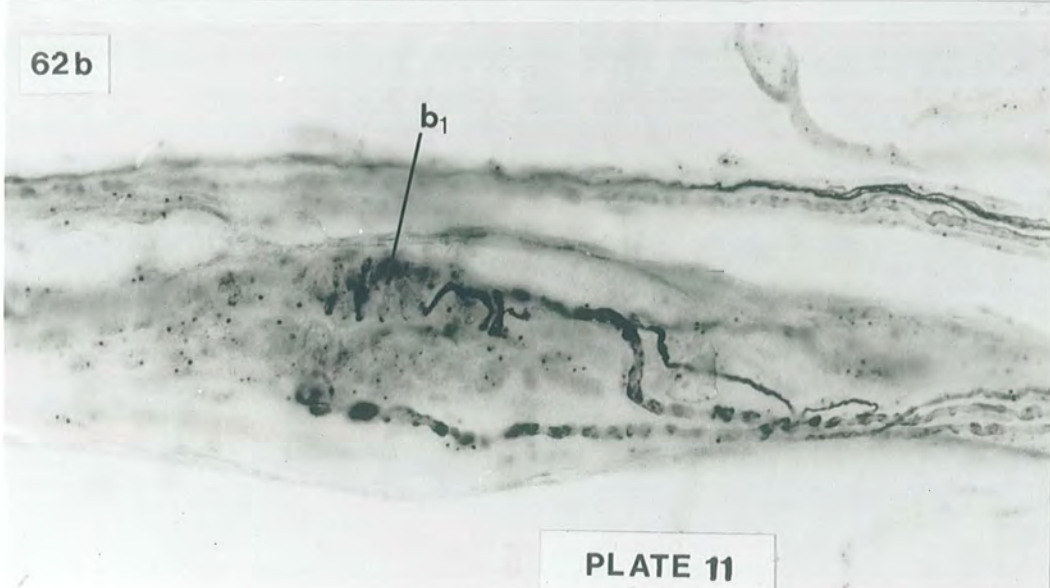
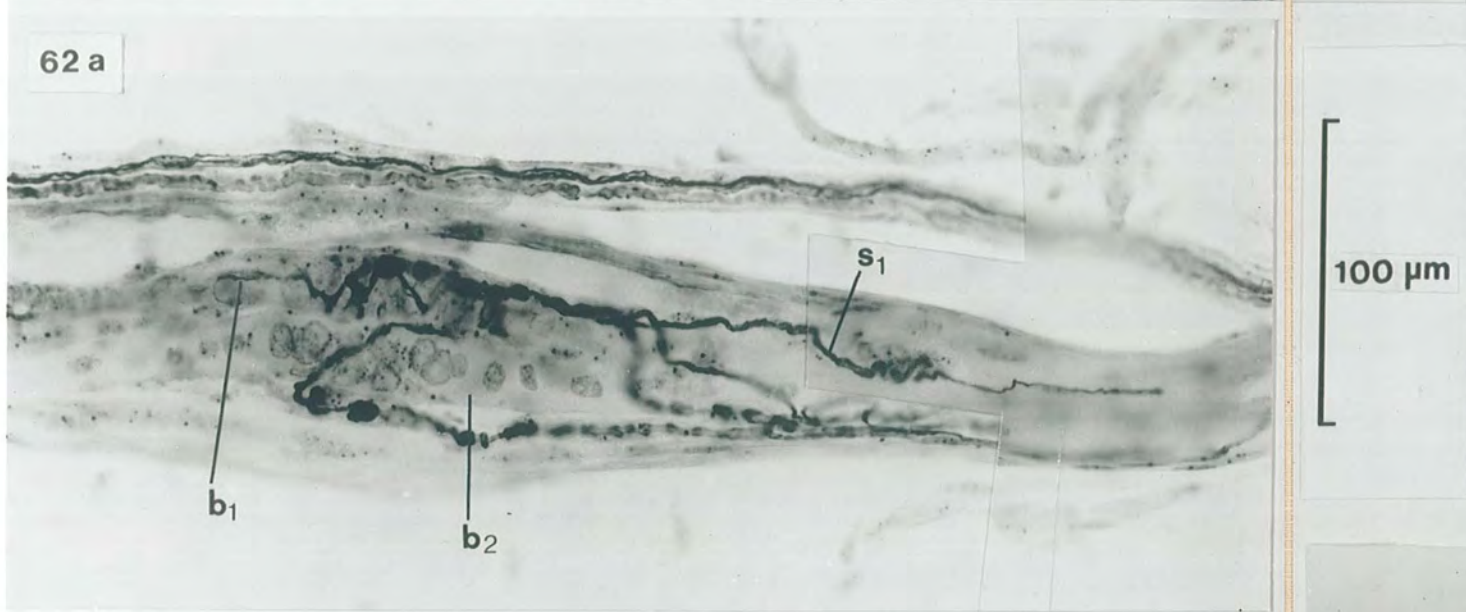
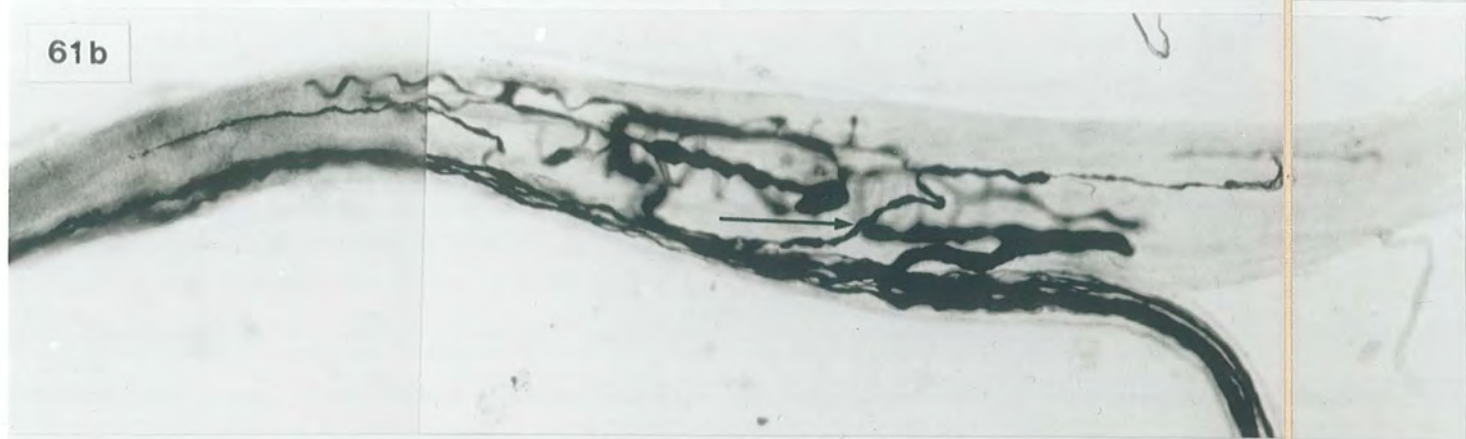
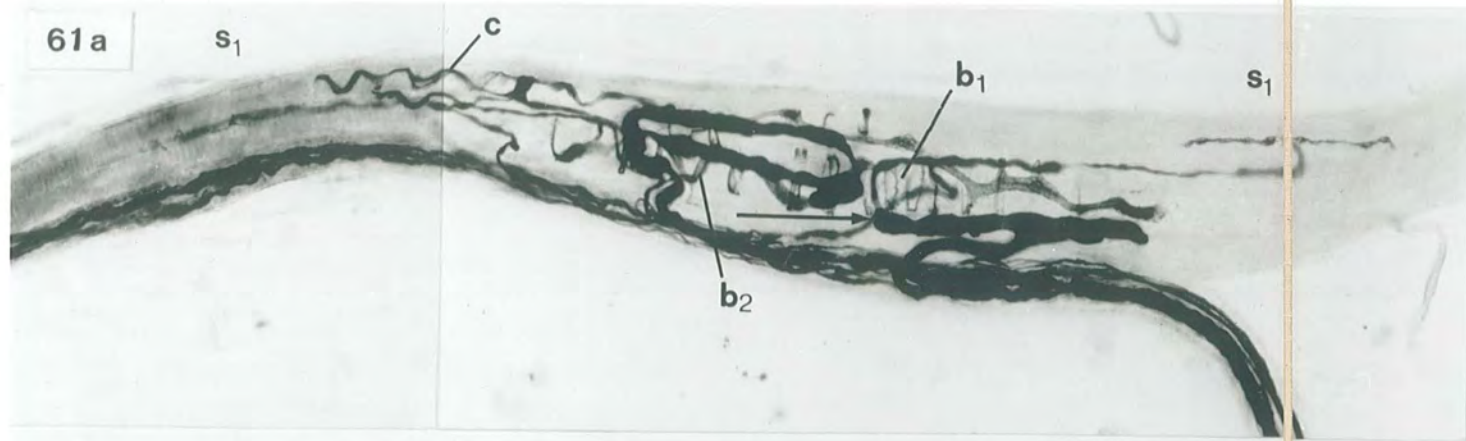
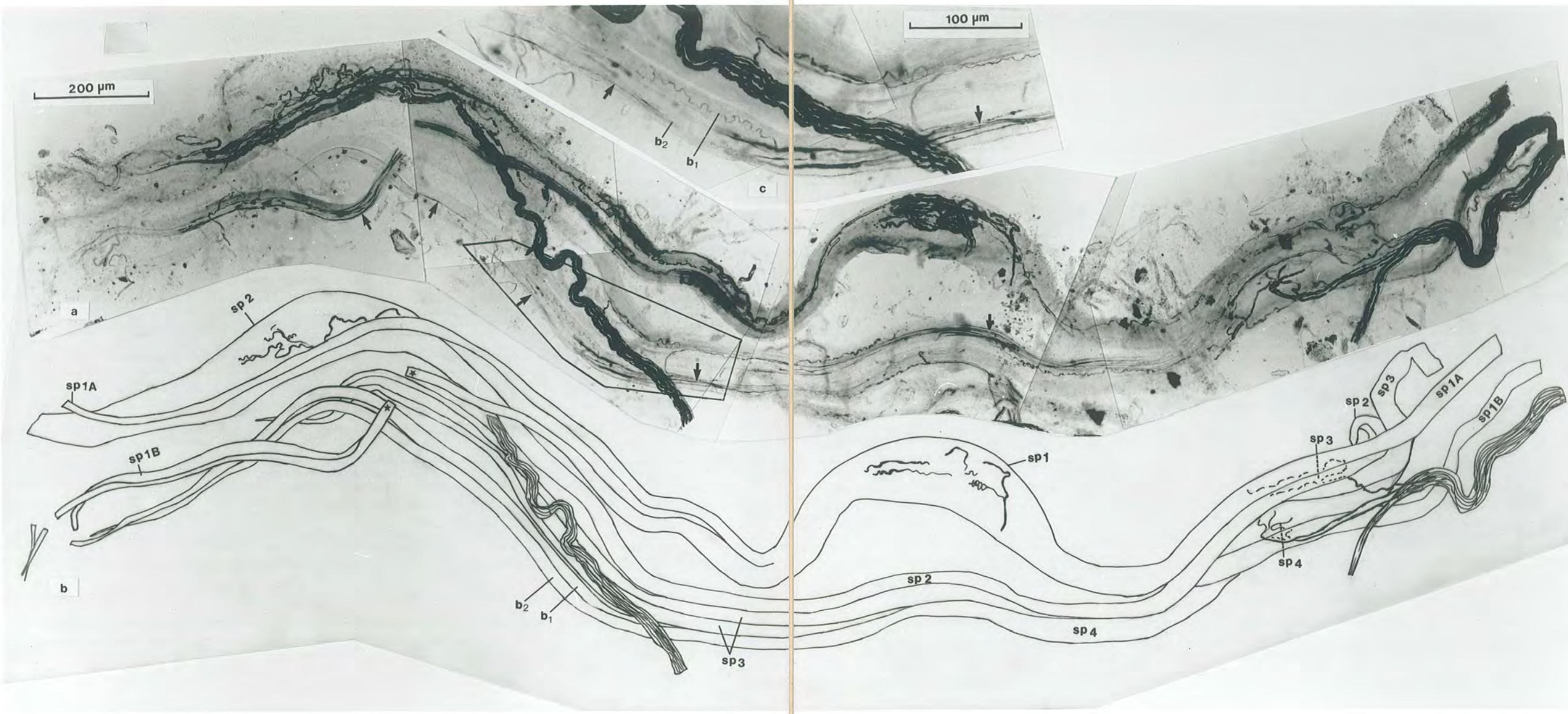
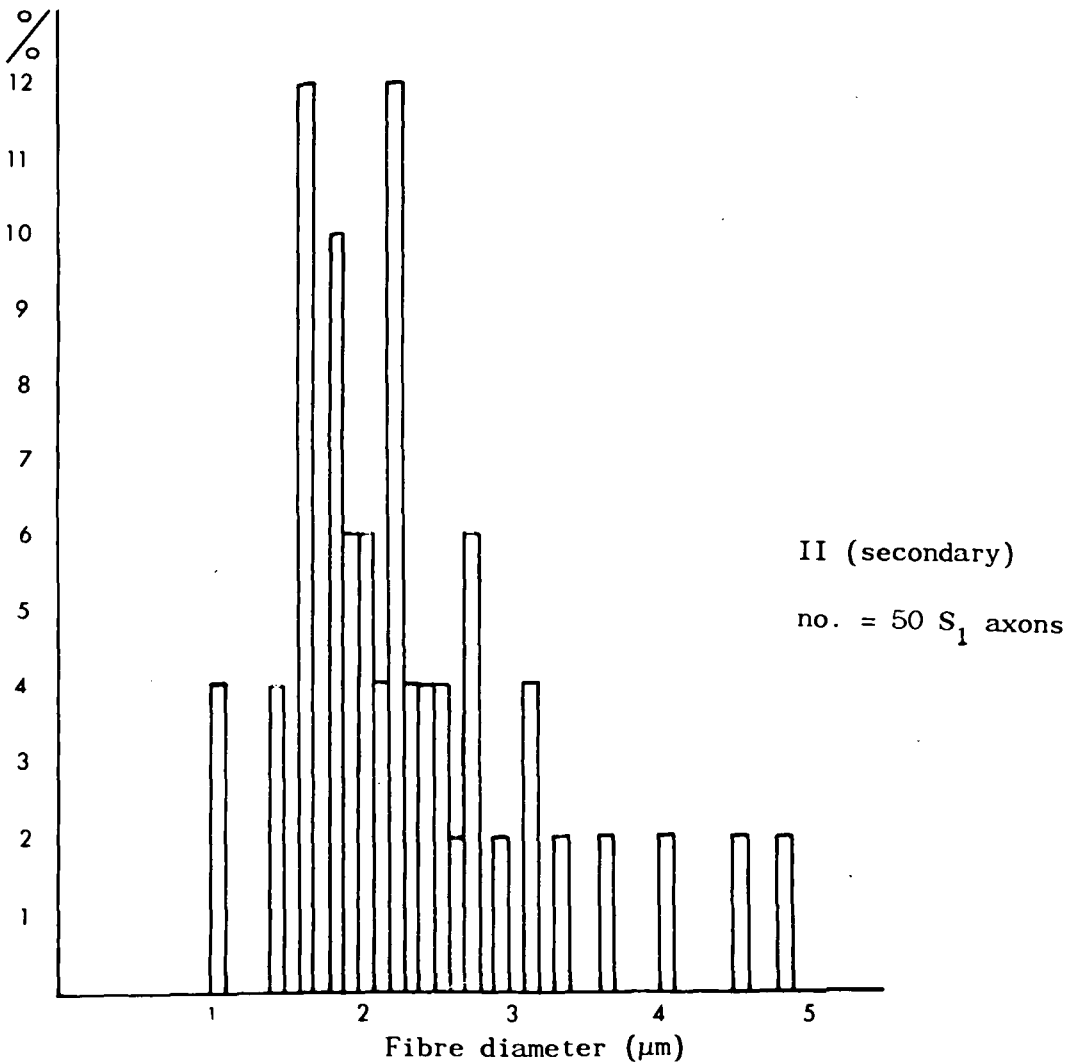
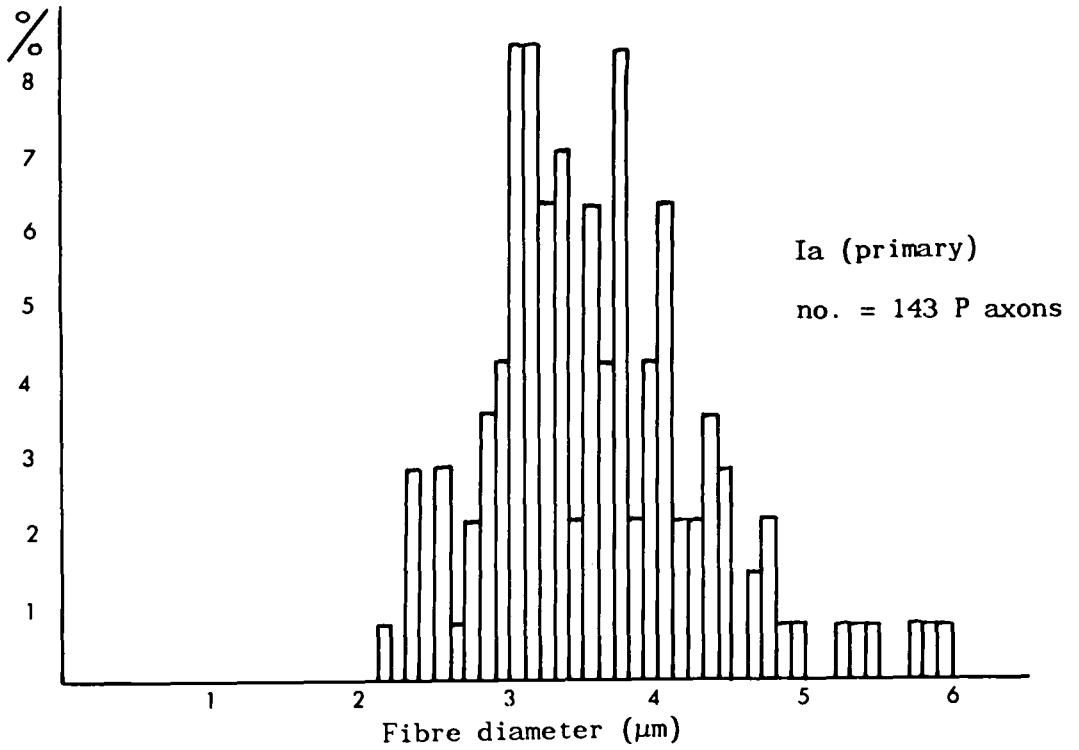


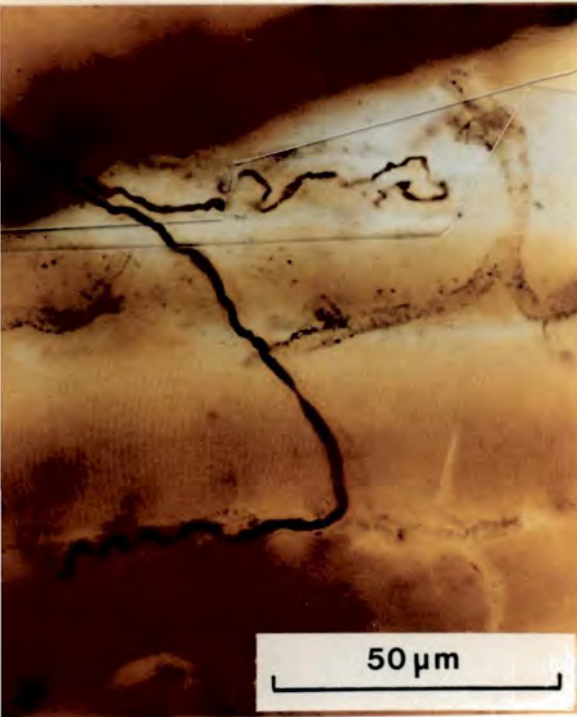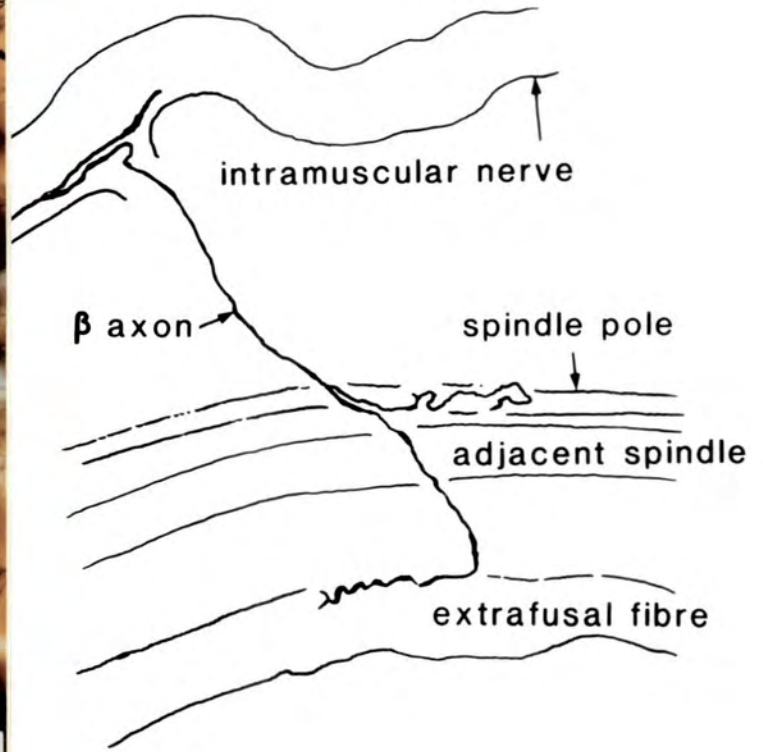
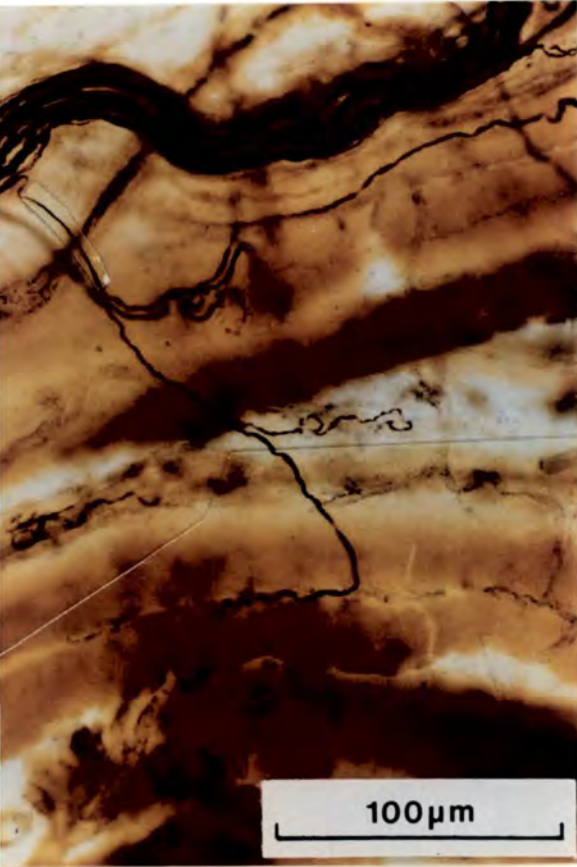
Figure 65a. A photo-montage of a group of four spindles in deep masseter muscle of a rat, silver preparation. Spindle 1 contained two intrafusal bundles in a single equatorial capsule. Elastic fibres appear as black lines (arrows) running parallel to and surrounding the intrafusal muscle fibres in regions B and C. They are more abundantly associated with bag<sub>2</sub> than with bag<sub>1</sub>, see inset C at higher power.

Figure 65b. Diagram to illustrate the boundary of each spindle. The two parts of the broken pole of spindle 1B are asterisked.

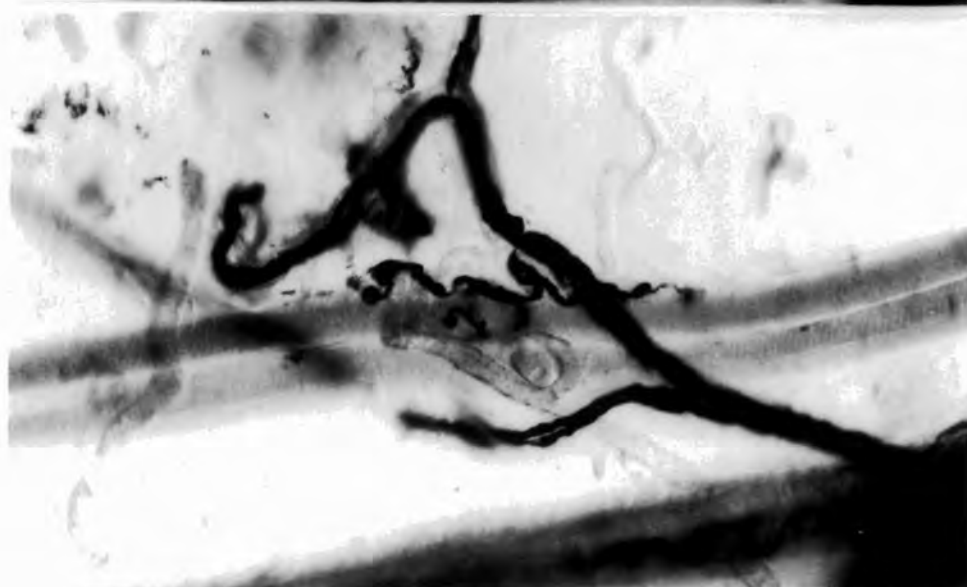
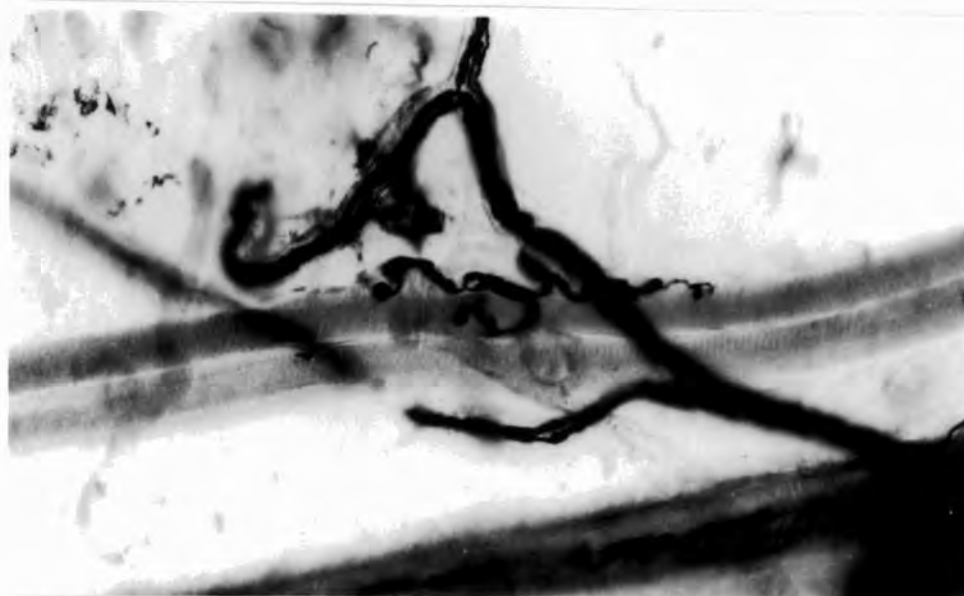


**Figure 66.** Diameter of nerve fibres that supplied primary (top) and secondary (bottom) endings in rat deep masseter muscle spindles measured as far as possible away from the endings but at least 300  $\mu\text{m}$  from the first branching node.





Photomontages of a  $\beta$  axon in which the common origin of intrafusal and extrafusal branches is clearly visible.



The intrafusal distribution of the  $\beta$  axons was confined to the polar regions of  $bag_1$  fibres, which were identified by their length, diameter and lack of elastic fibres. In this example, shown at two focal planes, a  $\beta$  axon supplied three small endplates closely spaced on the  $bag_1$  fibre.



### C. Discussion

#### 1. Types of intrafusal muscle fibre

Several authors have described two morphological types of intrafusal fibre in the rat, as in other mammals, known as bag and chain fibres: Barker and Hunt (1964); Merrillees (1960); Karlsen (1965); Landon (1966a); Porayko and Smith (1968); Bridgman, Shumpert and Eldred (1969); Rakhawy *et al.* (1971) and Ovalle (1971). This classification was later extended to three types of fibre, now named bag<sub>1</sub>, bag<sub>2</sub> and chain fibres: Ovalle (1972a), Milburn (1973a & b), Soukup (1976); Banks *et al.* (1977); Lennartsson (1980b) and Walro and Kucera (1985a). There are generally four intrafusal fibres in each spindle of adult rat: one bag<sub>1</sub>, one bag<sub>2</sub> and two chain fibres.

Based on the following morphological criteria the three types of intrafusal muscle fibre may be recognized. In transverse section bag fibres appear larger than chain fibres in the juxtaequatorial region, and contain more nuclei in the equatorial region, whereas chain fibres possess only one nucleus. Chain fibres are shorter than bag fibres and usually end at the limits of the capsule, whereas bag fibres extend beyond it (Boyd, 1962c). The bag<sub>2</sub> fibre can be distinguished from the bag<sub>1</sub> fibre by the relative abundance of elastic fibres associated with its extracapsular polar region (Gladden, 1976; Walro and Kucera, 1985 a & b), by its greater diameter in the juxtaequatorial region, and by the presence of more nuclei in the transverse sections of the equatorial region (Soukup, 1976). Also the bag<sub>1</sub> fibre is usually shorter than the bag<sub>2</sub> fibre.

In the present study, fifty-seven spindles which composed an anterior spindle-cluster in a rat deep masseter muscle were traced from end to end in serial transverse plastic sections (1  $\mu\text{m}$  thick) (Banks,

1981a; Walro and Kucera, 1985a). All spindles in this sample contained at least one bag<sub>2</sub>, one bag<sub>1</sub> and 0-5 chain fibres. Three spindles each contained 3 bag fibres, interpreted as two bag<sub>2</sub> (bag<sub>2</sub> & bag<sub>2</sub>.) and one bag<sub>1</sub> based on the results obtained with enzyme and immunohistochemistry described in Chapter V, although the additional bag<sub>2</sub> fibres (bag<sub>2</sub>.) appeared morphologically similar to bag<sub>1</sub> fibres. This finding is not peculiar to rat deep masseter muscle since Kucera *et al.* (1978) found a spindle that contained two bag<sub>2</sub> and one bag<sub>1</sub> fibre in rat soleus muscle.

In the present study the number of intrafusal muscle fibres varied from 2 to 7, which is within the limits given by the previous authors. For example Karlsen (1965) reported that most of the spindles of rat jaw muscles contained 5 to 7 fibres of which 1 to 3 were usually bag fibres, and Rakhawy *et al.* (1971) found 1 to 5 fibres in each spindle of rat lateral pterygoid muscle.

Fusion and clustering of spindles observed in rat deep masseter muscle in the present study has been noted by Maier (1979) in rat medial pterygoid and deep masseter muscles. These phenomena also occur in the deep part of cat masseter muscle (Lund *et al.*, 1978), cat and monkey (Rowlerson *et al.*, 1988) and in human masseter (Eriksson and Thornell, 1985). Thompson (1970) found that the muscles of rat tail contained parallel spindle complexes, some of which shared capsules. Similar spindle complexes have also been described in cat neck muscles by Richmond and Abrahams (1975b). The functional advantage, if any, of this arrangement is not yet known. However, these phenomena are not universal characteristics of masseter muscle since they are not found in rabbit and guinea-pig (Rowlerson *et al.*, 1988).

In this study I have not seen any extrafusal muscle fibres enclosed within fused spindles, as reported to be present in rat

masseter (Karlsen, 1965), in the small muscles of rat tail (Thompson, 1970) and in cat and monkey masseter muscles (Rowlerson *et al.*, 1988), or enclosed within a capsule of single spindle as described by Banks (1973) in hindlimb lumbrical muscles of guinea-pig. Neither have I observed any spindle containing fewer than two or more than seven intrafusal muscle fibres. Karlsen (1965) described "a giant spindle" consisting of 12 fibres in rat deep masseter muscle. In my sample I have found such spindles to be formed by the fusion of two capsules at their equatorial regions.

Although no specific stain for elastic fibres was used in the present study, the elastic fibres were easily visible surrounding the intrafusal muscle fibres in their polar regions using 1% toluidine blue (figure 51) or silver (figure 65) stains. Cooper and Gladden (1974) reported that bag fibres in human, cat and rat spindles were surrounded by elastic fibres more than were chain fibres in their polar regions. Moreover, Gladden (1976) found the elastic fibres to be associated more with bag<sub>2</sub> than with bag<sub>1</sub> fibres in their extracapsular regions. The same findings in rat spindles were confirmed by Walro and Kucera (1985a & b) in plastic transverse sections. I have found corresponding features in my sample of rat spindles. Elastic fibres were also seen around some chain fibres in region B (see figure 51). A recent claim has been reported by Arbuthnott *et al.* (1989) that the two bag fibre types in rat soleus muscle are surrounded by equal amounts of elastic fibres in their extracapsular region. In the present study I have not observed such findings.

The measurements listed in Table 15 show that there are regional differences in the diameter of each intrafusal muscle fibre for the three fibre types examined in rat deep masseter muscle. In the periaxial space region, only the bag<sub>2</sub> fibre usually appeared to have a

greater cross-sectional area than that of bag<sub>1</sub> and chain fibres. Using Student's t test it was found that the diameter of each of the three regions of bag<sub>2</sub> fibre were significantly greater than for bag<sub>1</sub> fibre, and that the diameter of chain fibres was smaller than bag<sub>1</sub> fibres. Similar findings have been reported in some rat hindlimb muscles (Soukup, 1976; Banks *et al.*, 1977), but Banks *et al.* found the diameter of bag<sub>1</sub> and bag<sub>2</sub> fibres in their equatorial regions to be larger than that in their polar regions. The number of nuclei abreast in the equatorial region of bag<sub>1</sub> and bag<sub>2</sub> fibres in the present study was found to be between 2 and 4, mean = 2.7 for bag<sub>2</sub> fibres, and between 1 and 4, mean = 2.5 for bag<sub>1</sub> fibres. This is similar to the findings of Soukup (1976). However, the diameter of intrafusal muscle fibres in rat deep masseter muscle measured in the present study was found to be smaller than that reported in some rat hindlimb muscles (Porayko and Smith, 1968; Ovalle, 1971; Soukup, 1976 and Banks *et al.*, 1977). This might be due to using different techniques for the study or else the intrafusal muscle fibres of masseter muscle are thinner than that in hindlimb muscles.

In the present sample of spindles from rat deep masseter muscle all the bag fibre types were seen to extend beyond the limits of the capsule. This is similar to what happens in other muscles of rat and other mammals. The length of bag fibres which extended beyond the capsule limits as found in this study were in a range of 50 to 1450  $\mu\text{m}$  for bag<sub>1</sub> fibres and of 50 to 1700  $\mu\text{m}$  for bag<sub>2</sub> fibres. The two ends of each intrafusal fibre did not extend equally beyond the limits of its capsule. This is the same as with other mammals. Regarding this point, three arrangements of chain-fibre insertion were found in the above sample: in the first type the fibre extended beyond both ends of the capsule; in the second type one end of the fibre extended beyond

the limits of the capsule, the other end terminating within or before the capsule end; in the third type both ends of the fibre terminated within or before the capsule ends or one within and the other before the capsule end. Similarly, rat lumbrical chain fibres usually extended beyond each end of the capsule (Porayko and Smith, 1968). The results presented for rat deep masseter show that 22% (N = 12) of chain fibres terminated beyond the limits of the capsule at both poles, 45% (N = 24) extended beyond the limits of the capsule at one pole, and the other pole terminated within or at the end of the capsule, the remaining 33% (N = 18) terminated within or at the end of the capsule in both poles, the total number of complete chain fibres examined being 54 (see Table 13). In terms of fibre poles, 56% (N = 60) terminated within or at the ends of the capsule and the remaining 44% (N = 48) extended beyond the limits of the capsule. According to Kucera (1980c) these are known as typical and intermediate chain fibres respectively. This result is similar to that reported by Walro and Kucera (1985a), who found that 60% of chain fibres terminated within the limits of the capsule when 13 poles of spindles containing 26 chain fibre poles were examined in rat soleus muscles. In the cat some chain fibres may extend beyond the limits of the capsule approximately as long as bag fibres, and were called "long chain" fibres by Barker *et al.* (1976). In the present study there were no long chain fibres. Similarly, Walro and Kucera (1985a) did not observe long chains in rat soleus spindles. In rat deep masseter muscle the bag<sub>2</sub> fibres were usually longer than bag<sub>1</sub> fibres, the mean total length was 2,807  $\mu\text{m}$ , N = 25, for bag<sub>2</sub> (including b<sub>2</sub>.) fibres; and 2,720  $\mu\text{m}$ , N = 22, for bag<sub>1</sub> fibres. This is shorter than that in soleus muscle of rat as reported by Walro and Kucera (1985a), who gave mean polar lengths of  $2,482 \pm 571 \mu\text{m}$  for bag<sub>1</sub> fibres and  $2,667 \pm 351 \mu\text{m}$  for bag<sub>2</sub> fibres measured from the centre of

the equator to the termination.

In the present study I found two spindles in which one chain fibre branched into two. Extremely short chain fibres that ended in the equatorial region were observed in some spindles. Similar findings have been described in cat (Boyd, 1962c).

Only one tandem spindle was found in the above sample. This consisted of three capsules linked by one common bag<sub>2</sub> fibre, and extended for about the entire length of the spindle-cluster. Two successive capsules shared one bag<sub>1</sub> fibre, and the third capsule possessed its own bag<sub>1</sub> fibre and shared a chain fibre with the adjacent capsule. Such complex spindles are common in amphibia, for example in frog's extensor digitorum longus IV muscle (Barker and Cope, 1962a) and in the muscles of cat neck (Richmond and Abrahams, 1975b). The term "conjunctive form" was applied to such complex forms of tandem spindles by Richmond and Abrahams (1975b). Karlson (1965) observed a tandem spindle which consisted of two capsules in rat jaw muscle linked by one or more fibres. Rat tail muscles contained some tandem spindles (Gladden, 1969; Thompson, 1970).

## 2. The sensory innervation

The availability in this study, for the first time, of good silver-impregnated material allowed a full analysis of spindle sensory innervation in rat. It is known that sensory innervation of the mammalian spindle consists of (i) primary endings which terminate as annulospirals on the densely nucleated equatorial parts of the three fibre types, and are supplied by the thickest afferent, and (ii) secondary endings which are similar and located adjacent to the primary ending in the equatorial region on one or both sides, and are supplied

by a thinner afferent than that which supplies the primary ending (Boyd, 1962c).

The diameter of the nerve fibres supplying the sensory endings obtained in the present study ranged from 1.9-6.0  $\mu\text{m}$  for the primary endings and from 1.1-4.9  $\mu\text{m}$  for the secondary endings in deep masseter, peroneus longus and lumbrical muscles (Table 17). The sensory nerve fibre diameters in normal and de-efferented rat muscle spindles stained with osmium tetroxide ranged from 1-10  $\mu\text{m}$  in lumbrical muscles (Porayko and Smith, 1968) and 2-12  $\mu\text{m}$  in intertransverse caudal muscles (Gladden, 1969). My readings are lower than those reported by the above authors. This is due to the different stains used, since the silver stains the axis cylinders of the nerve fibres only and the osmium tetroxide stains the myelin sheath only. The results are comparable if the conversion factor of 1.41 for silver-stained fibres (Stacey, 1967) is used.

In the present work the primary endings were found to be annulospirals, and occupied 70-386  $\mu\text{m}$  of the central nucleated area of the intrafusal muscle fibres. The secondary endings, up to a maximum of three, were fine sprays and some coils and spirals, and occupied 20-350  $\mu\text{m}$  of the areas adjacent to the primary endings within the periaxial space. As in other mammals not all the spindles found in rat contained secondary endings. These results are similar to the findings of Porayko and Smith (1968) and Gladden (1969) in rat lumbrical and intertransverse caudal muscles respectively. Porayko and Smith in their sample did not observe more than two secondary endings in a spindle.

For the first time in this study new data were collected about the rat spindle sensory innervation in deep masseter and some other hindlimb muscles. Some unusual features in the sensory innervation

were observed, these are: i) a large proportion of spindles with multiple primary endings, ii) sharing branching between primary and secondary endings and between the secondaries, iii) sharing branching between two bag<sub>1</sub> fibres in two different spindles.

In the spindles of the anterior cluster of deep masseter, peroneus longus, soleus and lumbrical muscles, the number of afferents which supplied each spindle varied between 1 and 6. This is not unusual since Banks *et al.* (1982) reported that up to 7 afferents supplied some spindles in cat. Moreover, Banks and Stacey (1988) found 8 afferents supplying a spindle which contained a double primary in cat popliteus muscle.

Analysis of the primary endings in the teased spindles of rat revealed that bag<sub>1</sub> and bag<sub>2</sub> fibres were often innervated separately, chain fibres usually sharing an afferent with bag<sub>2</sub> fibres. Up to 4 afferents were found terminating in the primary region of some spindles to form multiple primaries. The highest frequency of multiple primaries occurred in deep masseter muscle and the lowest were in lumbrical muscles. Such multiple primary endings in mammalian spindles have not been reported before the present study. Barker in his review (1974) mentioned that on very rare occasions two afferents were observed to enter a spindle to form "a single combined ending". Banks (1973) observed for the first time that some spindles in rabbit tenuissimus muscle contained two primary endings supplied by two independent nerve fibres. Then Banks *et al.* (1982) reported that in some cat spindles the primary endings were supplied by two afferents and therefore named them "double primaries". Later, Banks and Stacey (1988) found that 12% of spindles in extensor digitorum longus of cat possessed double primary endings.

Another unusual phenomenon in this study was that in rat deep



masseter muscle, some Ia afferents were seen to branch, each one supplying primary endings to two bag fibres, usually bag<sub>1</sub>, in separate spindles (see figures 54 & 56). Such branching in mammal primary afferents has never before been reported.

In this study, group II afferents which supply the secondary endings were often found branched to supply two secondary endings within the spindle, lying one on each side of the primary ending. Similarly, Banks (1973) found group II axons in some spindles of guinea-pig branched to supply two secondary endings, one on each side of the primary ending. Boyd (1962c) described only one group II axon in a particular spindle of cat that branched to supply two secondary endings, one on each side of the primary. On the other hand, such fibres were frequently seen branched to supply secondary endings in different spindles.

Another unusual occurrence in the sensory innervation was seen in some spindles of the four rat muscles examined. Some afferents were seen divided into two branches, one supplying primary endings, the second supplying secondary endings in the same spindle. In one spindle from peroneus longus two afferents were innervated in its sensory region; one of them supplied a primary ending, the other was divided to supply a primary ending and two secondary endings, one on each side of the primary.

Most of the studies of the sensory innervation of muscle spindles in silver- or gold-chloride-impregnated preparations have been carried out in mammalian hindlimb muscles, especially in cat. There is still not enough information about the sensory innervation of the spindles in jaw muscles, since no observations have been made using teased silver- or gold-chloride-impregnated materials which keep the afferents intact to their terminals. However, the present study has revealed that in

the rat features of the muscle spindles in the deep masseter and hindlimb muscles are similar.

Based on these constant features in rat spindle it is possible to summarise the following: an extremely high incidence of multiple primaries in deep masseter muscle and in other muscles of the hindlimb; a large proportion of afferents supplied to the primary ending; locations, branching of afferents supplying secondary endings or primary and secondary endings in the same spindle or supplying primary endings to bag<sub>1</sub> fibres in two different spindles. Comparing the features of rat spindles in these findings, with cat it is possible to suggest that differences in form and distribution are species dependent.

A complete account of motor innervation of intrafusal muscle fibres in rat deep masseter muscle spindles is beyond the scope of the present study. However it is interesting to mention the existence of  $\beta$ -innervation in deep masseter muscle. It was reported above (Chapter V) that the few oxidative extrafusal muscle fibres associated with the spindle-cluster in rat deep masseter muscle might receive a  $\beta$ -innervation.

Examination of the anterior spindle-cluster of rat deep masseter in teased silver preparation revealed some definite examples of  $\beta$ -innervation, despite the difficulty of keeping the common axon together with its intra- and extrafusal branches intact. Fortunately, in three instances, I was able to obtain the common axon with its two branches, for example see figure 67. The intrafusal branch terminated in a small plate on bag<sub>1</sub> fibres in each case. Similar plates were often seen on bag<sub>1</sub> fibres of other spindles in the cluster, for example see figure 68, but the intrafusal motor axon could not be traced to its parent. This is anatomically convincing evidence for the existence of

$\beta$ -innervation in rat deep masseter muscle. Similarly, Porayko and Smith (1968) reported six instances of the innervation of bag fibres by  $\beta$  collaterals in teased, silver preparations of rat lumbrical muscles. Gladden (1969) identified the smaller of the two fusimotor endings as corresponding with the cat  $P_1$  plates, in teased silver preparations of rat tail muscles.

The conclusion from these findings is that some cluster spindles in rat deep masseter muscle receive a dynamic  $\beta$ -innervation similar to that demonstrated in cat hindlimb spindles by Barker *et al.* (1977). Therefore, the extrafusul muscle fibres which participated in this innervation were probably of the slow oxidative type. Hence, this result confirms the suggestion made by Rowlerson *et al.* (1988) that the type I fibres which surround the anterior spindle-cluster in rat deep masseter muscle might receive slow dynamic  $\beta$ -innervation (see discussion of Chapter V). Using serial 1  $\mu\text{m}$ -thick transverse sections of rat lumbrical muscle spindles for tracing fusimotor axons, Walro and Kucera (1985b) found 7  $\beta$  axons (4 confirmed and 3 assumed to be  $\beta$ ), five of which terminated on bag<sub>1</sub> fibres and two on chain fibres.

$\beta$ -innervation has been found in a number of different muscles and species. It became obvious that there are dynamic and static  $\beta$  axons (Barker and Banks, 1986). This confirms the suggestion by Barker *et al.* (1970) that  $\beta$ -innervation is part of the motor innervation in most muscles.

## CHAPTER VII

### Muscle spindles in jaw muscles of other vertebrates

#### A. Introduction

Muscle spindles of both single and tandem types have been described in hindlimb muscles of Amphibia and were confined to Anura (Gray, 1957; Barker and Cope, 1962a; Barker, 1974). No muscle spindle has been reported from any urodele muscle (Bone *et al.*, 1976).

The frog's spindle consists of a bundle of small and large intrafusal muscle fibres, usually four or five. They have been classified into two types, a large twitch fibre and a small, non-twitch fibre (Barker, 1974; Ovalle and Smith, 1975). On the basis of fine structure observations, Page (1966) divided them into twitch and intermediate types innervated by large and small axons respectively. Nevertheless, the intrafusal muscle fibres in frog are not differentiated into bags and chains. Recently, Yoshimura, Diwan, Fujitsuka, Sokabe and Ito (1987); Diwan, Yoshimura and Ito (1987); Diwan and Ito (1989) suggested that frog intrafusal muscle fibres are of four types: large and medium nuclear bag fibres (possibly bag<sub>2</sub> and bag<sub>1</sub>) and two types of small nuclear chain fibres, one with and the other without a reticular zone. The sensory region is encapsulated by a thin capsule, its wall consist of fewer lamellae than that of a mammalian spindle capsule (Barker and Cope, 1962a).

Whereas Barker (1974) considered that muscle spindles are present in anamniote vertebrates only in anuran Amphibia, and that fish have none, Maeda *et al.* (1983) have reported that jaw-closing muscles of Japanese salmon (*Oncorhynchus masou*) contain monofibril spindles.

In this study I have examined the adductor mandibulae muscles of a frog (*Rana temporaria*), a newt (*Notophthalmus v. viridescens*), and a fish (*Salmo trutta*) using light microscopy to search for encapsulated neuromuscular spindles or tendon organs in these muscles.

## B. Results

1. Frog: muscle spindles were observed among the extrafusal muscle fibres of two adductor mandibulae muscles of frog (*Rana temporaria*) that were embedded in Araldite, serially sectioned transversely (1  $\mu\text{m}$  thick) at 50  $\mu\text{m}$  intervals, and stained with toluidine blue stain. One muscle contained 8 single spindles which were distributed along the length of the muscle from origin to insertion. Each spindle unit was composed of 1-5 small and large intrafusal muscle fibres enclosed by a thin capsule (figures 69, 70 and 71, plate 12). The spindles in jaw muscles appeared to be similar to those in the fourth extensor digitorum longus of the frog which were described by Barker and Cope (1962a). No tandem spindle was seen in the jaw muscles of the frog.

2. Newt: four adductor mandibulae muscles embedded in Araldite were serially sectioned transversely (1  $\mu\text{m}$  thick) at 50  $\mu\text{m}$  intervals and stained with toluidine blue stain. Only one muscle out of the four contained one possible intrafusal muscle fibre in a thin capsule, situated peripherally in the muscle mass (figure 74a low power and figures 72-75 high power, plate 13). The length of that intrafusal fibre was 1600  $\mu\text{m}$  in the serial transverse sections.

3. Fish: four complete adductor mandibulae muscles of fish (*Salmo trutta*) embedded in paraffin wax were serially sectioned transversely (5  $\mu\text{m}$  thick), stained with Weigert iron haematoxylin and van Gieson's stains. All sections were examined under a light microscope. I could not find any encapsulated neuromuscular spindle or tendon organs in the fish jaw muscles.

## Plate 12

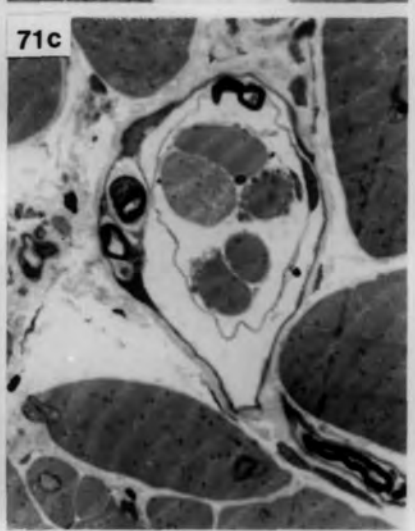
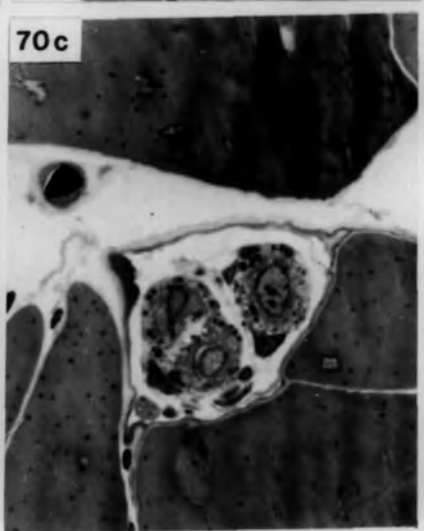
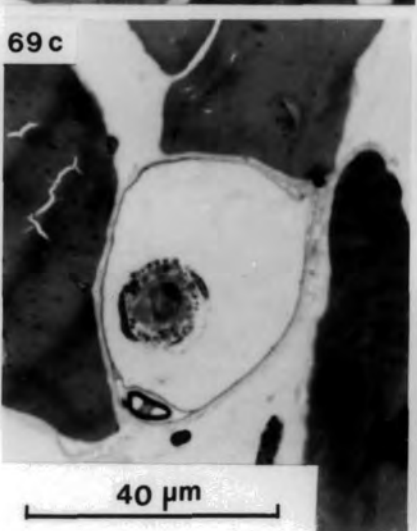
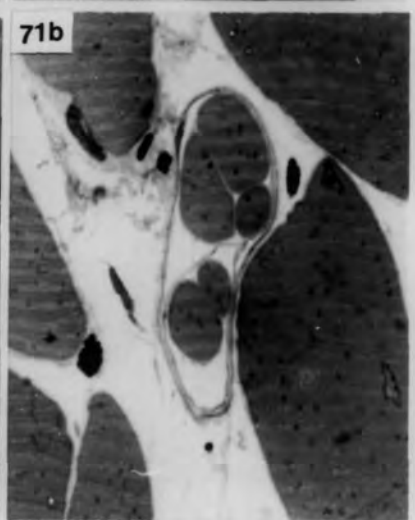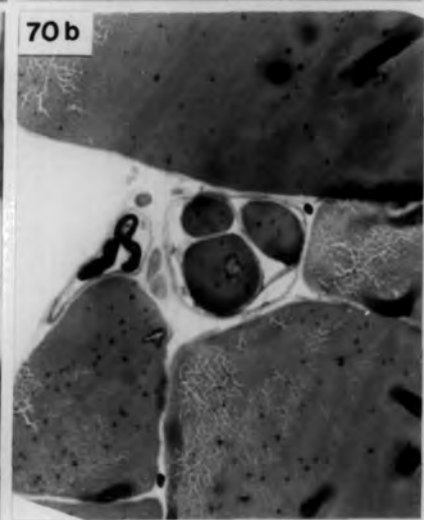
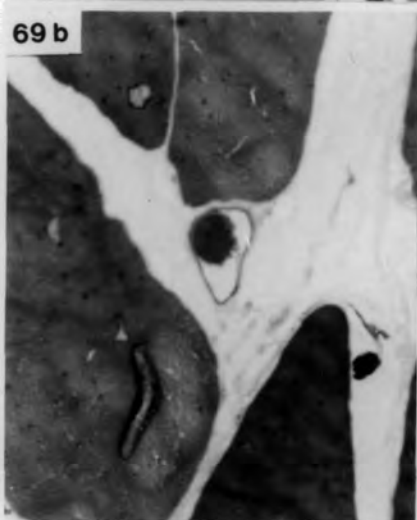
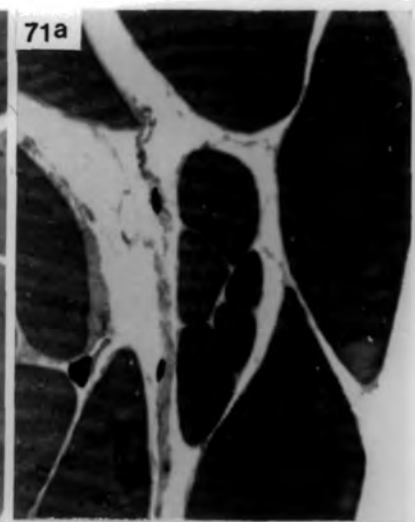
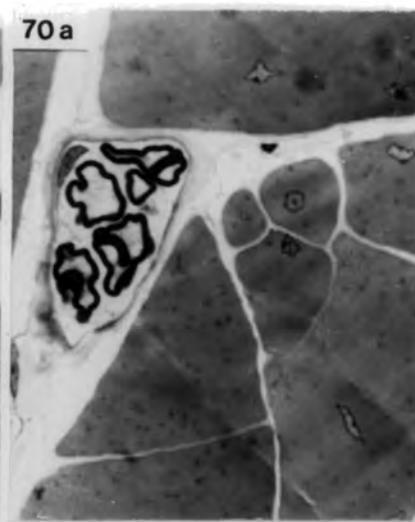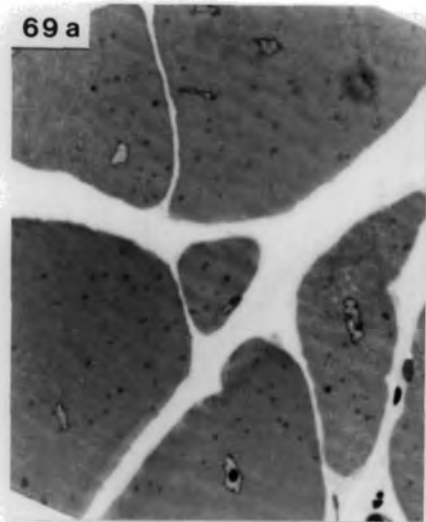
Photographs of toluidine blue-stained 1  $\mu\text{m}$ -thick transverse plastic sections of frog jaw muscle spindles cut through three different levels for each spindle: a) through region C, b) through region B, c) through region A.

Figure 69a, b & c. Shows a spindle that consisted of one intrafusal muscle fibre.

Figure 70a, b & c. Shows a spindle that consisted of three intrafusal muscle fibres; two large and one small.

Figure 71a, b & c. Shows a spindle that consisted of five intrafusal muscle fibres; two large and three small.

Scale in figure 69c refers to all figures.





### Plate 13

Figure 73a. Photograph at low power of toluidine blue-stained 1  $\mu$ m-thick transverse plastic sections of adductor mandibulae muscle of a newt. A single muscle fibre surrounded by a thin capsule (arrow) among the extrafusal muscle fibre is seen.

Figures 72-75. Photographs at higher power in semi-serial transverse sections stained with toluidine blue (1  $\mu$ m-thick) over a length of 1000  $\mu$ m showing the same intrafusal fibre that appears in figure 73a. Scale in figure 74 refers to figures 72-75.

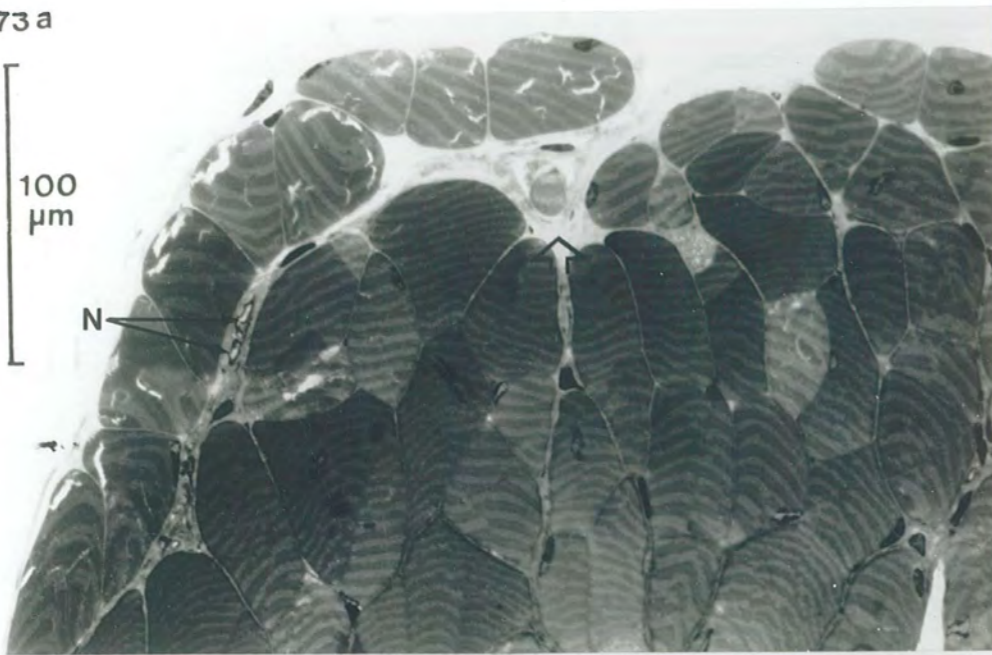
#### Abbreviation:

N : myelinated nerve fibres

73 a

100  
μm

N



72

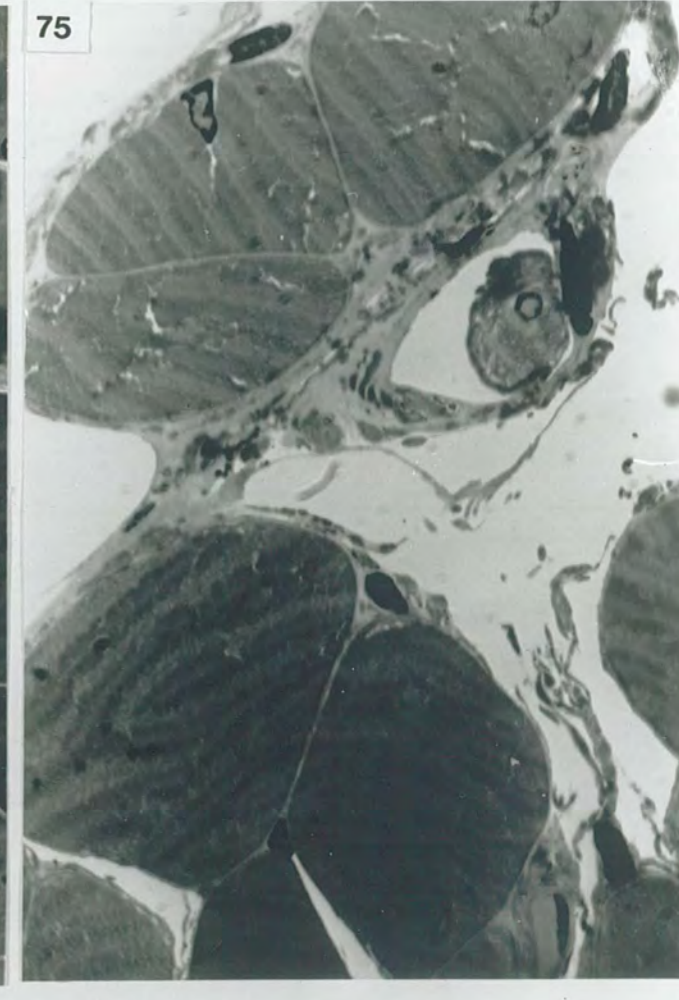
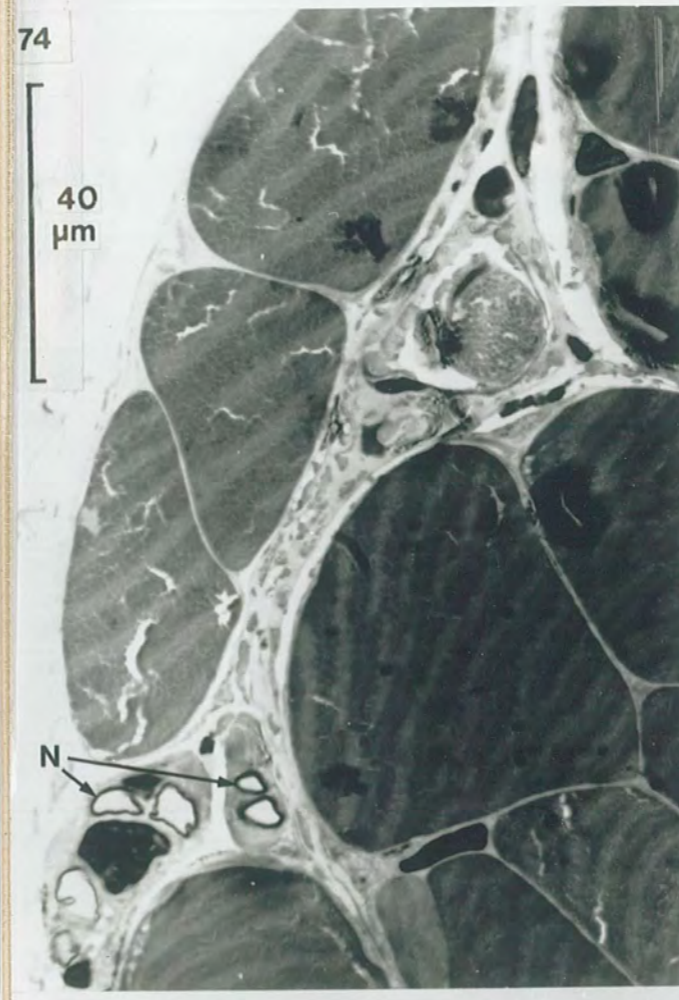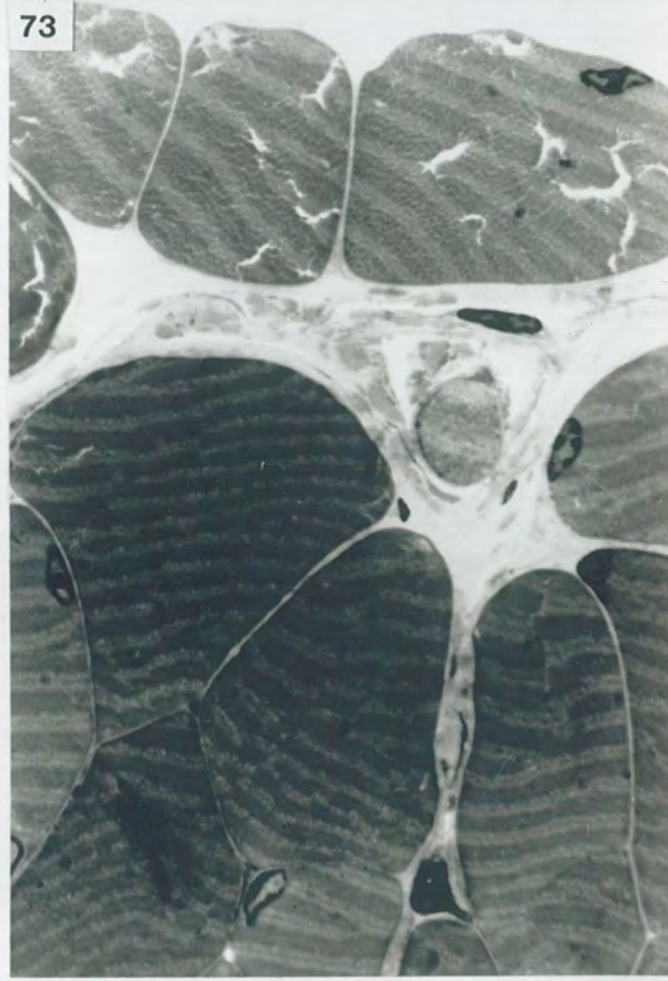
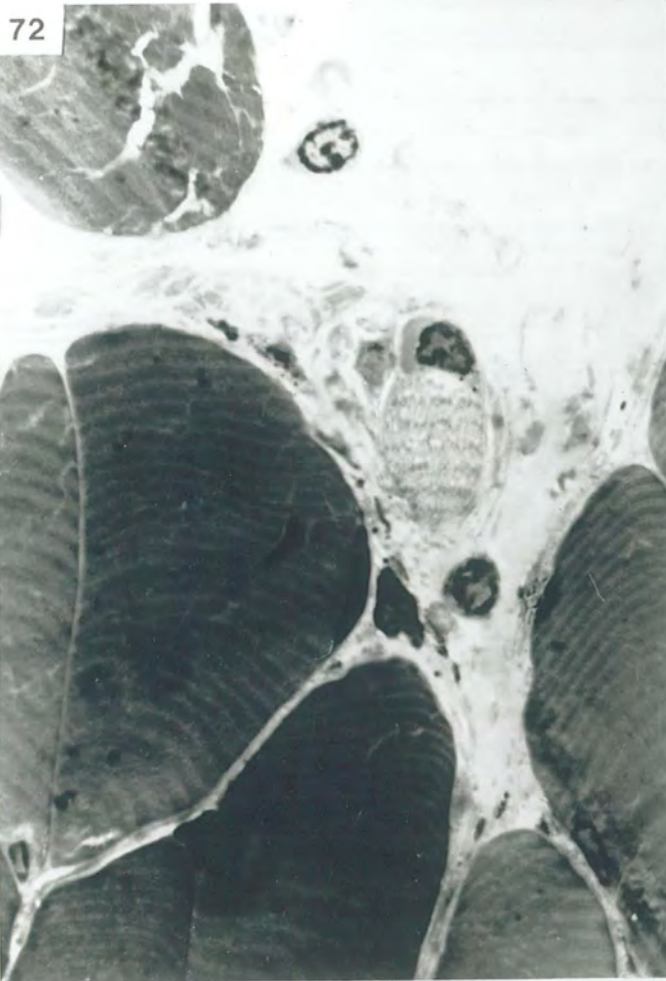
73

74

75

40  
μm

N



### C. Discussion

The surprising discovery by Maeda *et al.* (1983) of a monofibrillar spindle in jaw-closing muscles of the Japanese salmon prompted me to look for the existence of muscle spindles in the jaw muscles of frog and newt as well as fish.

The semi-serial sections (1  $\mu\text{m}$  thick) at 50  $\mu\text{m}$  intervals of adductor mandibulae muscles of frog (*Rana temporaria*) investigated in this study revealed the presence of spindles in these muscles. The number of intrafusal muscle fibres in each spindle varied between 1 and 5 and the fibres were of different diameters. For part of their length, they were surrounded by a very thin capsule, thinner than those which occur in mammal spindles. These general features of the spindle are similar to those in frog's (*Rana rugulosa* and *R. guentheri*) fourth extensor digitorum longus muscle (Barker and Cope, 1962a). All the spindles found in jaw-closing muscles of the frog in this study were distributed singly along the length of the muscle and their respective positions were in different parts of its transverse plane. They were of simple type, i.e. no spindles sharing capsules, no tandem spindles, and no spindle system or complex forms like those described in frog limb muscles were found (Gray, 1957; Barker and Cope, 1962a; and Diwan and Ito, 1989). In this study no attempt was made to study the intrafusal muscle fibres and their innervation.

The technique described above was carried out in four adductor mandibulae muscles of newt. I did not find any spindles, even with only one intrafusal muscle fibre similar to that in hindlimb muscle of lizard which was described by Proske (1969b). Proske (figure 2) showed that a transverse section of a spindle in iliofibularis muscle of lizard consists of one intrafusal fibre surrounded by an inner and an

outer capsule.

In only one muscle of the four did I find a small fibre (figures 72-75) running among the extrafusal muscle fibres over a length of 1600  $\mu\text{m}$ . It seems likely that it was an intrafusal fibre because it was surrounded by connective tissue similar to a capsule. To regard this fibre as intrafusal fibre with any certainty is difficult without the aid of electron microscopy and silver impregnation studies. Therefore, this finding cannot be taken to contradict the opinions of Barker (1974) and Bone *et al.* (1976), that muscle spindles are absent from the muscles of newt.

Light microscopy was used for the examination of serial paraffin sections containing the four adductor mandibulae muscles of trout. These sections were stained with Weigert's iron haematoxylin and van Gieson's stains, to search for the presence of muscle spindles as reported in Japanese salmon by Maeda *et al.* (1983). Although the thickness of the transverse sections was 5  $\mu\text{m}$  (in order to help to recognize the spindle) I could find no trace of a connective tissue capsule in any of the four muscles examined. Therefore, according to the above results, there is no firm evidence that jaw-closing muscles of salmon possess a muscle spindle, especially since the adductor mandibulae muscles of newt do not possess a muscle spindle.

## CHAPTER VIII

### General Conclusion

The present study has revealed that masseteric nerve supplying deep masseter muscle of the rat contained 2120 myelinated axons (one sample); the maximum diameter of the largest axon was 18.25  $\mu\text{m}$ ; the number of muscle spindles ranged between 86 and 134; they were located deeply and close to the midline, evenly distributed in the origin-insertion direction but often grouped together (clustered) in the transverse plane. Some spindles were found sharing capsules. No tendon organs were found in deep masseter muscles examined here. The total fibre count of digastric and deep masseter muscle obtained in this study was constant in young and old rats and about three times higher than Hiitemae's (1971) counts.

Using glyoxylic acid-induced fluorescence in autonomic nerves it was found that some spindle capsules in deep masseter muscle of the rat were adrenergically innervated. By electron microscopy, some unmyelinated axons were observed running between the capsule lamellae of some spindles at their equatorial region. No fluorescent nodules were observed in periaxial spaces or in association with the intrafusal muscle fibres, due either to the small size of unmyelinated axons in rat spindles or to species differences in contrast with cat, dog and human.

The glyoxylic acid revealed that some extrafusal muscle fibres of deep masseter and anterior digastric muscles were associated with adrenergic innervation: the estimated proportion was 40% and 55% respectively. These results led me to suggest that most of the tension observed by Passatore *et al.* (1981, 1982 & 1985) was due to the

contraction of these extrafusal muscle fibres.

Using histochemical and immunohistochemical techniques, rat masseter muscle appeared to be composed of type IIA fibres, but a few type I and IIC fibres were found in the deep layer of the muscle in the area that contained the spindle-cluster. Type IIC fibres are suggested here to be constant in rat masseter muscle. No type IIB fibres were found in this muscle. The same techniques were used to recognize the intrafusal muscle fibres. The three types of intrafusal ( $bag_1$ ,  $bag_2$  and chain) fibre were found in deep masseter muscle, similar to those described in rat hindlimb muscle. Some spindles possessed an additional  $bag_2$  fibre.

In addition to histo- and immunohistochemical profiles, the three types of intrafusal fibre differ morphologically in the length, diameter and equatorial nucleation. These morphological differences were present between the intrafusal fibres of deep masseter, but the fibres were shorter and thinner than the corresponding types in hindlimb muscles. In two instances a chain fibre was seen branched into two. A tandem spindle was found as well.

The silver impregnation technique used in this work revealed the features of sensory innervation in rat spindles which is characterized by a large proportion of spindles with multiple primary endings, some of the afferents also branching to supply secondary endings. Some primary afferents branched to supply two  $bag_1$  fibres in two different spindles. Some group II afferents branched to supply two secondary endings in the same spindle. Most of these phenomena are unusual or have not been reported in any mammal before this work. The fact that they occur in both masseter and hindlimb muscles of the rat indicates that they are species dependent.

The teased silver preparations of rat deep masseter muscle

revealed some bag<sub>1</sub> fibres of spindles in the anterior cluster innervated by slow dynamic  $\beta$  axons.

The present study has revealed that muscle spindles occur in jaw-closing muscles of the frog but none are found in those of newt and fish.

### References

- ADAL, M.N. (1969). The fine structure of the sensory region of cat muscle spindle. *J. Ultrastruct. Res.* **26**, 332-354.
- ANDREW, B.L. & PART, N.J. (1974). The division of control of muscle spindles between fusimotor and mixed skeletofusimotor fibres in a rat caudal muscle. *Quart. J. exp. Physiol.* **59**, 331-349.
- ANDREW, B.L., PART, N.J. & WAIT, F. (1971). Muscle spindles without  $\gamma$ -efferents. *J. Physiol. (Lond.)* **219**, 28-29P.
- ARBUTHNOTT, E.R., GLADDEN, M.H. & SUTHERLAND, F.I. (1982). Autonomic innervation of muscle spindles from the hind limb of the cat. *Suppl. Proc. Roy. Microscop. Soc.* **17**, 1.
- ARBUTHNOTT, E.R., GLADDEN, M.H. & SUTHERLAND, F.I. (1989). The selectivity of fusimotor innervation in muscle spindles of the rat studied by light microscopy. *J. Anat.* **163**, 183-190.
- BALLARD, K.J. (1978). Typical sympathetic noradrenergic ending in a muscle spindle of the cat. *J. Physiol. (Lond.)* **285**, 61-62.
- BANKER, B.Q. & GIRVIN, J.P. (1971). The ultrastructural features of the mammalian muscle spindle. *J. Neuropath. exp. Neurol.* **30**, 155-195.
- BANKS, R.W. (1971). Histochemical studies on rabbit intrafusal fibres. *J. Anat.* **108**, 613-614.
- BANKS, R.W. (1973). Morphological and histochemical studies on muscle spindles. Ph.D. Thesis: University of Sheffield.
- BANKS, R.W. (1981a). A histological study of the motor innervation of cat's muscle spindle. *J. Anat.* **133**, 571-591.
- BANKS, R.W. (1984). On the attachment of elastic fibres in cat tenuissimus muscle spindles. *J. Physiol. (Lond.)* **348**, 16P.
- BANKS, R.W. (1986). Observations on the primary sensory ending of tenuissimus muscle spindles in the cat. *Cell Tissue Res.* **246**, 309-319.
- BANKS, R.W., BARKER, D., HARKER, D.W. & STACEY, M.J. (1975). Correlation between ultrastructural and histochemistry of mammalian intrafusal muscle fibres. *J. Physiol. (Lond.)* **252**, 16-17P.
- BANKS, R.W., BARKER, D. & STACEY, M.J. (1982). Form and distribution of sensory terminals in cat hindlimb muscle spindles. *Phil. Trans. Roy. Soc.* **B299**, 329-364.
- BANKS, R.W., BARKER, D. & STACEY, M.J. (1985). Form and classification



- of motor endings in mammalian muscle spindles. Proc. Roy. Soc. Lond. B225, 195-212.
- BANKS, R.W., HARKER, D.W. & STACEY, M.J. (1977). A study of mammalian intrafusal muscle fibres using a combined histochemical and ultrastructural technique. J. Anat. 123, 783-796.
- BANKS, R.W. & JAMES, N.T. (1971). The fine structure of the guinea-pig muscle spindle. J. Anat. 110, 161-162.
- BANKS, R.W. & STACEY, M.J. (1988). Quantitative studies on mammalian muscle spindles and their sensory innervation. In Mechanoreceptors - Development, Structure and Function (eds. P. Hnik, J. Soukup, R. Vejsand & J. Zelená), p. 263-269. New York: Plenum Press.
- BARANY, M. (1967). ATPase activity of myosin correlated with speed of muscle shortening. J. Gen. Physiol. 50, 197-216.
- BARKER, D. (1948). The innervation of muscle-spindle. Quart. J. micr. Sci. 89, 143-186.
- BARKER, D. (1966). Three types of motor ending in cat spindles. J. Physiol. (Lond.) 186, 27-28.
- BARKER, D. (1967). The innervation of mammalian skeletal muscle. In Ciba Foundation Symposium on Myotatic, Kinesthetic and Vestibular Mechanisms (eds. A.V.S. De Reuck & J. Knight), p. 3-15. London: Churchill.
- BARKER, D. (1974). The morphology of muscle receptor. In Handbook of Sensory Physiology, Vol. III/2: Muscle Receptors (ed. C.C. Hunt), p. 1-190. Berlin: Springer-Verlag.
- BARKER, D. & BANKS, R.W. (1986). The muscle spindle. In Myology, Vol. 1 (eds. A.G. Engel & B.Q. Banker), p. 309-341. McGraw Hill: New York.
- BARKER, D., BANKS, R.W., HARKER, D.W., MILBURN, A. & STACEY, M.J. (1976). Studies of the histochemistry, ultrastructure, motor innervation, and regeneration of mammalian intrafusal muscle fibres. In Understanding the Stretch Reflex (ed. S. Homma), Prog. Brain Res. 44, 67-88. Amsterdam, Excerpta Medica.
- BARKER, D. & COPE, M. (1962a). Tandem muscle-spindles in the frog. J. Anat. 96, 49-57.
- BARKER, D. & COPE, M. (1962b). The innervation of individual intrafusal muscle fibres. In Symposium on Muscle Receptors (ed. D. Barker), p. 263-269. Hong Kong: Hong Kong Univ. Press.
- BARKER, D., EMONET-DÉNAND, F., HARKER, D.W., JAMI, L. & LAPORTE, Y. (1977). Types of intra- and extrafusal muscle fibre innervated by dynamic skeleto-fusimotor. J. Physiol. (Lond.) 266, 713-726.
- BARKER, D., EMONET-DÉNAND, F., LAPORTE, Y. & STACEY, M.J. (1980). Identification of the intrafusal endings of skeletofusimotor axons in the cat. Brain Res. 185, 227-237.

- BARKER, D. & HUNT, J.P. (1964). Mammalian intrafusal muscle fibres. *Nature (Lond.)* **203**, 1193.
- BARKER, D. & IP, M.C. (1963). A silver method for demonstrating the innervation of mammalian muscle in teased preparations. *J. Physiol. (Lond.)* **169**, 73-74.
- BARKER, D. & SAED, H. (1987). Adrenergic innervation of rat jaw muscles. *J. Physiol. (Lond.)* **391**, 114P.
- BARKER, D. & SAITO, M. (1981). Autonomic innervation of receptors and muscle fibres in cat skeletal muscle. *Proc. Roy. Soc. Lond.* **B212**, 317-332.
- BARKER, D. & STACEY, M.J. (1970). Rabbit intrafusal muscle fibres. *J. Physiol. (Lond.)* **210**, 70-72P.
- BARKER, D., STACEY, M.J. & ADAL, M.N. (1970). Fusimotor innervation in the cat. *Phil. Trans. Roy. Soc.* **B258**, 315-346.
- BILLETER, R., WEBER, H., LUTZ, H., HOWALD, H., EPPENBERGER, H. & JENNY, E. (1980). Myosin types in human skeletal muscle fibres. *Histochemistry* **65**, 249-259.
- BLOOM, F.E. & BARNETT, R.J. (1966). Fine structural localization of noradrenaline in vesicles of autonomic nerve endings. *Nature (Lond.)* **210**, 599-601.
- BONE, Q. (1978). Locomotor muscle. *Fish Physiology*, Vol. **VII**, 361-424.
- BONE, Q., RIDGE, R.M.A.P. & RYAN, K.P. (1976). Stretch receptors in urodele limb muscles. *Cell Tissue Res.* **165**, 249-266.
- BOSLEY, M. & ROWLERSON, A. (1980). A new myosin associated with the fast fibre type in the cat jaw-closer muscles? *J. Physiol. (Lond.)* **306**, 18P.
- BOTTERMAN, B.R., BINDER, M.D. & STUART, D.G. (1978). Functional anatomy of the association between motor units and muscle receptors. *Am. Zool.* **18**, 135-152.
- BOWMAN, W.C. & ZAIMIS, E. (1958). The effects of adrenaline, noradrenaline and isoprenaline on skeletal muscle contractions in the cat. *J. Physiol. (Lond.)* **144**, 92-107.
- BOYD, I.A. (1962c). The structure and innervation of the nuclear bag muscle fibre system and the nuclear chain muscle fibre system in mammalian muscle spindles. *Phil. Trans. Roy. Soc.* **B245**, 81-136.
- BOYD, I.A. (1985). Autonomic control of intrafusal muscle fibres. In The Muscle Spindle (eds. I.A. Boyd & M.H. Gladden), p. 145-146. London: Macmillan.
- BOYD, I.A. & DAVEY, M.R. (1968). Composition of Peripheral Nerves. Edinburgh and London: Livingstone.
- BRIDGMAN, C.F., SHUMPERT, E.E. & ELDRED, E. (1969). Insertions of intrafusal fibres in muscle spindles of the cat and other mammals.

Anat. Rec. 164, 391-402.

BROOKE, M.H. & KAISER, K.K. (1970). Muscle fibre types: how many and what kind? Arch. Neurol. 23, 369-379.

CARPENÉ, E., ROWLERSON, A., VEGGETTI, A. & MASCARELLO, F. (1982). Preparation of type-specific antimyosin antibodies and determination of their specificity by biochemical and immunohistochemical methods. Italian J. Biochem. 31, 329-341.

COOPER, S. & DANIEL, P.M. (1956). Human muscle spindles. J. Physiol. (Lond.) 133, 1-3.

COOPER, S. & DANIEL, P.M. (1967). Elastic tissue in muscle spindles of man and rat. J. Physiol. (Lond.) 192, 10-11P.

COOPER, S. & GLADDEN, M. (1974). Elastic fibres and reticulin of mammalian muscle spindles and their functional significance. Quart. J. exp. Physiol. 59, 367-385.

COWEN, T., HAVEN, A.J. & BURNSTOCK, G. (1985). Pontamine sky blue: A counterstain for background autofluorescence in fluorescence and immunofluorescence histochemistry. Histochemistry 82, 205-208.

DENNY-BROWN, D.E. (1929). The histological features of striped muscle in relation to its functional activity. Proc. R. Soc. 104, 371-411.

DIWAN, F.H. & ITO, F. (1989). Intrafusal muscle fibre types in frog spindles. J. Anat. 163, 191-200.

DIWAN, F.H. & MILBURN, A. (1986). The effects of temporary ischaemia on rat muscle spindles. J. Embryol. exp. Morph. 92, 223-254.

DIWAN, F.H., YOSHIMURA, A. & ITO, F. (1987). Differentiation of intrafusal muscle fibre types in frog muscle spindles. Dobutsu seiri 4, 129.

DREWS, G.A. & ENGEL, W.K. (1966). Reversal of the ATPase reaction in muscle fibres by edta. Nature (Lond.) 212, 1551-1553.

DRURY, R.A.B. and WALLINGTON, E.A. (1980). Carleton's Histological Technique, 5th ed. Oxford University Press.

DUBNER, R., SESSLE, B.J. & STOREY, A.T. (1978). Peripheral components of motor control. In The Neural Basis of Oral and Facial Function (eds. R. Dubner, B.J. Sessle & A.T. Storey), p. 211-245. New York and London: Plenum Press.

DUBOWITZ, V. & PEARSE, A.G.E. (1960a). Reciprocal relationship of phosphorylase and oxidative enzymes in skeletal muscle. Nature (Lond.) 185, 701.

DUBOWITZ, V. & PEARSE, A.G.E. (1960c). A comparative histochemical study of oxidative enzyme and phosphorylase activity in skeletal muscle. Histochemie 2, 105-117.

EDGERTON, V.R. & SIMPSON, D.R. (1969). The intermediate muscle fibre

- of rats and guinea pigs. *J. Histochem. Cytochem.* **17**, 828-838.
- ELDRED, E., SCHNITZLEIN, H.N. & BUCHWALD, J. (1960). Response of muscle spindles to stimulation of the sympathetic trunk. *Expl. Neurol.* **2**, 13-25.
- ENGEL, W.K. (1962). The essentiality of histo- and cytochemical studies of skeletal muscle in the investigation of neuromuscular disease. *Neurol.* **12**, 778-94.
- ERIKSSON, P.O. & THORNELL, L.E. (1983). Histochemical and morphological muscle-fibre characteristics of the human masseter, the medial pterygoid and the temporal muscles. *Archs. oral Biol.* **28**, 781-795.
- ERIKSSON, P.O. & THORNELL, L.E. (1985). Heterogeneous intrafusal fibre composition of the human masseter muscle: morphological and enzyme-histochemical characteristics. In The Muscle Spindle (ed. I.A. Boyd & M.H. Gladden), p. 95-100. London: Macmillan.
- FALCK, B., HILLARP, M.A., THIEME, C.T. & TORP, A. (1962). Fluorescence of catecholamines and related compounds condensed with formaldehyde. *J. Histochem. Cytochem.* **10**, 348-354.
- FICK, R. (1911). *Handbuch der Anatomie und Mechanik der Gelenke: II. Allegemeine Gelenk-und-Muskel Mechanik. III. Spezielle Gelenk-und-Muskel Mechanik.*, 1910, 1911, Jena.
- GAUTHIER, G.F. & LOWEY, S. (1979). Distribution of myosin isoenzymes among skeletal muscle fibre types. *J. Cell Biol.* **81**, 10-25.
- GAUTHIER, G.F. & PADYKULA, H.A. (1966). Cytological studies of fiber types in skeletal muscle. *J. Cell Biol.* **28**, 333-354.
- GLADDEN, M.H. (1969). Muscle spindle innervation in the inter-transverse caudal muscles of the rat. *Experientia (Basel)* **25**, 604-606.
- GLADDEN, M.H. (1976). Structural features relative to the function of intrafusal muscle fibres in the cat. In Understanding the Stretch Reflex (ed. S. Homma), *Prog. Brain Res.* **44**, p. 51-59. Amsterdam, Excerpta Medica.
- GONYEA, W.J. & ERICSON, G.C. (1977). Morphological and histochemical organization of the flexor carpi radialis muscle in the cat. *Am. J. Anat.* **148**, 329-344.
- GRASSI, C. & PASSATORE, M. (1990). Sympathetic nerve stimulation at physiological frequencies can modify the contraction of fatigued and non-fatigued digastric muscle in the rabbit. *J. Physiol.* (Lond.). In press: meeting 3-4 Nov. 1989.
- GRAY, E.G. (1957). The spindle and extrafusal innervation of a frog muscle. *Proc. Roy. Soc.* **B146**, 416-430.
- GREENE, E.C. (1955). The Anatomy of the Rat. New York: Hafner Publishing Co.
- GUTH, L. & SAMAHA, F.J. (1969). Qualitative differences between

- actomyosin ATPase of slow and fast mammalian muscle. *Exptl. Neurol.* **25**, 138-152.
- GUTH, L., SAMAHA, F.J. & ALBERS, R.W. (1970). The neural regulation of some phenotypic differences between the fiber types of mammalian skeletal muscle. *Exptl. Neurol.* **26**, 126-135.
- HEBEL, R. & STROMBERG, M.W. (1976). Anatomy of the laboratory rat. Baltimore: Williams & Wilkins.
- HENNIG, G. (1969). Die Nervendigungen der Rattenmuskelspindel im elektronen und phasekontrastmikroskopischen Bild. *Z. Zellforsch.* **96**, 275-294.
- HIIEMAE, K. (1971). The structure and function of the jaw muscles in the rat (*Rattus norvegicus* L.). II. Their fibre type and composition. *Zool. J. Linn. Soc.* **50**, 101-109.
- HIIEMAE, K. (1971). The structure and function of the jaw muscles in the rat (*Rattus norvegicus* L.). III. The mechanics of the muscles. *Zool. J. Linn. Soc.* **50**, 111-132.
- HIIEMAE, K. & HOUSTON, W.J.B. (1971). The structure and function of the jaw muscles in the rat (*Rattus norvegicus* L.). I. Their anatomy and internal architecture. *Zool. J. Linn. Soc.* **50**, 75-99.
- HINES, M. & TOWER, S.S. (1928). Studies on the innervation of skeletal muscle. II. Of muscle spindles in certain muscles of the kitten. *Bull. Johns Hopkins Hosp.* **42**, 264-307.
- HINSEY, J.C. (1927). Some observations on the innervation of skeletal muscle of the cat. *J. comp. Neurol.* **44**, 87-195.
- HIRAIWA, T. (1978). Histochemical properties of masticatory muscles of growing rat and of matured mammals. *Comp. Biochem. Physiol.* **59A**, 231-238.
- HOWALD, H. (1982). Training induced morphological and functional changes in skeletal muscle. *Int. J. Sports Med.* **3**, 1-12.
- HUNT, C.C. (1960). The effect of sympathetic stimulation on mammalian muscle spindles. *J. Physiol. (Lond.)* **151**, 332-341.
- JAMES, N.T. (1971c). The histochemical demonstration of three types of intrafusal fibre in rat muscle spindles. *Histochem. J.* **3**, 457-462.
- JAMI, L., LAN-COUTON, D., MALMGREN, K. & PETIT, J. (1978). 'Fast' and 'slow' skeleto-fusimotor innervation in cat tenuissimus spindles; a study with the glycogen depletion method. *Acta Physiol. Scand.* **103**, 284-298.
- JAMI, L., LAN-COUTON, D., MALMGREN, K. & PETIT, J. (1979). Histophysiological observations on fast skeleto-fusimotor axons. *Brain Res.* **164**, 53-59.
- JANSSON, E., SJODIN, B. & TESCH, P. (1978). Changes in muscle fibre type distribution in man after physical training. *Acta Physiol. Scand.* **104**, 235-237.

- JINNAI, D. (1960). Functional differentiation of skeletal muscles. *Acta Med. Okayama* **14**, 159.
- KARLSEN, K. (1965). The location of motor end plates and the distribution and histological structure of muscle spindles in jaw muscle of the rat. *Acta odont. Scand.* **23**, 521-547.
- KARLSEN, K. (1969). Fibre calibre spectra of nerves to the masticatory muscles in the cat. *Acta odont. Scand.* **27**, 263-270.
- KARNOVSKY, M.J. (1965). A formaldehyde-glutaraldehyde fixative of high osmolality for use in electron microscopy. *J. Cell Biol.* **27**, 137A.
- KENNEDY, W.R., QUICK, D.C. & REESE, T.R. (1979). Freeze-fracture of muscle spindles. *Abs. Soc. Neurosci.* **5**, 304.
- KENNEDY, W.R. & YOON, K.S. (1979). Permeability of muscle spindle capillaries and capsule. *Muscle Nerve* **2**, 101.
- KHAN, M.A. & SOUKUP, T. (1979). A histoenzymatic study of rat intrafusal muscle fibres. *Histochemistry* **62**, 179-189.
- KHAN, M.A. & SOUKUP, T. (1988). Histochemical heterogeneity of intrafusal muscle fibres in slow and fast skeletal muscles of the rat. *Histochem. J.* **20**, 52-60.
- KIRKEBY, S., MOE, D. & VILMANN, H. (1988). Esterase profile of human masseter muscle. *J. Anat.* **157**, 79-87.
- KÖNIG, R. (1979). Consecutive demonstration of catecholamines and dopamine- $\beta$ -hydroxylase within the same specimen. *Histochemistry* **61**, 301-305.
- KUCERA, J. (1977). Histochemistry of intrafusal muscle fibers outside the spindle capsule. *Am. J. Anat.* **148**, 427-432.
- KUCERA, J. (1980c). Histochemical study of long nuclear chain fibers in the cat muscle spindle. *Anat. Rec.* **198**, 567-580.
- KUCERA, J. (1981). Histochemical profiles of cat intrafusal muscle fibers and their motor innervation. *Histochemistry* **73**, 397-418.
- KUCERA, J., DOROVINI-ZIS, K. & ENGEL, W.K. (1978). Histochemistry of rat intrafusal muscle fibers and their motor innervation. *J. Histochem. Cytochem.* **26**, 973-988.
- KUCERA, J. & WALRO, J.M. (1987a). Postnatal maturation of spindles in deafferented rat soleus muscles. *Anat. Embryol.* **176**, 449-461.
- KUCERA, J. & WALRO, J.M. (1987b). Heterogeneity of spindle units in the cat tenuissimus muscle. *Am. J. Anat.* **178**, 269-278.
- KUCERA, J., WALRO, J.M. & REICHLER, J. (1988a). Motor and sensory innervation of muscle spindles in the neonatal rat. *Anat. Embryol.* **177**, 427-436.

- KUGELBERG, E. (1976). Adaptive transformation of rat soleus motor units during growth. *J. Neurol. Sci.* **27**, 269-289.
- LANDON, D.N. (1966a). Electron microscopy of muscle spindles. In Control and Innervation of Skeletal Muscle (ed. B.L. Andrew), p. 96-111. Edinburgh-London: Livingstone.
- LANDON, D.N. (1966b). The fine structure of the annulospiral sensory nerve ending in the muscle spindles of the Rat. *J. Physiol. (Lond.)* **185**, 6-7.
- LENNARTSSON, B. (1979a). Occurrence of a muscle spindle in the anterior digastric muscle of a monkey (*Macaca fascicularis*). *Archs. oral Biol.* **24**, 635-637.
- LENNARTSSON, B. (1979b). Muscle spindles in the human anterior digastric. *Acta odonto. Scand.* **37**, 329-333.
- LENNARTSSON, B. (1980a). The occurrence of muscle spindles in the masticatory muscles: A methodological study of different staining techniques. *J. Anat.* **130**, 127-130.
- LENNARTSSON, B. (1980b). Number and distribution of muscle spindles in the masticatory muscles of the rat. *J. Anat.* **130**, 279-288.
- LOW, F.N. (1976). The perineurium and connective tissue of peripheral nerve. In The Peripheral Nerve (ed. D.N. Landon), p. 159-187. London: Chapman & Hall.
- LUND, J.P. & MATTHEWS, B. (1987). Tension produced in jaw muscles of the rabbit by sympathetic stimulation. *J. Physiol. (Lond.)* **386**, 86P.
- LUND, J.P., RICHMOND, F.J.R., TOULOU MIS, C., PATRY, Y. & LAMARRE, Y. (1978). The distribution of Golgi tendon organs and muscle spindles in masseter and temporalis muscles of the cat. *Neuroscience* **3**, 259-270.
- MABUCHI, K. PINTER, K., MABUCHI, Y., SRETER, F. & GERGELY, J. (1984). Characterization of rabbit masseter muscle fibers. *Muscle & Nerve* **7**, 431-438.
- MAEDA, N., MIYOSHI, S. & TOH, H. (1983). First observation of a muscle spindle in fish. *Nature (Lond.)* **302**, 61-62.
- MAIER, A. (1979). Occurrence and distribution of muscle spindles in masticatory and suprahyoid muscles of the rat. *Am. J. Anat.* **155**, 483-506.
- MASCARELLO, F., CARPENÉ, E., VEGGETTI, A., ROWLERSON, A. & JENNY, E. (1982). The tensor tympani muscle of cat and dog contains IIM and slow-tonic fibres: an unusual combination of fibre types. *J. Mus. Res. Cell Motil.* **3**, 363-374.
- MASCARELLO, F. & ROWLERSON, A. (1986). Slow fibres and spindles in the jaw-closer muscles of the cat and rabbit. *J. Physiol. (Lond.)* **372**, 27P.
- MASCARELLO, F., SCAPOLO, P.A., VEGGETTI, A. & ROWLERSON, A. (1986).

Functional adaptation of the fibre type composition of skeletal muscle in mammals. *Basic & Applied Histochemistry* **30**, 279-283.

- MAXWELL, L.C., CARLSON, D.S., McNAMARA, J.A. & FAULKNER, J.A. (1979). Histochemical characteristics of the masseter and temporalis muscles of the Rhesus monkey (*Macaca mulatta*). *Anat. Rec.* **193**, 389-402.
- MAXWELL, A., WARD, H.A. & NAIRN, R.C. (1966). Freezing in an isopentane-liquid nitrogen mixture and storage in 2-octanol: technical improvements for immunofluorescence. *Stain Technol.* **41**, 305-307.
- MAYR, R. (1969). Untersuchungen an isolierten Muskelspindeln der Ratte nach cholinesterasedartstellung und Sudanschwarz-Färbung. *Z. Zellforsch.* **93**, 591-606.
- MERRILLEES, N.C.R. (1960). The fine structure of muscle spindles in the lumbrical muscles of the rat. *J. Biophys. biochem. Cytol.* **7**, 725-742.
- MILBURN, A. (1973a). The early development of muscle spindles in the rat. *J. Cell Sci.* **12**, 175-195.
- MILBURN, A. (1973b). The development of the muscle spindles in the rat. Ph.D. Thesis, University of Durham.
- MUHL, Z.F. & KOTOV, O. (1988). Muscle spindles in the digastric muscle of the rabbit. *J. Dent. Res.* **67**, 1243-1245.
- NACHMIAS, V.T. & PADYKULA, H.A. (1958). A histochemical study of normal and denervated red and white muscles of the rat. *J. Biophysic. Biochem. Cytol.* **4**, 47-54.
- NISHIYAMA, A. (1965). Histochemical studies on the red, white and intermediate muscle fibers of some skeletal muscles. I. Succinic dehydrogenase activity and physiological function of intercostal muscle fibers. *Acta Med. Okayama* **19**, 177.
- OGATA, T. (1958a). A histochemical study of the red and white muscle fibers. *Acta Med. Okayama* **12**, 216-227.
- OGATA, T. & MORI, M. (1962). Histochemical demonstration of three types of intrafusal fibers of muscle spindles, a study of oxidative enzymes. *Acta Med. Okayama* **16**, 347-350.
- OGATA, T. & MORI, M. (1964). Histochemical study of oxidative enzymes in vertebrate muscles. *J. Histochem. Cytochem.* **12**, 171-182.
- OGALLE, W.K. (1971). Fine structure of rat intrafusal muscle fibres. The polar region. *J. Cell Biol.* **51**, 83-103.
- OGALLE, W.K. (1972a). Fine structure of rat intrafusal muscle fibres. The equatorial region. *J. Cell Biol.* **52**, 382-396.
- OGALLE, W.K. (1972b). Motor nerve terminals on rat intrafusal muscle fibres; a correlated light and electron microscopic study. *J. Anat.* **111**, 239-252.



- OVALLE, W.K. & DOW, P.R. (1985). Morphological aspects of the muscle spindle capsule and its functional significance. In The Muscle Spindle (ed. I.A. Boyd & M.H. Gladden), p. 23-28. London: Macmillan.
- OVALLE, W.K. & SMITH, R.S. (1972). Histochemical identification of three types of intrafusal muscle fibres in the cat and monkey based on the myosin ATPase reaction. *Canad. J. Physiol. Pharmacol.* **50**, 195-202.
- OVALLE, W.K. & SMITH, R.S. (1975). Types of intrafusal muscle fibre in the amphibia. *J. Anat.* **119**, 189-191.
- PADYKULA, H.A. (1952). The localization of succinic dehydrogenase in tissue sections of the rat. *Am. J. Anat.* **91**, 107-145.
- PAGE, S.G. (1966). Intrafusal muscle fibres in the frog. *J. Microscopie* **5**, 101-104.
- PASSATORE, M. & FILIPPI, G.M. (1981). On whether there is a direct sympathetic influence on jaw muscle spindles. *Brain Res.* **219**, 162-165.
- PASSATORE, M. & FILIPPI, G.M. (1982). A dual effect of sympathetic nerve stimulation on jaw muscle spindles. *J. Auton. Nerv. Syst.* **6**, 347-361.
- PASSATORE, M., FILIPPI, G.M. & GRASSI, C. (1985). Cervical sympathetic nerve stimulation can induce an intrafusal muscle fibre contraction in the rabbit. In The Muscle Spindle (ed. I.A. Boyd & M.H. Gladden), p. 221-226. London: Macmillan.
- PASSATORE, M., GRASSI, C. & FILIPPI, G.M. (1985). Sympathetically-induced development of tension in jaw muscles: the possible contraction of intrafusal muscle fibres. *Pflügers Arch.* **405**, 297-304.
- PEARSE, A.G.E. (1972). Histochemistry, Theoretical and Applied 3rd ed. Edinburgh and London: Churchill Livingstone.
- PETER, J.B., BARNARD, R.J., EDGERTON, V.R., GILLESPIE, C.A. & STEMPEL, K.E. (1972). Metabolic profiles of three fiber types of skeletal muscle in guinea pigs and rabbits. *Biochemistry* **11**, 2627-2633.
- PORAYKO, O. & SMITH, R.S. (1968). Morphology of muscle spindles in the rat. *Experientia (Basel)* **24**, 588-589.
- PROSKE, U. (1969b). The innervation of muscle spindles in the lizard *Tiliqua nigrolutea*. *J. Anat.* **105**, 217-230.
- PULLEN, A.H. (1977b). The distribution and relative sizes of fibre types in the extensor digitorum longus and soleus muscles of the adult rat. *J. Anat.* **123**, 467-486.
- RAKHAWY, M.T., SHEHATA, S.H. & BADAWEY, Z.H. (1971). The proprioceptive innervation of the lateral pterygoid muscle in man and some other mammals. *Acta anat. (Basel)* **79**, 581-598.
- REICHMANN, H. & PETTE, D. (1982). A comparative microphotometric study

of succinate dehydrogenase activity levels in type I, IIA and IIB fibres of mammalian and human muscles. *Histochemistry* **74**, 27-41.

- REYNOLDS, E.S. (1963). The use of lead citrate at high pH as an electron-opaque stain in electron microscopy. *J. Cell Biol.* **17**, 208-212.
- RICHMOND, F.J.R. & ABRAHAMS, V.C. (1975b). Morphology and distribution of muscle spindles in dorsal muscles of the cat neck. *J. Neurophysiology* **38**, 1322-1339.
- RINGQVIST, M. (1971). Histochemical fiber types and fiber sizes in Human masticatory muscles. *Scand. J. dent. Res.* **79**, 366-368.
- RINGQVIST, M. (1973). Histochemical enzyme profiles of fibres in human masseter muscles with special regard to fibres with intermediate myofibrillar ATPase reaction. *J. neurol. Sci.* **18**, 133-141.
- RINGQVIST, M. (1974). Fiber types in Human masticatory muscle. *Scand. J. dent. Res.* **82**, 337-355.
- ROKX, J.T.M., VAN WILLIGEN, J.D. & JANSEN, H.W.B. (1984). Muscle fibre types and muscle spindles in the jaw musculature of the rat. *Archs. oral Biol.* **29**, 25-31.
- ROMANUL, F.C.A. (1964). Enzymes in muscle: I. Histochemical studies of enzymes in individual muscle fibres. *Arch. Neurol.* **11**, 355-368.
- ROWE, R.W.D. & GOLDSPINK, G. (1969). Muscle fibre growth in five different muscles in both sexes of mice. *J. Anat.* **104**, 519-530.
- ROWLERSON, A., GORZA, L. & SCHIAFFINO, S. (1985). Immunohistochemical identification of spindle fibre types in mammalian muscle using type-specific antibodies to isoforms of myosin. In *The Muscle Spindle* (eds. I.A. Boyd & M.H. Gladden), p. 29-34. London: Macmillan.
- ROWLERSON, A., MASCARELLO, F., BARKER, D. & SAED, H. (1988). Muscle-spindle distribution in relation to the fibre-type composition of masseter in mammals. *J. Anat.* **161**, 37-60.
- ROWLERSON, A., MASCARELLO, F., VEGETTI, A. & CARPENÉ, E. (1983). The fibre-type composition of the first branchial arch muscles in carnivora and primates. *J. Mus. Res. Cell Motil.* **4**, 443-472.
- ROWLERSON, A., POPE, B., MURRAY, J., WHALEN, R.G. & WEEDS, A.G. (1981). A novel myosin present in cat jaw-closing muscles. *J. Mus. Res. Cell Myotil.* **2**, 415-438.
- SAMAHA, F.J., GUTH, L. & ALBERS, R.W. (1970). Phenotypic differences between the actomyosin ATPase of the three fiber types of mammalian skeletal muscle. *Exptl. Neurol.* **26**, 120-125.
- SANTINI, M. & IBATA, Y. (1971). The fine structure of thin unmyelinated axons within muscle spindles. *Brain Res.* **33**, 289-302.
- SCHIAFFINO, S. (1974). Histochemical enzyme profile of the masseter muscle in different mammalian species. *Anat. Rec.* **180**, 53-61.

- SCHIAFFINO, S., HANZLÍKOVÁ, V. & PIEROBON, S. (1970). Relations between structure and function in rat skeletal muscle fibres. *J. Cell Biol.* **47**, 107-119.
- SHANTHA, T.R.GOLARZ, M.N. & BOURNE, G.H. (1968). Histological and histochemical observations on the capsule of the muscle spindle in normal and denervated muscle. *Acta anat. (Basel)* **69**, 632-646.
- SHEHATA, S.H. (1971). The pattern of innervation of the digastric muscle of the albino rat. *Acta anat.* **78**, 117-126.
- SNOW, D., BILLETTER, R. MASCARELLO, F., CARPENE, E., ROWLERSON, A. & JENNY, E. (1982). No classical type IIB fibres in dog skeletal muscle. *Histochemistry* **75**, 53-65.
- SOUKUP, T. (1976). Intrafusal fibre types in rat limb muscle spindles. Morphological and histochemical characteristics. *Histochemistry* **47**, 43-57.
- STACEY, M.J. (1967). The innervation of mammalian skeletal muscle by medium and small diameter afferent nerve fibres. Ph.D. Thesis: University of Durham.
- STACEY, M.J. (1969). Free endings in skeletal muscle of the cat. *J. Anat.* **105**, 231-254.
- STEIN, J.M. & PADYKULA, H.A. (1962). Histochemical classification of individual skeletal muscle fibers of the rat. *Am. J. Anat.* **110**, 103-115.
- SUZUKI, A. (1977). A comparative histochemical study of the masseter muscle of the cattle, sheep, swine, dog, guinea pig and rat. *Histochemistry* **51**, 121-131.
- SWASH, M. & FOX, K. (1985). Adrenergic innervation of baboon and human muscle spindles. In *The Muscle Spindle* (eds. I.A. Boyd & M.H. Gladden), p. 121-126. London: Macmillan.
- TAYLOR, A., CODY, F.W.J. & BOSLEY, M.A. (1973). Histochemical and mechanical properties of the jaw muscles of the cat. *Expl. Neurol.* **38**, 99-109.
- THOMPSON, J. (1970). Parallel spindle systems in the small muscles of the Rat tail. *J. Physiol. (Lond.)* **211**, 781-799.
- TRANZER, J.P. & THOENEN, H. (1967). Electronmicroscopic localization of 5-hydroxydopamine (3,4,5-trihydroxyphenyl-ethylamine) a new 'false' sympathetic transmitter. *Experientia (Basel)* **23**, 743-745.
- TURNBULL, W.D. (1970). Mammalian masticatory apparatus. *Fieldiana: Geology* **18**, 149-356.
- WALRO, J.M. & KUCERA, J. (1985a). Motor innervation of intrafusal fibers in rat muscle spindles: incomplete separation of dynamic and static systems. *Am. J. Anat.* **173**, 55-68.
- WALRO, J.M. & KUCERA, J. (1985b). Rat muscle spindles deficient in elements of the static system. *Neuroscience Letters* **59**, 303-307.

- WALRO, J.M. & KUCERA, J. (1987). Sharing of sensory terminals between the dynamic bag<sub>1</sub> and static bag<sub>2</sub> fibers in the rat muscle spindle. *Brain Res.* **425**, 311-318.
- WEIJS, W.A. (1973). Morphology of the muscles of mastication in the albino rat, *Rattus norvegicus* (Berkenhout, 1769). *Acta Morphol. neerl-Scand.* **11**, 321-340.
- WEISMANN, A. (1861). Über das Wachsen der quergestreiften Muskel nach Beobachtungen am Frosh. *Z. Rat. Med.* **10**, 263-284.
- YELLIN, H. (1969a). A histochemical study of muscle spindles and their relationship to extrafusil fiber types in the rat. *Am. J. Anat.* **125**, 31-46.
- YELLIN, H. (1969b). Unique intrafusil and extraocular muscle fibers exhibiting dual actomyosin ATPase activity. *Expl. Neurol.* **25**, 153-163.
- YELLIN, H. (1974). Regional differences in the contractile apparatus of intrafusil muscle fibers. *Am. J. Anat.* **139**, 147-152.
- YELLIN, H. & GUTH, L. (1970). The histochemical classification of muscle fibers. *Exptl. Neurol.* **26**, 424-432.
- YOSHIMURA, A., DIWAN, F.H., FUJITSUKA, N., SOKABE, M. & ITO, F. (1987). Classification of the intrafusil muscle fibres in the frog muscle spindle. *J. Physiological Soc. Japan* **49**, 477.
- YOUNG, J.Z. (1981). The Life of Vertebrates, 3rd ed., p. 246. Oxford: Univ. Oxford Press.